A 48-year-old man comes to the hospital due to 10 days of persistent fever, chills, fatigue, and dyspnea. He had a splenectomy at age 28 after a motor vehicle accident and received the appropriate vaccines. The patient does not use tobacco, alcohol, or illicit drugs. He recently traveled from New York City to Connecticut for a family wedding. His temperature is 38.6 C (101.5 F), blood pressure is 118/70 mm Hg, and pulse is 108/min. Lung examination reveals coarse crackles. Laboratory studies are as follows:

Complete blood count	
Hemoglobin	9.6 g/dL
Reticulocytes	4%
Platelets	108,000/mm^3
Leukocytes	11,000/mm^3
Liver function studies	
Total bilirubin	1.8 mg/dL
Direct bilirubin	0.6 mg/dL
Alkaline phosphatase	120 U/L
Aspartate aminotransferase (SGOT)	87 U/L
Alanine aminotransferase (SGPT)	74 U/L
Lactate dehydrogenase	188 U/L (normal: 60-100 U/L)
Haptoglobin	36 mg/dL (normal: 50-150 mg/dL)

Direct bilirubin	0.6 mg/dL
Alkaline phosphatase	120 U/L
Aspartate aminotransferase (SGOT)	87 U/L
Alanine aminotransferase (SGPT)	74 U/L
Lactate dehydrogenase	188 U/L (normal: 60-100 U/L)
Haptoglobin	36 mg/dL (normal: 50-150 mg/dL)

Chest x-ray reveals bilateral infiltrates. A peripheral blood smear shows normocytic, normochromic anemia with ring- and cross-shaped intraerythrocytic inclusions. The vector responsible for this patient's current condition can also transmit which of the following organisms?

- A. *Borrelia burgdorferi*
- B. Dengue virus
- C. *Haemophilus influenzae*
- D. *Histoplasma capsulatum*
- E. *Neisseria meningitidis*
- F. *Plasmodium falciparum*

Submit

Direct bilirubin	0.6 mg/dL
Alkaline phosphatase	120 U/L
Aspartate aminotransferase (SGOT)	87 U/L
Alanine aminotransferase (SGPT)	74 U/L
Lactate dehydrogenase	188 U/L (normal: 60-100 U/L)
Haptoglobin	36 mg/dL (normal: 50-150 mg/dL)

Chest x-ray reveals bilateral infiltrates. A peripheral blood smear shows normocytic, normochromic anemia with ring- and cross-shaped intraerythrocytic inclusions. The vector responsible for this patient's current condition can also transmit which of the following organisms?

- ✓ A. *Borrelia burgdorferi* (72%)
- B. Dengue virus (7%)
- C. *Haemophilus influenzae* (3%)
- D. *Histoplasma capsulatum* (3%)
- E. *Neisseria meningitidis* (1%)
- F. *Plasmodium falciparum* (12%)

Omitted
Correct answer

72%
Answered correctly

01 min, 02 secs
Time Spent

01/13/2020
Last Updated

This patient with an acute febrile illness, thrombocytopenia, hemolytic anemia (indirect hyperbilirubinemia, elevated lactate dehydrogenase, low haptoglobin), abnormal liver function tests, and intraerythrocytic inclusions (ring-shaped and "Maltese cross" forms) has babesiosis, a tick-borne infection. A definitive diagnosis can be made from a Giemsa-stained thin blood smear (showing intraerythrocytic parasites). Splenectomy places patients at increased risk for severe babesiosis, which can manifest as acute respiratory distress syndrome (dyspnea, coarse crackles, bilateral infiltrates on chest x-ray).

Babesiosis (caused by *Babesia microti*) and **Lyme disease** (caused by *Borrelia burgdorferi*) are both transmitted by the *Ixodes* **tick** and occur in similar geographic regions. **Coinfection** is common and could be considered in the appropriate epidemiologic setting (eg, patients who present with babesiosis in a region endemic for Lyme disease and who do not improve despite appropriate treatment). *Ixodes* is also the vector for human granulocytic anaplasmosis.

(Choices B and F) Dengue fever and malaria may present as acute febrile illnesses, but both infections occur mainly in tropical regions. Malaria is similarly characterized by intravascular hemolysis, anemia, and abnormal liver function tests, but the blood smear frequently shows ring-shaped (not cross-shaped) erythrocyte inclusions.

(Choices C and E) Asplenic patients are at increased risk for life-threatening infections with encapsulated organisms (eg, *Streptococcus pneumoniae*, *Haemophilus influenzae*, *Neisseria meningitidis*) and therefore receive protective vaccines. Intraerythrocytic inclusions are also not seen in *H influenzae* and *N meningitidis* infections.

(Choice D) Histoplasmosis is a common mycotic infection that is most commonly found in the Ohio and Mississippi river basins and is associated with activities involving exposure to bird or bat droppings (eg, caving).

Educational objective:
Babesiosis and Lyme disease are transmitted by the *Ixodes* tick and occur in similar geographic regions. Coinfection is common.

References

- Coinfections acquired from Ixodes ticks.
- Human babesiosis.
- Tick-borne disease.

A 45-year-old man comes to the office with groin pain and swelling. About a month ago, he noticed a sore on his penis but did not seek medical attention because the ulcer was not painful and disappeared within a week. Several days ago, he began to experience painful swelling in his inguinal region, with inflammation of the overlying skin and eventual formation of several draining ulcers. He also has mild fever and malaise that began around the same time as his groin symptoms. The patient is a sailor. His other medical problems include well-controlled hypertension and hyperlipidemia. Cell scrapings from his lesions show cytoplasmic inclusion bodies. Which of the following is the most likely cause of this patient's condition?

A. *Chlamydia trachomatis*

B. *Haemophilus ducreyi*

C. Herpes simplex virus

D. *Klebsiella granulomatis*

E. *Treponema pallidum*

Submit

A 45-year-old man comes to the office with groin pain and swelling. About a month ago, he noticed a sore on his penis but did not seek medical attention because the ulcer was not painful and disappeared within a week. Several days ago, he began to experience painful swelling in his inguinal region, with inflammation of the overlying skin and eventual formation of several draining ulcers. He also has mild fever and malaise that began around the same time as his groin symptoms. The patient is a sailor. His other medical problems include well-controlled hypertension and hyperlipidemia. Cell scrapings from his lesions show cytoplasmic inclusion bodies. Which of the following is the most likely cause of this patient's condition?

- ✓ A. *Chlamydia trachomatis* (42%)
- B. *Haemophilus ducreyi* (12%)
- C. Herpes simplex virus (9%)
- D. *Klebsiella granulomatis* (6%)
- E. *Treponema pallidum* (28%)

Omitted
Correct answer
A

42%
Answered correctly

02 secs
Time Spent

01/20/2020
Last Updated

Explanation

Characteristics of ulcerative sexually transmitted diseases

	Causative		Initial

Characteristics of ulcerative sexually transmitted diseases

Disease	Causative agent	Features of primary lesion	Initial lesion painful?
Chancroid	*Haemophilus ducreyi*	• Multiple & deep ulcers • Base may have gray to yellow exudate • Organisms often clump in long parallel strands ("school of fish")	**Yes**
Genital herpes	Herpes simplex virus 1 & 2	• **Multiple**, small, grouped ulcers • Shallow with erythematous base • Multinucleated giant cells & intranuclear inclusions (Cowdry type A)	**Yes**
Granuloma inguinale (donovanosis)	*Klebsiella granulomatis*	• Extensive & progressive ulcerative lesions without lymphadenopathy • Base may have granulation-like tissue • Deeply staining gram-negative intracytoplasmic cysts	No

Granuloma inguinale (donovanosis)	*Klebsiella granulomatis*	• Extensive & progressive ulcerative lesions without lymphadenopathy • Base may have granulation-like tissue • Deeply staining gram-negative intracytoplasmic cysts (Donovan bodies)	No
Syphilis	*Treponema pallidum*	• Single, indurated, well-circumscribed ulcer • Clean base • Thin, delicate, corkscrew-shaped organisms on dark-field microscopy	No
Lymphogranuloma venereum	*Chlamydia trachomatis*	• Small & shallow ulcers • Large, painful, coalesced inguinal lymph nodes ("buboes") • Intracytoplasmic chlamydial inclusion bodies in epithelial cells & leukocytes	No

©UWorld

Chlamydia trachomatis is a small, gram-negative (albeit difficult to stain), obligate **intracellular** bacterium. Serotypes A through C cause ocular infection (trachoma) in children; serotypes D through K cause urogenital (sexually transmitted) infections and inclusion conjunctivitis; and serotypes L1 through L3 cause **lymphogranuloma venereum** (LGV).

Chlamydia trachomatis is a small, gram-negative (albeit difficult to stain), obligate **intracellular** bacterium. Serotypes A through C cause ocular infection (trachoma) in children; serotypes D through K cause urogenital (sexually transmitted) infections and inclusion conjunctivitis; and serotypes L1 through L3 cause **lymphogranuloma venereum** (LGV).

LGV is characterized initially by a painless, small, shallow genital ulcer containing infected cells. The **painless** nature helps distinguish LGV from other diseases. The appearance of the ulcer is followed weeks later by swollen, **painful**, coalescing **inguinal nodes** ("**buboes**") that can develop stellate abscesses and rupture. If left untreated, LGV can cause fibrosis, lymphatic obstruction, and anogenital strictures and fistulas. Histologically, LGV lesions contain areas of mixed granulomatous and neutrophilic inflammation with **intracytoplasmic chlamydial inclusion bodies** in epithelial and inflammatory cells.

Doxycycline is recommended. Although it is relatively uncommon in the United States or Western Europe, LGV is endemic in some parts of the world.

(Choice B) *Haemophilus ducreyi* causes chancroid, an ulcerative, sexually transmitted infection characterized by **painful** (rather than painless) red papules on the genitals that eventually erode to become tender ulcers (you "do cry" with *H ducreyi*). Regional lymph nodes may swell and become chronic ulcers.

(Choice C) Herpes simplex virus type 2 is the most common cause of genital herpes, characterized by vesicles that develop into shallow ulcers. These lesions are often painful and heal within 10 days. Histologically, multinucleated giant cells and large pinkish-purple intranuclear (not intracytoplasmic) inclusions, termed Cowdry type A bodies, are present.

(Choice D) *Klebsiella granulomatis* causes granuloma inguinale (donovanosis), which also initially manifests as a painless genital papule that eventually ulcerates; however, lymphadenopathy is uncommon. Intracytoplasmic Donovan bodies are diagnostic. If donovanosis is untreated, scarring and strictures can lead to severe lymphatic obstruction and lymphedema (elephantiasis).

(Choice E) Syphilis, caused by the gram-negative spirochete *Treponema pallidum,* is initially characterized by a painless lesion (chancre) that heals without treatment within weeks. It does not typically develop into buboes and is not characterized by cytoplasmic inclusion bodies.

Educational objective:
Chlamydia trachomatis serotypes L1 through L3 cause lymphogranuloma venereum, a sexually transmitted disease characterized initially by painless ulcers with later progression to painful inguinal lymphadenopathy ("buboes") and ulceration. Chlamydial inclusion bodies are seen in host cell cytoplasm.

Doxycycline is recommended. Although it is relatively uncommon in the United States or Western Europe, LGV is endemic in some parts of the world.

(Choice B) *Haemophilus ducreyi* causes chancroid, an ulcerative, sexually transmitted infection characterized by **painful** (rather than painless) red papules on the genitals that eventually erode to become tender ulcers (you "do cry" with *H ducreyi*). Regional lymph nodes may swell and become chronic ulcers.

(Choice C) Herpes simplex virus type 2 is the most common cause of genital herpes, characterized by vesicles that develop into shallow ulcers. These lesions are often painful and heal within 10 days. Histologically, multinucleated giant cells and large pinkish-purple intranuclear (not intracytoplasmic) inclusions, termed Cowdry type A bodies, are present.

(Choice D) *Klebsiella granulomatis* causes granuloma inguinale (donovanosis), which also initially manifests as a painless genital papule that eventually ulcerates; however, lymphadenopathy is uncommon. Intracytoplasmic Donovan bodies are diagnostic. If donovanosis is untreated, scarring and strictures can lead to severe lymphatic obstruction and lymphedema (elephantiasis).

(Choice E) Syphilis, caused by the gram-negative spirochete *Treponema pallidum,* is initially characterized by a painless lesion (chancre) that heals without treatment within weeks. It does not typically develop into buboes and is not characterized by cytoplasmic inclusion bodies.

Educational objective:
Chlamydia trachomatis serotypes L1 through L3 cause lymphogranuloma venereum, a sexually transmitted disease characterized initially by painless ulcers with later progression to painful inguinal lymphadenopathy ("buboes") and ulceration. Chlamydial inclusion bodies are seen in host cell cytoplasm.

References

- Prevention and treatment of sexually transmitted diseases: an update.

Microbiology	Infectious Diseases	Lymphogranuloma venerum
Subject	System	Topic

Copyright © UWorld. All rights reserved.

1
2
3
4
5
6
7
8
9
10
11
12
13
14
15
16
17
18
19
20
21
22
23
24
25
26
27
28
29
30
31

Exhibit Display

Zoom In | Zoom Out | Reset | Add To New Card | Existing Card

A 26-year-old man comes to the office due to a 3-day-history of dysuria and urethral discharge. The symptoms developed about 2 weeks after he had unprotected sexual intercourse with a new partner. His temperature is 37.1 C (98.8 F). On physical examination, a mucoid discharge is expressed with gentle milking of the penis. Gram stain of the discharge reveals numerous neutrophils with intracellular diplococci. A sample of the discharge is placed on an antibiotic-containing medium, and bacterial colonies are cultured. Which of the following terms best describes the medium?

- A. Differential
- B. Enrichment
- C. Reducing
- D. Selective
- E. Synthetic

Submit

A 26-year-old man comes to the office due to a 3-day-history of dysuria and urethral discharge. The symptoms developed about 2 weeks after he had unprotected sexual intercourse with a new partner. His temperature is 37.1 C (98.8 F). On physical examination, a mucoid discharge is expressed with gentle milking of the penis. Gram stain of the discharge reveals numerous neutrophils with intracellular diplococci. A sample of the discharge is placed on an antibiotic-containing medium, and bacterial colonies are cultured. Which of the following terms best describes the medium?

- A. Differential (5%)
- B. Enrichment (7%)
- C. Reducing (2%)
- ✓ D. Selective (83%)
- E. Synthetic (0%)

Omitted
Correct answer
D

83%
Answered correctly

02 secs
Time Spent

01/29/2020
Last Updated

Explanation

This patient with dysuria and urethral discharge has **gonococcal urethritis** as indicated by the Gram stain showing gram-negative diplococci within leukocytes. *Neisseria gonorrhoeae* can be cultured on Thayer-Martin VCN **selective** medium, which contains **v**ancomycin, **c**olistin, **n**ystatin, and trimethoprim. These antibiotics kill potential contaminants such as gram-positive organisms (vancomycin), gram-negative organisms other than *Neisseria* (colistin and trimethoprim), and fungi (nystatin).

(Choice A) Differential media help identify cultured organisms based on their metabolic and biochemical properties. Examples of differential

Omitted
Correct answer
D

83%
Answered correctly

02 secs
Time Spent

01/29/2020
Last Updated

Explanation

This patient with dysuria and urethral discharge has **gonococcal urethritis** as indicated by the Gram stain showing gram-negative diplococci within leukocytes. *Neisseria gonorrhoeae* can be cultured on Thayer-Martin VCN **selective** medium, which contains **v**ancomycin, **c**olistin, **n**ystatin, and trimethoprim. These antibiotics kill potential contaminants such as gram-positive organisms (vancomycin), gram-negative organisms other than *Neisseria* (colistin and trimethoprim), and fungi (nystatin).

(Choice A) Differential media help identify cultured organisms based on their metabolic and biochemical properties. Examples of differential media include the MacConkey and eosin methylene blue (EMB) agars used to culture enteric organisms. Organisms that ferment lactose will appear pink on MacConkey agar and black on EMB agar.

(Choice B) Enrichment media contain special growth factors required for some organisms. Examples include the X and V factors required by *Haemophilus* or the anaerobic conditions needed by *Clostridium* species.

(Choice C) Reducing media (eg, thioglycolate broth) remove oxygen and are used to culture anaerobic organisms.

(Choice E) A synthetic medium is any chemically-defined medium for which all of the chemical contents are known.

Educational objective:
Neisseria can be isolated by culture on selective media such as the Thayer-Martin VCN (vancomycin/colistin/nystatin) medium, which inhibits growth of contaminants such as gram-positive organisms, gram-negative organisms other than *Neisseria*, and fungi.

Microbiology	Infectious Diseases	Urethritis
Subject	System	Topic

Copyright © UWorld. All rights reserved.

A 17-year-old boy is hospitalized with recent-onset insomnia, headaches, periodic agitation, and dysphagia. He is a high school student interested in becoming a veterinarian. He owns a snake, fish, and parrot and, about 4 weeks ago, went on a field trip to study bats in a cave. The patient has no known medical problems and is not taking any medications. He does not consume alcohol and has never used illicit drugs. Despite hospitalization and treatment, he develops painful spasms, progressive paralysis, and coma and dies. Which of the following interventions would have most likely prevented this student from developing this illness?

- A. Cellular receptor inhibitor drug
- B. Inactivated vaccine
- C. Interferon therapy
- D. Live attenuated vaccine
- E. Toxoid vaccine
- F. Viral enzyme inhibitor drug

Submit

A 17-year-old boy is hospitalized with recent-onset insomnia, headaches, periodic agitation, and dysphagia. He is a high school student interested in becoming a veterinarian. He owns a snake, fish, and parrot and, about 4 weeks ago, went on a field trip to study bats in a cave. The patient has no known medical problems and is not taking any medications. He does not consume alcohol and has never used illicit drugs. Despite hospitalization and treatment, he develops painful spasms, progressive paralysis, and coma and dies. Which of the following interventions would have most likely prevented this student from developing this illness?

- A. Cellular receptor inhibitor drug (5%)
- ✓ B. Inactivated vaccine (47%)
- C. Interferon therapy (5%)
- D. Live attenuated vaccine (11%)
- E. Toxoid vaccine (26%)
- F. Viral enzyme inhibitor drug (2%)

Omitted
Correct answer
B

47%
Answered correctly

02 secs
Time Spent

03/29/2020
Last Updated

Explanation

Human rabies	
Pathogenesis	• Transmission of rabies virus by a bite from an infected mammal

Human rabies		
Pathogenesis	• Transmission of rabies virus by a bite from an infected mammal	
Reservoir	• United States: bats (most common), raccoons, skunks, foxes • Developing world: dogs	
Clinical features	**Encephalitic**	• Hydrophobia & aerophobia (due to pharyngeal spasm) • Autonomic instability • Spasticity • Agitation & altered mental status
	Paralytic	• Ascending flaccid paralysis
Postexposure prophylaxis*	• Rabies immunoglobulin • Rabies vaccine series	
Prognosis	• Coma, respiratory failure & death within weeks	

*In cases of a high-risk animal that cannot be tested or observed.

Restlessness, agitation, and dysphagia progressing to coma within weeks of exploring a bat cave is concerning for **rabies encephalitis**. Although **bats** (and, almost as commonly, raccoons) are among the main sources of rabies in the United States, many patients with bat rabies are not aware that they had been bitten. Once in a wound, the virus travels retrograde via peripheral nerves to the dorsal root ganglia and then to the brain, where replication occurs. The virus then spreads to other organs through neural pathways. Common manifestations include a nonspecific, flu-like prodrome followed by an acute neurologic syndrome with agitation, persistent fever, variable consciousness, and painful **spasms** with swallowing or inspiration (causing dysphagia, hydrophobia, and aerophobia). Generalized flaccid paralysis and coma ensue, with most patients dying within weeks.

Prophylactic vaccination is recommended for individuals at high exposure risk (eg, veterinarians, cave explorers, laboratory workers handling infected tissues, travelers to countries where rabid dogs are prevalent). **Postexposure prophylaxis** (a medical emergency) generally includes rabies immune globulin and vaccination; it is not effective after symptom onset. The approved rabies **vaccines** consist of various rhabdovirus

*In cases of a high-risk animal that cannot be tested or observed.

Restlessness, agitation, and dysphagia progressing to coma within weeks of exploring a bat cave is concerning for **rabies encephalitis**. Although **bats** (and, almost as commonly, raccoons) are among the main sources of rabies in the United States, many patients with bat rabies are not aware that they had been bitten. Once in a wound, the virus travels retrograde via peripheral nerves to the dorsal root ganglia and then to the brain, where replication occurs. The virus then spreads to other organs through neural pathways. Common manifestations include a nonspecific, flu-like prodrome followed by an acute neurologic syndrome with agitation, persistent fever, variable consciousness, and painful **spasms** with swallowing or inspiration (causing dysphagia, hydrophobia, and aerophobia). Generalized flaccid paralysis and coma ensue, with most patients dying within weeks.

Prophylactic vaccination is recommended for individuals at high exposure risk (eg, veterinarians, cave explorers, laboratory workers handling infected tissues, travelers to countries where rabid dogs are prevalent). **Postexposure prophylaxis** (a medical emergency) generally includes rabies immune globulin and vaccination; it is not effective after symptom onset. The approved rabies **vaccines** consist of various rhabdovirus strains grown in tissue cell culture and **inactivated** by beta-propiolactone.

(Choices A, C, and F) No antirabies drugs targeting specific viral pathways (eg, cellular entry) are available, and interferon is not used in rabies management.

(Choice D) Some live attenuated rabies vaccines have been used in wild animal populations, but none are currently recommended in humans. The herpes zoster (shingles), varicella, and yellow fever vaccines are live attenuated.

(Choice E) Toxoid (prepared from formalin- or heat-treated toxin) can induce humoral immunity against the corresponding toxin without producing serious toxic effects. However, rabies does not appear predominantly toxin-mediated. The tetanus-(reduced) diphtheria vaccine contains inactivated bacterial toxoids.

Educational objective:
In the United States, bats are the main source of rabies (only transmitted by mammals). Agitation and spasms progressing to coma within weeks of exposure is strongly suggestive of rabies encephalitis. Prophylactic vaccination is recommended for individuals at high risk for exposure to rabid animals or their tissues. The approved rabies vaccines consist of various rhabdovirus strains grown in tissue cell culture and then inactivated.

brain, where replication occurs. The virus then spreads to other organs through neural pathways. Common manifestations include a nonspecific, flu-like prodrome followed by an acute neurologic syndrome with agitation, persistent fever, variable consciousness, and painful **spasms** with swallowing or inspiration (causing dysphagia, hydrophobia, and aerophobia). Generalized flaccid paralysis and coma ensue, with most patients dying within weeks.

Prophylactic vaccination is recommended for individuals at high exposure risk (eg, veterinarians, cave explorers, laboratory workers handling infected tissues, travelers to countries where rabid dogs are prevalent). **Postexposure prophylaxis** (a medical emergency) generally includes rabies immune globulin and vaccination; it is not effective after symptom onset. The approved rabies **vaccines** consist of various rhabdovirus strains grown in tissue cell culture and **inactivated** by beta-propiolactone.

(Choices A, C, and F) No antirabies drugs targeting specific viral pathways (eg, cellular entry) are available, and interferon is not used in rabies management.

(Choice D) Some live attenuated rabies vaccines have been used in wild animal populations, but none are currently recommended in humans. The herpes zoster (shingles), varicella, and yellow fever vaccines are live attenuated.

(Choice E) Toxoid (prepared from formalin- or heat-treated toxin) can induce humoral immunity against the corresponding toxin without producing serious toxic effects. However, rabies does not appear predominantly toxin-mediated. The tetanus-(reduced) diphtheria vaccine contains inactivated bacterial toxoids.

Educational objective:
In the United States, bats are the main source of rabies (only transmitted by mammals). Agitation and spasms progressing to coma within weeks of exposure is strongly suggestive of rabies encephalitis. Prophylactic vaccination is recommended for individuals at high risk for exposure to rabid animals or their tissues. The approved rabies vaccines consist of various rhabdovirus strains grown in tissue cell culture and then inactivated.

Microbiology	Infectious Diseases	Rabies
Subject	System	Topic

Copyright © UWorld. All rights reserved.

1
2
3
4
5
6
7
8
9
10
11
12
13
14
15
16
17
18
19
20
21
22
23
24
25
26
27
28
29
30
31

A 24-year-old previously healthy man comes to the office due to a week of low-grade fever, malaise, sore throat, and persistent nonproductive cough. He does not use tobacco, alcohol, or illicit drugs. The patient takes no medications and has no drug allergies. He lives in Connecticut and has not traveled recently. Physical examination reveals mild pharyngeal erythema, no nasal congestion, and bilateral vesicular breath sounds with no crackles or wheezes. Chest x-ray shows patchy, interstitial infiltrates. Sputum Gram stain shows numerous leukocytes but no organisms. Which of the following agents is the best initial treatment for this patient?

A. Antagonist of folate metabolism

B. Inhibitor of bacterial cell wall synthesis

C. Inhibitor of bacterial protein synthesis

D. Inhibitor of ergosterol synthesis

E. Inhibitor of mycolic acid synthesis

Submit

A 24-year-old previously healthy man comes to the office due to a week of low-grade fever, malaise, sore throat, and persistent nonproductive cough. He does not use tobacco, alcohol, or illicit drugs. The patient takes no medications and has no drug allergies. He lives in Connecticut and has not traveled recently. Physical examination reveals mild pharyngeal erythema, no nasal congestion, and bilateral vesicular breath sounds with no crackles or wheezes. Chest x-ray shows patchy, interstitial infiltrates. Sputum Gram stain shows numerous leukocytes but no organisms. Which of the following agents is the best initial treatment for this patient?

A. Antagonist of folate metabolism (3%)

B. Inhibitor of bacterial cell wall synthesis (5%)

✓ C. Inhibitor of bacterial protein synthesis (61%)

D. Inhibitor of ergosterol synthesis (15%)

E. Inhibitor of mycolic acid synthesis (13%)

Omitted
Correct answer
C

61%
Answered correctly

02 secs
Time Spent

04/09/2020
Last Updated

Explanation

This patient with low-grade fever, sore throat, persistent cough, and chest x-ray evidence of a bilateral patchy infiltrate likely has "walking pneumonia", a form of **atypical pneumonia** usually caused by ***Mycoplasma pneumoniae*** or *Chlamydia pneumoniae*.

Unlike most bacteria, *Mycoplasma* and *Chlamydia* do not have cell walls composed of peptidoglycan. *Mycoplasma* **completely lacks a cell wall**, while *Chlamydia* has a cell wall composed of an alternate protein. Therefore, these pathogens cannot be seen on Gram stain (which stains peptidoglycan) and cannot be treated with antibacterial agents that target peptidoglycan such as penicillins, cephalosporins, vancomycin, or

This patient with low-grade fever, sore throat, persistent cough, and chest x-ray evidence of a bilateral patchy infiltrate likely has "walking pneumonia", a form of **atypical pneumonia** usually caused by ***Mycoplasma pneumoniae*** or *Chlamydia pneumoniae*.

Unlike most bacteria, *Mycoplasma* and *Chlamydia* do not have cell walls composed of peptidoglycan. *Mycoplasma* **completely lacks a cell wall**, while *Chlamydia* has a cell wall composed of an alternate protein. Therefore, these pathogens cannot be seen on Gram stain (which stains peptidoglycan) and cannot be treated with antibacterial agents that target peptidoglycan such as penicillins, cephalosporins, vancomycin, or carbapenems **(Choice B)**. Treatment requires a **bacterial protein synthesis inhibitor** such as a macrolide or tetracycline.

Legionella pneumophila is another common cause of atypical pneumonia. However, this pathogen usually is associated with gastrointestinal symptoms (eg, diarrhea), more severe clinical illness (eg, high fever), and lobar infiltrate on chest x-ray.

(Choice A) Trimethoprim and sulfamethoxazole are folate metabolism antagonists. They are the first-line therapy for *Pneumocystis* pneumonia, which often presents with subacute pulmonary symptoms and a bilateral patchy interstitial infiltrate. However, most patients have significant shortness of breath and nearly all are immunocompromised (eg, AIDS, chronic steroids).

(Choice D) Azole medications (eg, fluconazole) inhibit the synthesis of ergosterol, a primary component of the fungal cell membrane. Fungal pneumonias are often associated with lobar, nodular, or cavitary infiltrates. However, most occur in the setting of immunosuppression, and an accompanying sore throat would be unusual.

(Choice E) Mycolic acid is found in the cell wall of *Mycobacterium* and can be targeted by isoniazid, a mycolic acid synthesis inhibitor. Active pulmonary tuberculosis often presents with several weeks of cough, weight loss, malaise, and upper lobe cavitary infiltrates.

Educational objective:
Mycoplasma pneumoniae is a leading cause of atypical pneumonia. Because this pathogen lacks a cell wall, it does not show up on Gram stain and cannot be treated with beta-lactam antibiotics. Protein synthesis inhibitors (eg, macrolides, tetracycline) are the treatment of choice.

Microbiology	Infectious Diseases	Community acquired pneumonia
Subject	System	Topic

Copyright © UWorld. All rights reserved.

1
2
3
4
5
6
7
8
9
10
11
12
13
14
15
16
17
18
19
20
21
22
23
24
25
26
27
28
29
30
31

A 26-year-old woman comes to the office due to fever, malaise, and joint pain. A week ago, the patient had pain in the small joints of her right hand, which improved spontaneously but was quickly followed by pain in the right ankle and left wrist. She has no prior medical problems and takes no medications. Temperature is 38 C (100.4 F), blood pressure is 124/82 mm Hg, and pulse is 90/min. The extremity joints are not erythematous or swollen, but tenderness is present along the tendons of the left wrist and right ankle. Several small, nontender pustules are seen on the extremities. There is no other rash. Blood culture in a selective growth medium consisting of chocolate agar and multiple antibiotics yields the causative pathogen. Which of the following strategies would most likely have prevented this patient's current condition?

A. Avoiding bites from ticks

B. Obtaining adequate vaccinations

C. Thoroughly cooking meat products

D. Using condoms consistently

E. Using mosquito repellents

Submit

A 26-year-old woman comes to the office due to fever, malaise, and joint pain. A week ago, the patient had pain in the small joints of her right hand, which improved spontaneously but was quickly followed by pain in the right ankle and left wrist. She has no prior medical problems and takes no medications. Temperature is 38 C (100.4 F), blood pressure is 124/82 mm Hg, and pulse is 90/min. The extremity joints are not erythematous or swollen, but tenderness is present along the tendons of the left wrist and right ankle. Several small, nontender pustules are seen on the extremities. There is no other rash. Blood culture in a selective growth medium consisting of chocolate agar and multiple antibiotics yields the causative pathogen. Which of the following strategies would most likely have prevented this patient's current condition?

- A. Avoiding bites from ticks (7%)
- B. Obtaining adequate vaccinations (13%)
- C. Thoroughly cooking meat products (1%)
- ✓ D. Using condoms consistently (75%)
- E. Using mosquito repellents (1%)

Omitted
Correct answer
D

75%
Answered correctly

02 secs
Time Spent

01/26/2020
Last Updated

Explanation

Disseminated gonococcal infection occurs when *Neisseria gonorrhoeae* spreads from the genitourinary tract to the bloodstream. It typically presents with the triad of polyarthralgia, tenosynovitis, and dermatitis (painless pustules on the extremities) or purulent arthritis. The diagnosis is confirmed when the organism is isolated on **Thayer-Martin media**, chocolate agar infused with antibiotics.

N gonorrhoeae is spread primarily via infected genital secretions during **sexual contact**. Therefore, most cases can be prevented by the

Disseminated gonococcal infection occurs when *Neisseria gonorrhoeae* spreads from the genitourinary tract to the bloodstream. It typically presents with the triad of polyarthralgia, tenosynovitis, and dermatitis (painless pustules on the extremities) or purulent arthritis. The diagnosis is confirmed when the organism is isolated on **Thayer-Martin media**, chocolate agar infused with antibiotics.

N gonorrhoeae is spread primarily via infected genital secretions during **sexual contact**. Therefore, most cases can be prevented by the **consistent use of condoms**, which act as a mucosal barrier between sexual partners. Patients with genitourinary *N gonorrhoeae* infections may have purulent cervicitis or urethritis, but many are asymptomatic. Asymptomatic infection increases the risk of spread to deeper tissues (eg, disseminated gonococcal infection, pelvic inflammatory disease) because of treatment delay.

(Choice A) Lyme disease is a tick-borne illness caused by the spirochete *Borrelia burgdorferi*. Early localized Lyme disease can be associated with arthralgias, myalgias, fever, and erythema migrans (a migrating, erythematous, bull's-eye rash). However, it is not associated with tendonitis/pustules, and spirochetes cannot be cultured on Thayer-Martin media.

(Choice B) *N gonorrhoeae* undergoes dramatic antigenic variation of its surface molecules, which prevents the formation of protective antibodies against future infection. Therefore, recurrent infection is common and vaccinations are ineffective.

(Choice C) The roundworm *Trichinella* can be transmitted via undercooked pork. It invades the skeletal muscle and causes severe muscle pain, swelling, and tenderness. Periorbital edema and eosinophilia are often important diagnostic clues. Diagnosis is made by serology; culture on Thayer-Martin media is not performed.

(Choice E) Dengue fever, also called breakbone fever, is a mosquito-borne viral infection associated with fever, severe myalgias, arthralgias, and macular rash. Hemorrhagic complications can occur. The diagnosis is usually made clinically; Thayer-Martin media would not yield an organism (as it is a viral pathogen).

Educational objective:
Neisseria gonorrhoeae is spread sexually by genitourinary secretions and can be prevented by the consistent use of condoms. Genitourinary infections are often asymptomatic, which increases the risk of spread through the bloodstream, leading to disseminated gonococcal infection. Patients with disseminated disease typically present with the triad of polyarthralgia, tenosynovitis, and dermatitis or purulent arthritis.

Microbiology Infectious Diseases Gonococcal infection

confirmed when the organism is isolated on **Thayer-Martin media**, chocolate agar infused with antibiotics.

N gonorrhoeae is spread primarily via infected genital secretions during **sexual contact**. Therefore, most cases can be prevented by the **consistent use of condoms**, which act as a mucosal barrier between sexual partners. Patients with genitourinary *N gonorrhoeae* infections may have purulent cervicitis or urethritis, but many are asymptomatic. Asymptomatic infection increases the risk of spread to deeper tissues (eg, disseminated gonococcal infection, pelvic inflammatory disease) because of treatment delay.

(Choice A) Lyme disease is a tick-borne illness caused by the spirochete *Borrelia burgdorferi*. Early localized Lyme disease can be associated with arthralgias, myalgias, fever, and erythema migrans (a migrating, erythematous, bull's-eye rash). However, it is not associated with tendonitis/pustules, and spirochetes cannot be cultured on Thayer-Martin media.

(Choice B) *N gonorrhoeae* undergoes dramatic antigenic variation of its surface molecules, which prevents the formation of protective antibodies against future infection. Therefore, recurrent infection is common and vaccinations are ineffective.

(Choice C) The roundworm *Trichinella* can be transmitted via undercooked pork. It invades the skeletal muscle and causes severe muscle pain, swelling, and tenderness. Periorbital edema and eosinophilia are often important diagnostic clues. Diagnosis is made by serology; culture on Thayer-Martin media is not performed.

(Choice E) Dengue fever, also called breakbone fever, is a mosquito-borne viral infection associated with fever, severe myalgias, arthralgias, and macular rash. Hemorrhagic complications can occur. The diagnosis is usually made clinically; Thayer-Martin media would not yield an organism (as it is a viral pathogen).

Educational objective:
Neisseria gonorrhoeae is spread sexually by genitourinary secretions and can be prevented by the consistent use of condoms. Genitourinary infections are often asymptomatic, which increases the risk of spread through the bloodstream, leading to disseminated gonococcal infection. Patients with disseminated disease typically present with the triad of polyarthralgia, tenosynovitis, and dermatitis or purulent arthritis.

Microbiology	Infectious Diseases	Gonococcal infection
Subject	System	Topic

Copyright © UWorld. All rights reserved.

confirmed when the organism is isolated on **Thayer-Martin media**, chocolate agar infused with antibiotics.

Exhibit Display

Zoom In | Zoom Out | Reset | Add To New Card | Existing Card

confirmed when the organism is isolated on **Thayer-Martin media**, chocolate agar infused with antibiotics.

Exhibit Display

Zoom In | Zoom Out | Reset | Add To New Card | Existing Card

1
2
3
4
5
6
7
8
9
10
11
12
13
14
15
16
17
18
19
20
21
22
23
24
25
26
27
28
29
30
31

A 6-day-old boy is brought to the emergency department for inability to feed for 12 hours. His parents report that the infant has been unable to open his mouth and has held his hands clenched all day. The infant was delivered at home by the grandmother. The mother had no access to prenatal care but says that the pregnancy was uncomplicated. The mother immigrated to the United States 6 years ago. Physical examination shows increased muscle tone throughout, arching of the back, and dorsiflexed feet. The umbilical cord is covered with a clump of soil. The mother says that it is customary in her village where she grew up to cover the umbilical stump with dung to speed cord separation. In addition to hygienic umbilical cord care, which of the following is the most effective strategy to prevent this condition?

A. Early postpartum breastfeeding
B. Prophylactic antibiotics
C. Prophylactic immune globulin
D. Vaccination of infants at birth
E. Vaccination of pregnant women

Submit

A 6-day-old boy is brought to the emergency department for inability to feed for 12 hours. His parents report that the infant has been unable to open his mouth and has held his hands clenched all day. The infant was delivered at home by the grandmother. The mother had no access to prenatal care but says that the pregnancy was uncomplicated. The mother immigrated to the United States 6 years ago. Physical examination shows increased muscle tone throughout, arching of the back, and dorsiflexed feet. The umbilical cord is covered with a clump of soil. The mother says that it is customary in her village where she grew up to cover the umbilical stump with dung to speed cord separation. In addition to hygienic umbilical cord care, which of the following is the most effective strategy to prevent this condition?

- A. Early postpartum breastfeeding (3%)
- B. Prophylactic antibiotics (5%)
- C. Prophylactic immune globulin (17%)
- D. Vaccination of infants at birth (17%)
- ✓ E. Vaccination of pregnant women (56%)

Omitted
Correct answer
E

56%
Answered correctly

02 secs
Time Spent

02/16/2020
Last Updated

Explanation

Neonatal tetanus	
	• Difficulty feeding, **trismus**

1
2
3
4
5
6
7
8
9
10
11
12
13
14
15
16
17
18
19
20
21
22
23
24
25
26
27
28
29
30
31

Neonatal tetanus	
Clinical features	• Difficulty feeding, **trismus** • Spasms & hypertonicity ○ Clenched hands, dorsiflexed feet, **opisthotonus** • Eventual respiratory failure
Treatment	• Supportive care • Antibiotics & tetanus immune globulin
Prevention	• Immunization of pregnant women & those of childbearing age • Hygienic delivery & cord care

©UWorld

Neonatal tetanus (tetanus neonatorum) is a major cause of infant mortality in developing countries but is rare in the United States. Neonatal tetanus results from the introduction of *Clostridium tetani* spores to the infant, generally from **unhygienic deliveries or cord care**. Symptoms typically begin 5-7 days after birth and can progress more rapidly than in adults. Infected infants become irritable and have difficulty feeding and suckling due to tonic spasm of the masticatory muscles (trismus). As the disease progresses, **spasms and hypertonicity** become more generalized. Mortality approaches 100% without treatment.

Prevention of neonatal tetanus focuses on **vaccinating women** who are pregnant or may become pregnant with inactivated tetanus toxin (tetanus toxoid). Appropriately vaccinated women provide **transplacental IgG** to the fetus, which decreases the incidence of neonatal tetanus by approximately 95%.

(Choice A) Secretory IgA found in breast milk helps prevent respiratory and gastrointestinal infections in the newborn by providing mucosal immune support. However, adequate protection against neonatal tetanus requires the presence of toxin-neutralizing, circulating IgG antibodies that are obtained transplacentally.

Neonatal tetanus (tetanus neonatorum) is a major cause of infant mortality in developing countries but is rare in the United States. Neonatal tetanus results from the introduction of *Clostridium tetani* spores to the infant, generally from **unhygienic deliveries or cord care**. Symptoms typically begin 5-7 days after birth and can progress more rapidly than in adults. Infected infants become irritable and have difficulty feeding and suckling due to tonic spasm of the masticatory muscles (trismus). As the disease progresses, **spasms and hypertonicity** become more generalized. Mortality approaches 100% without treatment.

Prevention of neonatal tetanus focuses on **vaccinating women** who are pregnant or may become pregnant with inactivated tetanus toxin (tetanus toxoid). Appropriately vaccinated women provide **transplacental IgG** to the fetus, which decreases the incidence of neonatal tetanus by approximately 95%.

(Choice A) Secretory IgA found in breast milk helps prevent respiratory and gastrointestinal infections in the newborn by providing mucosal immune support. However, adequate protection against neonatal tetanus requires the presence of toxin-neutralizing, circulating IgG antibodies that are obtained transplacentally.

(Choices B and C) Treatment of tetanus, including neonatal tetanus, involves the use of antibiotics to kill *C tetani* and administration of tetanus immune globulin to neutralize unbound toxin. However, these agents are not used for tetanus prevention.

(Choice D) Tetanus vaccination is not given at birth because the neonatal immune system is immature and unable to mount a proper memory immune response against the tetanus toxoid. The first dose of the diphtheria-pertussis-tetanus series is commonly administered at 2 months of age. In areas of endemic tetanus disease, this vaccine can be given as early as 4-6 weeks of age, but not earlier.

Educational objective:
Neonatal tetanus can be prevented by hygienic delivery and umbilical cord care and universal immunization of women who are pregnant or may become pregnant. Immunized mothers provide passive immunity via transplacental IgG, protecting infants until they receive active immunization (vaccination) around age 2 months.

References

- Maternal and neonatal tetanus.
- Vaccines for women to prevent neonatal tetanus.

A 43-year-old man comes to the office due to fatigue and worsening pedal edema over the past several weeks. The patient was diagnosed with advanced HIV infection and started on antiretroviral therapy 3 months ago. He also has a history of hypertension. Physical examination shows bilateral lower extremity pitting edema. Serum creatinine is elevated and serum phosphorus is decreased compared to test results 3 months ago. Urinalysis reveals moderate proteinuria and glucosuria. Renal biopsy shows cytoplasmic vacuolization in the proximal tubules accompanied by loss of brush border and basement membrane denudation. Intracytoplasmic eosinophilic inclusions are also seen in the proximal tubules. There are no significant interstitial inflammatory infiltrates, and the glomeruli appear normal. Which of the following is the most likely diagnosis in this patient?

A. HIV-associated nephropathy
B. Hypertensive nephrosclerosis
C. Postinfectious glomerulonephritis
D. Tenofovir-induced nephrotoxicity
E. Trimethoprim-sulfamethoxazole–induced nephrotoxicity

Submit

A 43-year-old man comes to the office due to fatigue and worsening pedal edema over the past several weeks. The patient was diagnosed with advanced HIV infection and started on antiretroviral therapy 3 months ago. He also has a history of hypertension. Physical examination shows bilateral lower extremity pitting edema. Serum creatinine is elevated and serum phosphorus is decreased compared to test results 3 months ago. Urinalysis reveals moderate proteinuria and glucosuria. Renal biopsy shows cytoplasmic vacuolization in the proximal tubules accompanied by loss of brush border and basement membrane denudation. Intracytoplasmic eosinophilic inclusions are also seen in the proximal tubules. There are no significant interstitial inflammatory infiltrates, and the glomeruli appear normal. Which of the following is the most likely diagnosis in this patient?

A. HIV-associated nephropathy (18%)
B. Hypertensive nephrosclerosis (4%)
C. Postinfectious glomerulonephritis (3%)
✓ D. Tenofovir-induced nephrotoxicity (55%)
E. Trimethoprim-sulfamethoxazole–induced nephrotoxicity (17%)

Omitted
Correct answer
D

55%
Answered correctly

02 secs
Time Spent

02/23/2020
Last Updated

Explanation

This patient with HIV was recently started on antiretroviral therapy and subsequently developed evidence of proximal tubule dysfunction (eg, hypophosphatemia, glucosuria, proteinuria, biopsy abnormalities), raising concern for **tenofovir-induced nephrotoxicity**. Tenofovir is a common part of first-line HIV therapy. It is an adenosine analogue that is a member of the **nucleotide reverse transcriptase inhibitors** (NRTIs). NRTIs

Explanation

This patient with HIV was recently started on antiretroviral therapy and subsequently developed evidence of proximal tubule dysfunction (eg, hypophosphatemia, glucosuria, proteinuria, biopsy abnormalities), raising concern for **tenofovir-induced nephrotoxicity**. Tenofovir is a common part of first-line HIV therapy. It is an adenosine analogue that is a member of the **nucleotide reverse transcriptase inhibitors** (NRTIs). NRTIs prevent reverse transcriptase from converting the HIV RNA genome into complementary double-stranded DNA, which inhibits viral replication.

Tenofovir is primarily eliminated via the proximal tubule cells of the kidney. High concentrations of tenofovir in these cells can interfere with mitochondrial DNA synthesis and result in cellular damage. This typically manifests with **acute kidney injury** (eg, elevated creatinine, water retention) and/or signs of **proximal tubule dysfunction** (eg, phosphaturia, glucosuria, proteinuria). Histopathology may show damage to proximal tubule cells (eg, loss of brush border, basement membrane denudation) and evidence of giant mitochondria (eg, large eosinophilic inclusions). Renal abnormalities typically improve once tenofovir is discontinued.

(Choice A) HIV-associated nephropathy is due to viral infection of kidney epithelial cells and typically manifests with hematuria, hypertension, and edema. Biopsy classically shows focal segmental glomerulosclerosis and significant interstitial inflammation.

(Choice B) Hypertensive nephrosclerosis is most common in black patients who have markedly elevated blood pressure. It usually is characterized by proteinuria with or without renal insufficiency. Biopsy typically reveals damage to the renal vasculature (eg, intimal thickening, luminal narrowing), glomeruli (eg, glomerulosclerosis), and renal interstitium (eg, fibrosis, atrophy).

(Choice C) Poststreptococcal glomerulonephritis is an immune complex disease of the glomeruli caused by a preceding infection with a nephritogenic strain of group A beta-hemolytic streptococcus. Patients may have proteinuria, edema, hypertension, and/or acute kidney injury. However, they usually also have red/brown urine and biopsy evidence of diffuse proliferative glomerulonephritis.

(Choice E) Trimethoprim-sulfamethoxazole is often used in patients with advanced AIDS to prevent *Pneumocystis* pneumonia and/or *Toxoplasma gondii*. It can cause interstitial nephritis and acute kidney injury but does not usually cause focal damage to the proximal tubule.

Educational objective:
Tenofovir is a nucleotide reverse transcriptase inhibitor that is a common component of HIV therapy. This drug is generally well tolerated but may occasionally cause damage to the proximal tubule of the kidney, leading to acute kidney injury and/or proximal tubule impairment (eg, phosphoruria, glucosuria, proteinuria, water retention). Biopsy typically reveals a normal glomerulus and renal interstitium but damage to the

1 2 3 4 5 6 7 8 9 10 11 12 13 14 15 16 17 18 19 20 21 22 23 24 25 26 27 28 29 30 31

Tenofovir is primarily eliminated via the proximal tubule cells of the kidney. High concentrations of tenofovir in these cells can interfere with mitochondrial DNA synthesis and result in cellular damage. This typically manifests with **acute kidney injury** (eg, elevated creatinine, water retention) and/or signs of **proximal tubule dysfunction** (eg, phosphaturia, glucosuria, proteinuria). Histopathology may show damage to proximal tubule cells (eg, loss of brush border, basement membrane denudation) and evidence of giant mitochondria (eg, large eosinophilic inclusions). Renal abnormalities typically improve once tenofovir is discontinued.

(Choice A) HIV-associated nephropathy is due to viral infection of kidney epithelial cells and typically manifests with hematuria, hypertension, and edema. Biopsy classically shows focal segmental glomerulosclerosis and significant interstitial inflammation.

(Choice B) Hypertensive nephrosclerosis is most common in black patients who have markedly elevated blood pressure. It usually is characterized by proteinuria with or without renal insufficiency. Biopsy typically reveals damage to the renal vasculature (eg, intimal thickening, luminal narrowing), glomeruli (eg, glomerulosclerosis), and renal interstitium (eg, fibrosis, atrophy).

(Choice C) Poststreptococcal glomerulonephritis is an immune complex disease of the glomeruli caused by a preceding infection with a nephritogenic strain of group A beta-hemolytic streptococcus. Patients may have proteinuria, edema, hypertension, and/or acute kidney injury. However, they usually also have red/brown urine and biopsy evidence of diffuse proliferative glomerulonephritis.

(Choice E) Trimethoprim-sulfamethoxazole is often used in patients with advanced AIDS to prevent *Pneumocystis* pneumonia and/or *Toxoplasma gondii*. It can cause interstitial nephritis and acute kidney injury but does not usually cause focal damage to the proximal tubule.

Educational objective:
Tenofovir is a nucleotide reverse transcriptase inhibitor that is a common component of HIV therapy. This drug is generally well tolerated but may occasionally cause damage to the proximal tubule of the kidney, leading to acute kidney injury and/or proximal tubule impairment (eg, phosphoruria, glucosuria, proteinuria, water retention). Biopsy typically reveals a normal glomerulus and renal interstitium but damage to the proximal tubule.

Microbiology	Infectious Diseases	HIV
Subject	System	Topic

Copyright © UWorld. All rights reserved.

1
2
3
4
5
6
7
8
9
10
11
12
13
14
15
16
17
18
19
20
21
22
23
24
25
26
27
28
29
30
31

A group of researchers is investigating the causative agents responsible for infections in immunocompromised individuals. Patients with solid-organ malignancy who have received conventional chemotherapy are enrolled in the study. Detailed microbiologic data are obtained on any patient who develops fever during chemotherapy-induced neutropenia. Which of the following types of pathogens are most likely to be obtained in the majority of these patients?

A. Environmental, opportunistic pathogens

B. Hospital-acquired, drug-resistant bacteria

C. Pathogens spread from infected contacts

D. Patient's own endogenous bacterial flora

E. Previously latent, reactivated pathogens

Submit

A group of researchers is investigating the causative agents responsible for infections in immunocompromised individuals. Patients with solid-organ malignancy who have received conventional chemotherapy are enrolled in the study. Detailed microbiologic data are obtained on any patient who develops fever during chemotherapy-induced neutropenia. Which of the following types of pathogens are most likely to be obtained in the majority of these patients?

- A. Environmental, opportunistic pathogens (50%)
- B. Hospital-acquired, drug-resistant bacteria (7%)
- C. Pathogens spread from infected contacts (5%)
- ✓ D. Patient's own endogenous bacterial flora (25%)
- E. Previously latent, reactivated pathogens (10%)

Omitted
Correct answer
D

25%
Answered correctly

02 secs
Time Spent

03/08/2020
Last Updated

Explanation

Systemic chemotherapy targets rapidly dividing cancer cells but often incidentally damages other rapidly dividing cells in the gastrointestinal tract and bone marrow, which dramatically **increases the risk of infection** due to:

- **Mucositis** – Damage to rapidly dividing epithelial cells of the digestive tract creates breaches in the mucosal barrier that allow **endogenous bacterial flora** (commensal organisms) to penetrate and enter the bloodstream. Gram-negative enteric bacilli, such as *Pseudomonas aeruginosa*, and gram-positive skin organisms, such as *Staphylococcus epidermidis* and *S aureus*, are most likely to invade.
- **Neutropenia** – Damage to rapidly dividing granulopoietic cells reduces circulating neutrophil count. Because neutrophils serve as front-line

Systemic chemotherapy targets rapidly dividing cancer cells but often incidentally damages other rapidly dividing cells in the gastrointestinal tract and bone marrow, which dramatically **increases the risk of infection** due to:

- **Mucositis** – Damage to rapidly dividing epithelial cells of the digestive tract creates breaches in the mucosal barrier that allow **endogenous bacterial flora** (commensal organisms) to penetrate and enter the bloodstream. Gram-negative enteric bacilli, such as *Pseudomonas aeruginosa*, and gram-positive skin organisms, such as *Staphylococcus epidermidis* and *S aureus*, are most likely to invade.
- **Neutropenia** – Damage to rapidly dividing granulopoietic cells reduces circulating neutrophil count. Because neutrophils serve as front-line defense against bacterial and fungal pathogens, commensal pathogens that penetrate the mucosal/cutaneous barrier cannot be contained and subsequently spread to the bloodstream and deeper tissues. Neutropenic patients have weak inflammatory responses and **fever** is often the **only sign of infection** (neutropenic fever).

To reduce the risk of serious infection, patients who receive systemic chemotherapy are often empirically treated with prophylactic antibiotics (eg, ciprofloxacin) to prevent commensal organisms from invading and with granulocyte-stimulating agents (eg, filgrastim) to increase neutrophil count.

(Choice A) Environmental pathogens such as *Histoplasma* (in bird droppings), Mycobacterium avium complex (in water), and *Cryptococcus* (in soil contaminated by bird droppings) often cause opportunistic infection in those with advanced AIDS due to impaired cell-mediated immunity. Although these pathogens can cause infections in those with neutropenia, most cases of neutropenic fever are due to endogenous commensal organisms.

(Choice B) Hospital-acquired, drug-resistant bacteria, such as methicillin-resistant *S aureus*, can cause neutropenic fever but do so much less often than endogenous commensal bacteria.

(Choice C) Pathogens spread from infected contacts (eg, influenza) are more likely to cause severe infection in those with impaired immunity. However, the greatest cause of neutropenic fever is endogenous bacterial flora.

(Choice E) The reactivation of latent bacterial (eg, tuberculosis) and viral (eg, cytomegalovirus) pathogens is common in those with impaired cellular immunity (eg, AIDS, immunosuppression). However, endogenous commensal bacteria are a more likely cause of fever in neutropenic patients.

Educational objective:
Chemotherapy-associated neutropenic fever is most often caused by endogenous commensal bacteria that have translocated across damaged

often the **only sign of infection** (neutropenic fever).

To reduce the risk of serious infection, patients who receive systemic chemotherapy are often empirically treated with prophylactic antibiotics (eg, ciprofloxacin) to prevent commensal organisms from invading and with granulocyte-stimulating agents (eg, filgrastim) to increase neutrophil count.

(Choice A) Environmental pathogens such as *Histoplasma* (in bird droppings), Mycobacterium avium complex (in water), and *Cryptococcus* (in soil contaminated by bird droppings) often cause opportunistic infection in those with advanced AIDS due to impaired cell-mediated immunity. Although these pathogens can cause infections in those with neutropenia, most cases of neutropenic fever are due to endogenous commensal organisms.

(Choice B) Hospital-acquired, drug-resistant bacteria, such as methicillin-resistant *S aureus*, can cause neutropenic fever but do so much less often than endogenous commensal bacteria.

(Choice C) Pathogens spread from infected contacts (eg, influenza) are more likely to cause severe infection in those with impaired immunity. However, the greatest cause of neutropenic fever is endogenous bacterial flora.

(Choice E) The reactivation of latent bacterial (eg, tuberculosis) and viral (eg, cytomegalovirus) pathogens is common in those with impaired cellular immunity (eg, AIDS, immunosuppression). However, endogenous commensal bacteria are a more likely cause of fever in neutropenic patients.

Educational objective:
Chemotherapy-associated neutropenic fever is most often caused by endogenous commensal bacteria that have translocated across damaged mucosal sites.

References

- Microbial etiology of febrile neutropenia.

Microbiology	Infectious Diseases	Febrile neutropenia
Subject	System	Topic

Copyright © UWorld. All rights reserved.

1
2
3
4
5
6
7
8
9
10
11
12
13
14
15
16
17
18
19
20
21
22
23
24
25
26
27
28
29
30
31

A previously healthy 24-year-old man is hospitalized due to 3 days of fever, chills, myalgia, and severe headache. The symptoms started on the last day of his camping trip in the Appalachian Mountains and have rapidly progressed. Temperature is 38.9 C (102 F), blood pressure is 100/56 mm Hg, and pulse is 120/min. On examination, the patient is lethargic and confused. There is no neck rigidity. The lungs are clear on auscultation and heart sounds are normal. The abdomen is soft and nontender. There is a prominent erythematous maculopapular rash on the distal forearms. No lymphadenopathy is present. The patient should be immediately initiated on a medication that targets which of the following?

A. Bacterial DNA unwinding

B. Bacterial folate metabolism

C. Bacterial protein synthesis

D. Fungal ergosterol synthesis

E. Spirochetal cell wall formation

F. Viral reverse transcription

Submit

A previously healthy 24-year-old man is hospitalized due to 3 days of fever, chills, myalgia, and severe headache. The symptoms started on the last day of his camping trip in the Appalachian Mountains and have rapidly progressed. Temperature is 38.9 C (102 F), blood pressure is 100/56 mm Hg, and pulse is 120/min. On examination, the patient is lethargic and confused. There is no neck rigidity. The lungs are clear on auscultation and heart sounds are normal. The abdomen is soft and nontender. There is a prominent erythematous maculopapular rash on the distal forearms. No lymphadenopathy is present. The patient should be immediately initiated on a medication that targets which of the following?

- A. Bacterial DNA unwinding (2%)
- B. Bacterial folate metabolism (2%)
- ✓ C. Bacterial protein synthesis (76%)
- D. Fungal ergosterol synthesis (4%)
- E. Spirochetal cell wall formation (11%)
- F. Viral reverse transcription (2%)

Omitted
Correct answer
C

76%
Answered correctly

01 sec
Time Spent

02/06/2020
Last Updated

Explanation

This patient developed fever, headache, myalgia, and a maculopapular rash while camping in the Appalachian Mountains, raising strong suspicion for **Rocky Mountain Spotted Fever** (RMSF). The causative pathogen is ***Rickettsia rickettsii***, a weakly gram-negative, obligate intracellular bacterium. Transmission occurs following a **tick bite** from specific tick vectors (eg, American dog tick) present in the eastern and south-central United States and mountainous regions west of the Mississippi River.

This patient developed fever, headache, myalgia, and a maculopapular rash while camping in the Appalachian Mountains, raising strong suspicion for **Rocky Mountain Spotted Fever** (RMSF). The causative pathogen is ***Rickettsia rickettsii***, a weakly gram-negative, obligate intracellular bacterium. Transmission occurs following a **tick bite** from specific tick vectors (eg, American dog tick) present in the eastern and south-central United States and mountainous regions west of the Mississippi River.

R rickettsii moves from the tick salivary glands to the human host after 6-12 hours of attachment. The pathogen enters vascular endothelial cells via endocytosis and subsequently lyses the endosome using specific virulence factors. It then replicates in the cytosol and nucleus of the host cell and spreads rapidly to adjacent cells via filopodia, leading to a lymphohistiocytic **vasculitis**.

Manifestations begin with fever, headache, myalgia, and malaise followed 3-5 days later by a characteristic macular **rash** that becomes petechial over time. The rash typically begins on the ankles or wrists and spreads toward the center of the body (**centripetally**) as well as to the palms and soles. **Thrombocytopenia** frequently occurs as platelets are consumed due to widespread vascular injury. Antibiotic therapy is required to prevent progression and, potentially, death. First-line therapy is **doxycycline**, which **inhibits protein synthesis** by binding the 30s bacterial ribosomal subunit.

(Choice A) Fluoroquinolones prevent DNA gyrase and topoisomerase from unwinding bacterial double-stranded circular DNA. Fluoroquinolones can be used to treat typhoid fever, a *Salmonella* infection that typically occurs in individuals who travel to developing nations. Symptoms include a step-wise fever, salmon-colored rose spots on the trunk, and intestinal bleeding/perforation.

(Choice B) Trimethoprim-sulfamethoxazole inhibits bacterial replication by blocking 2 successive steps in bacterial folate metabolism: Sulfamethoxazole competes with para-aminobenzoic acid in the synthesis of dihydrofolic acid, and trimethoprim inhibits dihydrofolate reductase.

(Choice D) Azole medications inhibit fungal ergosterol synthesis, which disrupts fungal cell membranes. Itraconazole can be used to treat pulmonary histoplasmosis, which usually causes subacute pneumonia with hilar or mediastinal lymphadenopathy.

(Choice E) Penicillin medications inhibit peptidoglycan cross-linking, which disrupts bacterial (spirochetal) cell membranes. Penicillin is the first-line therapy for syphilis, a spirochetal infection that can present with fever and a diffuse, symmetric maculopapular rash that involves the palms and soles (secondary syphilis). However, patients typically have a mild (not high) fever and diffuse lymphadenopathy.

(Choice F) Nucleotide and non-nucleoside reverse transcriptase inhibitors block viral reverse transcription. Although acute retroviral syndrome (early HIV infection) can present with a diffuse maculopapular rash and fever, patients also often have diffuse lymphadenopathy, a sore throat, and

prevent progression and, potentially, death. First-line therapy is **doxycycline**, which **inhibits protein synthesis** by binding the 30s bacterial ribosomal subunit.

(Choice A) Fluoroquinolones prevent DNA gyrase and topoisomerase from unwinding bacterial double-stranded circular DNA. Fluoroquinolones can be used to treat typhoid fever, a *Salmonella* infection that typically occurs in individuals who travel to developing nations. Symptoms include a step-wise fever, salmon-colored rose spots on the trunk, and intestinal bleeding/perforation.

(Choice B) Trimethoprim-sulfamethoxazole inhibits bacterial replication by blocking 2 successive steps in bacterial folate metabolism: Sulfamethoxazole competes with para-aminobenzoic acid in the synthesis of dihydrofolic acid, and trimethoprim inhibits dihydrofolate reductase.

(Choice D) Azole medications inhibit fungal ergosterol synthesis, which disrupts fungal cell membranes. Itraconazole can be used to treat pulmonary histoplasmosis, which usually causes subacute pneumonia with hilar or mediastinal lymphadenopathy.

(Choice E) Penicillin medications inhibit peptidoglycan cross-linking, which disrupts bacterial (spirochetal) cell membranes. Penicillin is the first-line therapy for syphilis, a spirochetal infection that can present with fever and a diffuse, symmetric maculopapular rash that involves the palms and soles (secondary syphilis). However, patients typically have a mild (not high) fever and diffuse lymphadenopathy.

(Choice F) Nucleotide and non-nucleoside reverse transcriptase inhibitors block viral reverse transcription. Although acute retroviral syndrome (early HIV infection) can present with a diffuse maculopapular rash and fever, patients also often have diffuse lymphadenopathy, a sore throat, and painful oral ulcers. In addition, RMSF is more likely in this case given this patient's recent camping trip.

Educational objective:
Rocky mountain spotted fever is a tick-borne illness due to *Rickettsia rickettsii*, a weakly gram-negative, obligate intracellular organism that has an affinity for vascular endothelial cells. Patients usually have nonspecific symptoms (eg, fever, malaise, myalgia) followed by a macular-petechial rash that begins on the ankles and wrists and spreads to the center of the body as well as to the palms and soles. Urgent treatment with doxycycline, an inhibitor of bacterial protein synthesis, is required.

Microbiology	Infectious Diseases	Rocky mountain spotted fever
Subject	System	Topic

Copyright © UWorld. All rights reserved.

prevent progression and, potentially, death. First-line therapy is **doxycycline**, which **inhibits protein synthesis** by binding the 30s bacterial

Exhibit Display

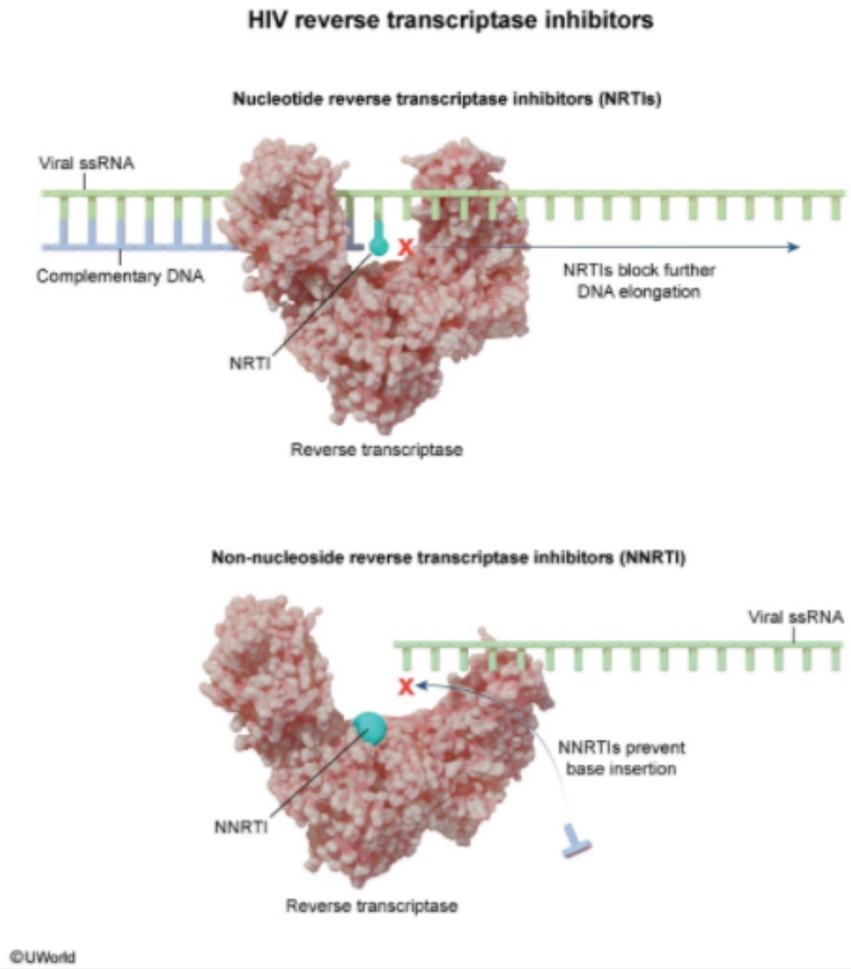

Zoom In | Zoom Out | Reset | Add To New Card | Existing Card

1
2
3
4
5
6
7
8
9
10
11
12
13
14
15
16
17
18
19
20
21
22
23
24
25
26
27
28
29
30
31

A previously healthy 2-year-old boy is brought to the clinic with fever and mouth pain that began yesterday. He has consumed an adequate amount of fluids but refuses to eat due to the pain. The patient has no medical problems and takes no medications. Physical examination reveals swollen gums and vesicular, inflamed lesions on his hard palate and lips. He has enlarged and tender cervical lymph nodes. Which of the following is most likely responsible for this patient's condition?

A. DNA virus, double-stranded, enveloped

B. DNA virus, double-stranded, non-enveloped

C. DNA virus, single-stranded, non-enveloped

D. RNA virus, double-stranded, positive-sense

E. RNA virus, single-stranded, negative-sense

F. RNA virus, single-stranded, positive-sense

Submit

A previously healthy 2-year-old boy is brought to the clinic with fever and mouth pain that began yesterday. He has consumed an adequate amount of fluids but refuses to eat due to the pain. The patient has no medical problems and takes no medications. Physical examination reveals swollen gums and vesicular, inflamed lesions on his hard palate and lips. He has enlarged and tender cervical lymph nodes. Which of the following is most likely responsible for this patient's condition?

- ✓ A. DNA virus, double-stranded, enveloped (56%)
- B. DNA virus, double-stranded, non-enveloped (12%)
- C. DNA virus, single-stranded, non-enveloped (5%)
- D. RNA virus, double-stranded, positive-sense (3%)
- E. RNA virus, single-stranded, negative-sense (9%)
- F. RNA virus, single-stranded, positive-sense (12%)

Omitted
Correct answer
A

56%
Answered correctly

02 secs
Time Spent

06/16/2020
Last Updated

Explanation

Double-stranded DNA viruses	
Enveloped	• Hepadna (eg, hepatitis B) • Herpes (eg, varicella, HSV-1 & HSV-2)

Double-stranded DNA viruses	
Enveloped	• Hepadna (eg, hepatitis B) • Herpes (eg, varicella, HSV-1 & HSV-2) • Pox (eg, smallpox)
Non-enveloped	• Adenovirus • Papova (eg, HPV) • Polyoma (eg, JC & BK)

HPV= human papillomavirus; **HSV**= herpes simplex virus.

©UWorld

Primary **herpes simplex virus type 1** (HSV-1) infection is characterized by the **gingivostomatitis** (vesicles on the lips and hard palate, fever, lymphadenopathy) seen in this young patient. Recurrent HSV-1 infection causes lip lesions that are typically less severe due to existing cellular and humoral immunity from prior infection.

HSV-1 and other herpesviruses are **enveloped** and possess **double-stranded DNA** genomes. Transmission is usually by direct contact with infected oral secretions or lesions. Inoculation occurs on mucosa or skin where the virus replicates rapidly in the host cell nucleus and causes abnormal cell division, resulting in intranuclear inclusion bodies and **multinucleated giant cells** visible on Tzanck smear. The vesicular lesions result from cell lysis and necrosis as well as tissue destruction, inflammation, and fluid accumulation between the dermis and epidermis.

(Choice B) Most DNA viruses are double-stranded. They are enveloped (ie, surrounded by a lipid layer) or non-enveloped (ie, lacking a surrounding lipid layer). Adenovirus is a non-enveloped, double-stranded DNA virus that typically causes self-limited upper respiratory infection or gastroenteritis.

(Choice C) Parvovirus is a single-stranded, non-enveloped DNA virus that causes erythema infectiosum, or fifth disease. Patients classically present with fever, cough, and rhinorrhea followed by a "slapped-cheek" and lacy, reticular truncal rash.

(Choice D) Rotavirus, a type of reovirus, is a double-stranded, positive-sense, non-enveloped RNA virus. Rotavirus infection is a vaccine-

©UWorld

Primary **herpes simplex virus type 1** (HSV-1) infection is characterized by the **gingivostomatitis** (vesicles on the lips and hard palate, fever, lymphadenopathy) seen in this young patient. Recurrent HSV-1 infection causes lip lesions that are typically less severe due to existing cellular and humoral immunity from prior infection.

HSV-1 and other herpesviruses are **enveloped** and possess **double-stranded DNA** genomes. Transmission is usually by direct contact with infected oral secretions or lesions. Inoculation occurs on mucosa or skin where the virus replicates rapidly in the host cell nucleus and causes abnormal cell division, resulting in intranuclear inclusion bodies and **multinucleated giant cells** visible on Tzanck smear. The vesicular lesions result from cell lysis and necrosis as well as tissue destruction, inflammation, and fluid accumulation between the dermis and epidermis.

(Choice B) Most DNA viruses are double-stranded. They are enveloped (ie, surrounded by a lipid layer) or non-enveloped (ie, lacking a surrounding lipid layer). Adenovirus is a non-enveloped, double-stranded DNA virus that typically causes self-limited upper respiratory infection or gastroenteritis.

(Choice C) Parvovirus is a single-stranded, non-enveloped DNA virus that causes erythema infectiosum, or fifth disease. Patients classically present with fever, cough, and rhinorrhea followed by a "slapped-cheek" and lacy, reticular truncal rash.

(Choice D) Rotavirus, a type of reovirus, is a double-stranded, positive-sense, non-enveloped RNA virus. Rotavirus infection is a vaccine-preventable disease characterized by profuse, watery diarrhea in children.

(Choices E and F) Most RNA viruses are single-stranded and can be classified as negative- or positive-sense viruses. Positive-sense viruses can be directly translated into proteins, but negative-sense stranded viruses must first have their RNA converted into positive-sense strands before translation. Coxsackievirus, a single-stranded, positive-sense RNA virus of the enterovirus family, causes hand, foot, and mouth disease, which presents with vesicular lesions on the buccal mucosa, tongue, and soft palate. The gums and hard palate are usually involved in HSV gingivostomatitis, not hand-foot-mouth disease.

Educational objective:
Primary herpes simplex virus type 1 (HSV-1) infection in children causes gingivostomatitis (vesicular lesions on the lips and hard palate). HSV-1 and other herpesviruses are double-stranded, enveloped DNA viruses.

References

- The RNA synthesis machinery of negative-stranded RNA viruses

©UWorld

Exhibit Display

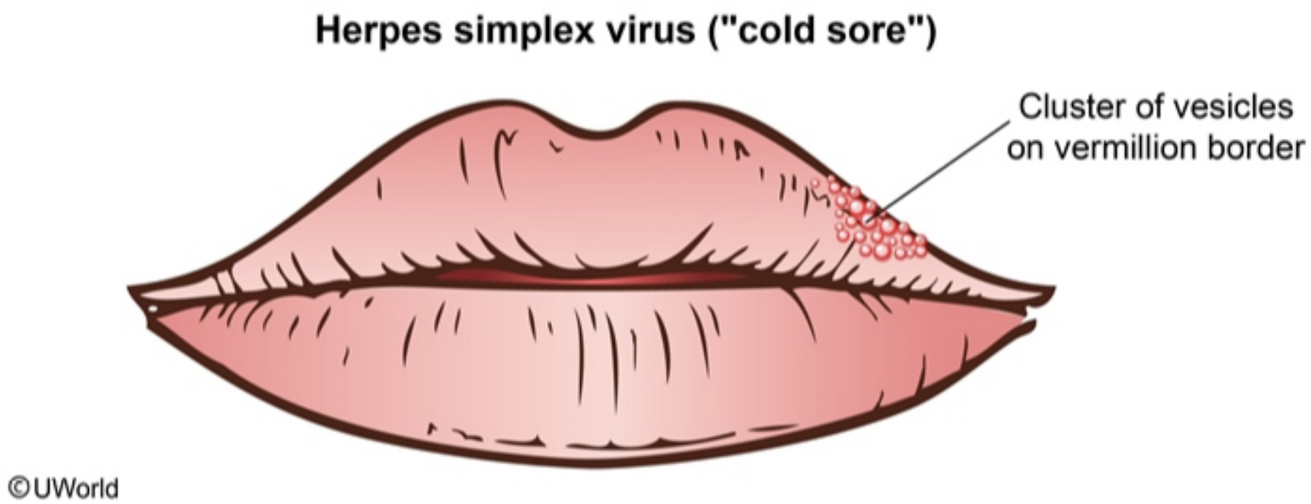

Zoom In | Zoom Out | Reset | Add To New Card | Existing Card

- The RNA synthesis machinery of negative-stranded RNA viruses

result from cell lysis and necrosis as well as tissue destruction, inflammation, and fluid accumulation between the dermis and epidermis.

(Choice B) Most DNA viruses are double-stranded. They are enveloped (ie, surrounded by a lipid layer) or non-enveloped (ie, lacking a surrounding lipid layer). Adenovirus is a non-enveloped, double-stranded DNA virus that typically causes self-limited upper respiratory infection or gastroenteritis.

(Choice C) Parvovirus is a single-stranded, non-enveloped DNA virus that causes erythema infectiosum, or fifth disease. Patients classically present with fever, cough, and rhinorrhea followed by a "slapped-cheek" and lacy, reticular truncal rash.

(Choice D) Rotavirus, a type of reovirus, is a double-stranded, positive-sense, non-enveloped RNA virus. Rotavirus infection is a vaccine-preventable disease characterized by profuse, watery diarrhea in children.

(Choices E and F) Most RNA viruses are single-stranded and can be classified as negative- or positive-sense viruses. Positive-sense viruses can be directly translated into proteins, but negative-sense stranded viruses must first have their RNA converted into positive-sense strands before translation. Coxsackievirus, a single-stranded, positive-sense RNA virus of the enterovirus family, causes hand, foot, and mouth disease, which presents with vesicular lesions on the buccal mucosa, tongue, and soft palate. The gums and hard palate are usually involved in HSV gingivostomatitis, not hand-foot-mouth disease.

Educational objective:
Primary herpes simplex virus type 1 (HSV-1) infection in children causes gingivostomatitis (vesicular lesions on the lips and hard palate). HSV-1 and other herpesviruses are double-stranded, enveloped DNA viruses.

References

- The RNA synthesis machinery of negative-stranded RNA viruses.
- Ultrastructure of the replication site of positive-stranded RNA viruses.

Microbiology	Infectious Diseases	HSV infection
Subject	System	Topic

Copyright © UWorld. All rights reserved.

result from cell lysis and necrosis as well as tissue destruction, inflammation, and fluid accumulation between the dermis and epidermis.

Exhibit Display

Single-stranded RNA viruses	
Negative-sense	• Arena (eg, Lassa) • Bunya (eg, hantavirus) • Delta (eg, hepatitis D) • Filo (eg, Ebola, Marburg) • Orthomyxo (eg, influenza) • Paramyxo (eg, RSV, mumps, measles) • Rhabdo (eg, rabies)
Positive-sense	• Calici (eg, norovirus) • Corona (eg, SARS) • Flavi (eg, West Nile, hepatitis C, dengue, yellow fever) • Hepe (eg, hepatitis E virus) • Picorna (eg, hepatitis A, enteroviruses) • Retro (eg, HIV) • Toga (eg, rubella)

RSV= respiratory syncytial virus; **SARS**= severe acute respiratory syndrome.

©UWorld

Zoom In Zoom Out Reset Add To New Card | Existing Card

result from cell lysis and necrosis as well as tissue destruction, inflammation, and fluid accumulation between the dermis and epidermis.

Exhibit Display

Hand foot and mouth disease Hand foot and mouth

Zoom In Zoom Out Reset Add To New Card | Existing Card

1
2
3
4
5
6
7
8
9
10
11
12
13
14
15
16
17
18
19
20
21
22
23
24
25
26
27
28
29
30
31

result from cell lysis and necrosis as well as tissue destruction, inflammation, and fluid accumulation between the dermis and epidermis.

Exhibit Display

Hand foot and mouth disease Hand foot and mouth

Zoom In Zoom Out Reset Add To New Card | Existing Card

An 83-year-old woman is brought to the emergency department from a nursing home with fever and altered mental status. The patient has a history of hypertension, dementia, and fecal incontinence. Her temperature is 38.3 C (100.9 F), blood pressure is 100/68 mm Hg, and pulse is 114/min. She is lethargic and unable to answer questions. Her abdomen is soft, with suprapubic tenderness. Lungs are clear bilaterally. There is no cardiac murmur or skin rash. Laboratory results are as follows:

Blood	
Leukocytes	17,000/mm^3
Potassium	3.8 mEq/L
Bicarbonate	22 mEq/L
Creatinine	0.8 mg/dL
Urinalysis	
Leukocyte esterase	positive
Nitrites	positive
Leukocytes	10/hpf

A chest x-ray reveals normal-appearing lungs. Blood and urine cultures are performed, and empiric antibiotics are initiated. Urine cultures grow gram-negative rods that are lactose-fermenting and indole-positive. Which of the following is the most likely organism causing this patient's infection?

- A. *Enterobacter cloacae*
- B. *Escherichia coli*
- C. *Haemophilus influenzae*

1 2 3 4 5 6 7 8 9 10 11 12 13 14 15 16 17 18 19 20 21 22 23 24 25 26 27 28 29 30 31

Leukocytes	17,000/mm^3
Potassium	3.8 mEq/L
Bicarbonate	22 mEq/L
Creatinine	0.8 mg/dL

Urinalysis

Leukocyte esterase	positive
Nitrites	positive
Leukocytes	10/hpf

A chest x-ray reveals normal-appearing lungs. Blood and urine cultures are performed, and empiric antibiotics are initiated. Urine cultures grow gram-negative rods that are lactose-fermenting and indole-positive. Which of the following is the most likely organism causing this patient's infection?

A. *Enterobacter cloacae*
B. *Escherichia coli*
C. *Haemophilus influenzae*
D. *Proteus mirabilis*
E. *Pseudomonas aeruginosa*

Submit

1 2 3 4 5 6 7 8 9 10 11 12 13 14 15 16 17 18 19 20 21 22 23 24 25 26 27 28 29 30 31

Leukocytes	17,000/mm^3
Potassium	3.8 mEq/L
Bicarbonate	22 mEq/L
Creatinine	0.8 mg/dL
Urinalysis	
Leukocyte esterase	positive
Nitrites	positive
Leukocytes	10/hpf

A chest x-ray reveals normal-appearing lungs. Blood and urine cultures are performed, and empiric antibiotics are initiated. Urine cultures grow gram-negative rods that are lactose-fermenting and indole-positive. Which of the following is the most likely organism causing this patient's infection?

A. *Enterobacter cloacae* (6%)
✓ B. *Escherichia coli* (83%)
C. *Haemophilus influenzae* (0%)
D. *Proteus mirabilis* (6%)
E. *Pseudomonas aeruginosa* (2%)

Omitted
Correct answer

83%
Answered correctly

06 secs
Time Spent

04/29/2020
Last Updated

1
2
3
4
5
6
7
8
9
10
11
12
13
14
15
16
17
18
19
20
21
22
23
24
25
26
27
28
29
30
31

Characteristics of gram-negative bacteria

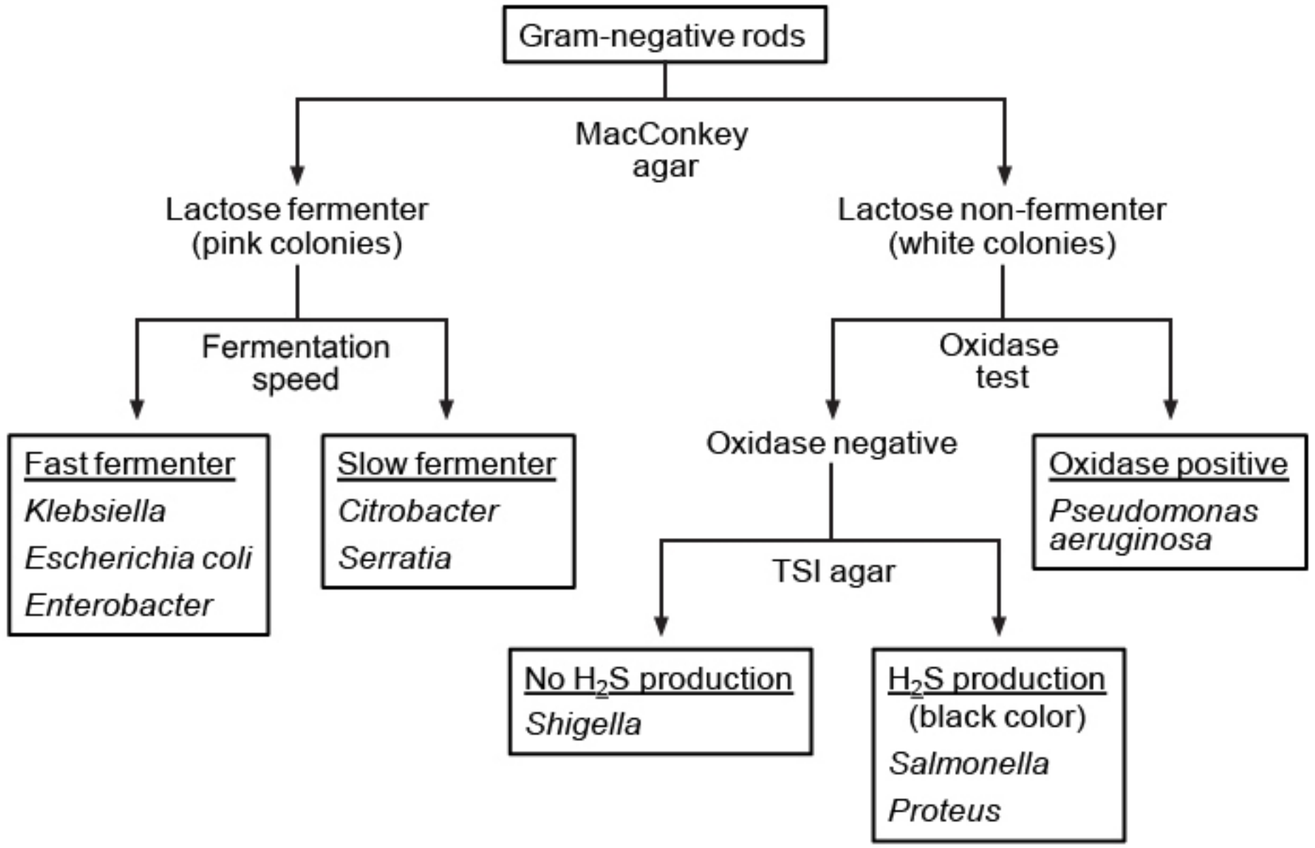

©UWorld

This patient has sepsis, most likely due to a **urinary tract infection** (UTI), as evidenced by the presence of pyuria (leukocytes), leukocyte esterase, and gram-negative rods in the urine. Among the organisms listed, the microbiological features - **lactose-fermenting, indole-positive gram-negative rods** - are characteristic of ***Escherichia coli***, the most common etiology of UTIs among elderly women. The indole positivity (ability to convert tryptophan to indole) of *E coli* distinguishes it from *Enterobacter cloacae*, another lactose-fermenting gram-negative rod that is a common cause of UTIs in women **(Choice A).** Both *E coli* and *E cloacae* are fast lactose fermenters.

1
2
3
4
5
6
7
8
9
10
11
12
13
14
15
16
17
18
19
20
21
22
23
24
25
26
27
28
29
30
31

Shigella

(black color)
Salmonella
Proteus

©UWorld

This patient has sepsis, most likely due to a **urinary tract infection** (UTI), as evidenced by the presence of pyuria (leukocytes), leukocyte esterase, and gram-negative rods in the urine. Among the organisms listed, the microbiological features - **lactose-fermenting, indole-positive gram-negative rods** - are characteristic of ***Escherichia coli***, the most common etiology of UTIs among elderly women. The indole positivity (ability to convert tryptophan to indole) of *E coli* distinguishes it from *Enterobacter cloacae*, another lactose-fermenting gram-negative rod that is a common cause of UTIs in women **(Choice A).** Both *E coli* and *E cloacae* are fast lactose fermenters.

(Choice C) *Haemophilus influenzae* are gram-negative organisms that colonize the respiratory tract rather than the gastrointestinal and genitourinary tracts; they do not typically cause UTIs. These organisms are frequent causes of pneumonia, sinusitis, and, less commonly, meningitis.

(Choices D and E) *Proteus mirabilis* and *Pseudomonas aeruginosa* are gram-negative organisms that can cause UTI, most commonly in patients with Foley catheters. However, in contrast to *E coli*, these organisms are lactose non-fermenters (do not form pink colonies on MacConkey agar).

Educational objective:
Escherichia coli are lactose-fermenting, indole-positive gram-negative rods that are an important cause of urinary tract infection in women.

References

- Epidemiology of urinary tract infection: transmission and risk factors, incidence, and costs.
- Urinary tract infections in older women: a clinical review.

Microbiology	Infectious Diseases	Urinary tract infection
Subject	System	Topic

Copyright © UWorld. All rights reserved.

1
2
3
4
5
6
7
8
9
10
11
12
13
14
15
16
17
18
19
20
21
22
23
24
25
26
27
28
29
30
31

Researchers studying fungal pathogens isolated an ergosterol biosynthetic gene by polymerase chain reaction. Using homologous recombination, they then developed a new strain of *Candida* with a mutated allele for that gene. The mutant strain was cultured in the presence of several different antifungal agents. Compared to isolates from the wild-type strain, isolates from the mutant *Candida* strain exhibited enhanced growth in the presence of drug X. Further investigation revealed that the mechanism of resistance to drug X was a decrease in ergosterol incorporation into the cell membrane. Based on this data, drug X is likely to be most closely related to which of the following antifungal agents?

A. Caspofungin
B. Cyclosporine
C. Flucytosine
D. Griseofulvin
E. Nystatin

Submit

1
2
3
4
5
6
7
8
9
10
11
12
13
14
15
16
17
18
19
20
21
22
23
24
25
26
27
28
29
30
31

Researchers studying fungal pathogens isolated an ergosterol biosynthetic gene by polymerase chain reaction. Using homologous recombination, they then developed a new strain of *Candida* with a mutated allele for that gene. The mutant strain was cultured in the presence of several different antifungal agents. Compared to isolates from the wild-type strain, isolates from the mutant *Candida* strain exhibited enhanced growth in the presence of drug X. Further investigation revealed that the mechanism of resistance to drug X was a decrease in ergosterol incorporation into the cell membrane. Based on this data, drug X is likely to be most closely related to which of the following antifungal agents?

A. Caspofungin (22%)
B. Cyclosporine (2%)
C. Flucytosine (8%)
D. Griseofulvin (9%)
✓ E. Nystatin (57%)

Omitted
Correct answer
E

57%
Answered correctly

02 secs
Time Spent

05/18/2020
Last Updated

Explanation

1
2
3
4
5
6
7
8
9
10
11
12
13
14
15
16
17
18
19
20
21
22
23
24
25
26
27
28
29
30
31

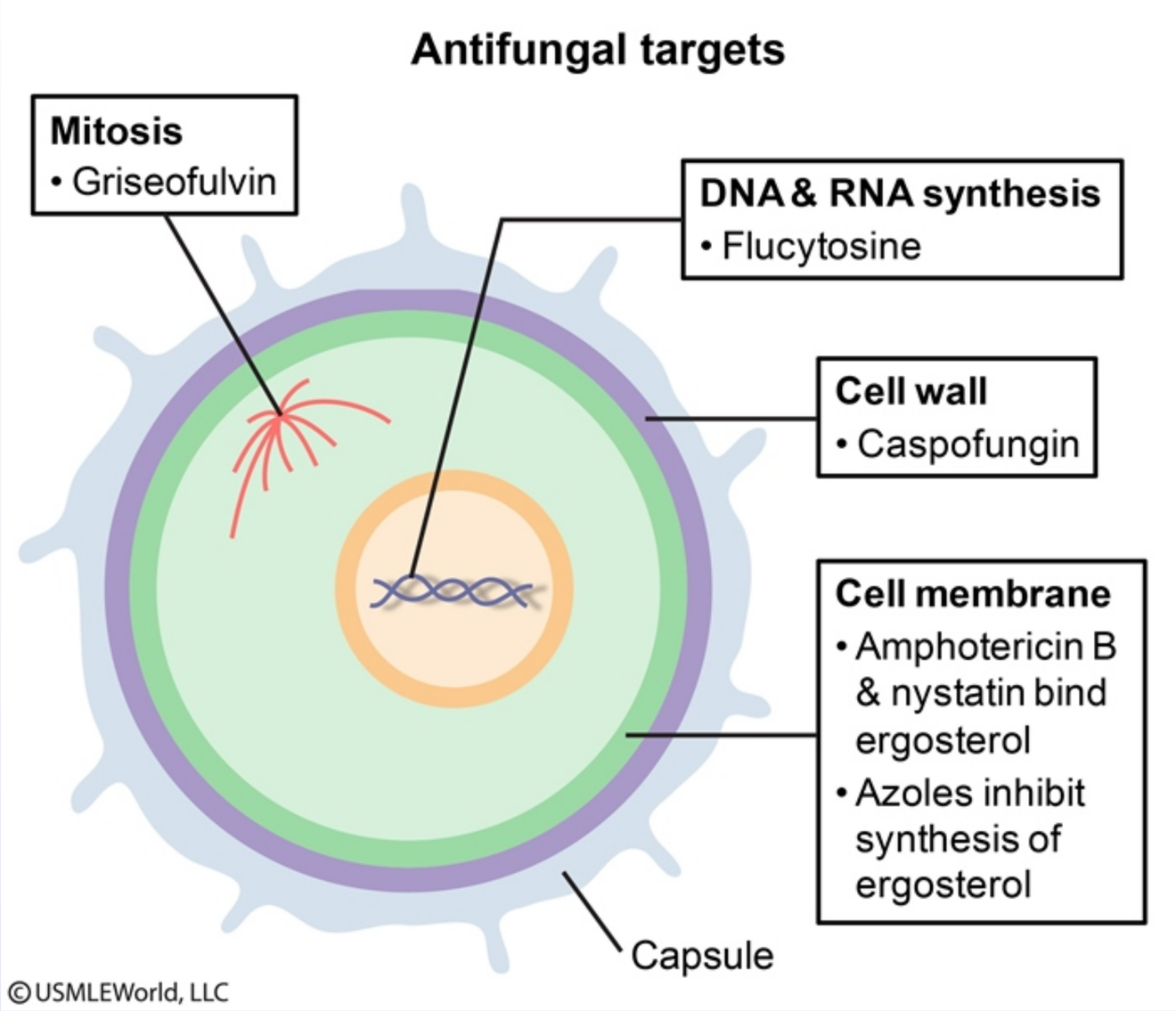

The main classes of antifungal medications currently in use include:

The main classes of antifungal medications currently in use include:

1. **Polyenes** (eg, amphotericin B, nystatin): Bind to ergosterol molecules in fungal cell membranes, creating pores and causing cell lysis
2. **Triazoles** (eg, ketoconazole, fluconazole, itraconazole, voriconazole): Inhibit the synthesis of ergosterol
3. **Echinocandins** (eg, caspofungin, micafungin): Inhibit the synthesis of glucan, a component of the fungal cell wall
4. **Pyrimidines**: Flucytosine, the only agent in this class of antifungals, is converted to 5-fluorouracil within the fungal cell and interferes with fungal RNA and protein synthesis.

Of these agents, only the polyenes (amphotericin B, nystatin) depend on the amount of **ergosterol** incorporated into fungal cell membranes for their efficacy. These drugs bind to ergosterol molecules, forming **pores** in the membrane and allowing leakage of ions (especially K^+) from the cells. This disruption of cell membrane integrity leads to cell lysis. An organism that decreases the amount of ergosterol in its cell membrane would likely become resistant to polyenes. **Amphotericin** B is a systemic antifungal active against *Candida, Aspergillus, Cryptococcus, Histoplasma, Blastomyces*, and *Coccidioides*. **Nystatin** is used topically; oral candidiasis is the main indication for its use ("swish and swallow").

(Choice A) Caspofungin is an antifungal agent that blocks synthesis of the glucan component of the fungal cell wall. It is active against *Candida* and *Aspergillus*. Caspofungin does not bind ergosterol.

(Choice B) Cyclosporine is an immunosuppressant used in transplant recipients to prevent rejection. It decreases the synthesis of IL-2, thereby inhibiting T cell proliferation.

(Choice C) Flucytosine is used in combination with amphotericin B primarily for the treatment of cryptococcal meningitis in patients with HIV. It is a nucleotide analog that competitively inhibits RNA synthesis in fungal cells.

(Choice D) Griseofulvin interacts with fungal cell microtubules, inhibiting mitosis. It accumulates in keratin-containing tissues and is used to treat dermatophyte infections (eg, *Microsporum, Epidermophyton, Trichophyton*).

Educational objective:
The main groups of antifungal drugs are polyenes, azoles, echinocandins, and pyrimidines. Polyene antifungals (eg, amphotericin B, nystatin) act by binding ergosterol in the fungal cell membrane.

Microbiology Infectious Diseases Antibiotic resistance

1 2 3 4 5 6 7 8 9 10 11 12 13 14 15 16 17 18 19 20 21 22 23 24 25 26 27 28 29 30 31

2. **Triazoles** (eg, ketoconazole, fluconazole, itraconazole, voriconazole): Inhibit the synthesis of ergosterol
3. **Echinocandins** (eg, caspofungin, micafungin): Inhibit the synthesis of glucan, a component of the fungal cell wall
4. **Pyrimidines**: Flucytosine, the only agent in this class of antifungals, is converted to 5-fluorouracil within the fungal cell and interferes with fungal RNA and protein synthesis.

Of these agents, only the polyenes (amphotericin B, nystatin) depend on the amount of **ergosterol** incorporated into fungal cell membranes for their efficacy. These drugs bind to ergosterol molecules, forming **pores** in the membrane and allowing leakage of ions (especially K^+) from the cells. This disruption of cell membrane integrity leads to cell lysis. An organism that decreases the amount of ergosterol in its cell membrane would likely become resistant to polyenes. **Amphotericin** B is a systemic antifungal active against *Candida, Aspergillus, Cryptococcus, Histoplasma, Blastomyces*, and *Coccidioides*. **Nystatin** is used topically; oral candidiasis is the main indication for its use ("swish and swallow").

(Choice A) Caspofungin is an antifungal agent that blocks synthesis of the glucan component of the fungal cell wall. It is active against *Candida* and *Aspergillus*. Caspofungin does not bind ergosterol.

(Choice B) Cyclosporine is an immunosuppressant used in transplant recipients to prevent rejection. It decreases the synthesis of IL-2, thereby inhibiting T cell proliferation.

(Choice C) Flucytosine is used in combination with amphotericin B primarily for the treatment of cryptococcal meningitis in patients with HIV. It is a nucleotide analog that competitively inhibits RNA synthesis in fungal cells.

(Choice D) Griseofulvin interacts with fungal cell microtubules, inhibiting mitosis. It accumulates in keratin-containing tissues and is used to treat dermatophyte infections (eg, *Microsporum, Epidermophyton, Trichophyton*).

Educational objective:
The main groups of antifungal drugs are polyenes, azoles, echinocandins, and pyrimidines. Polyene antifungals (eg, amphotericin B, nystatin) act by binding ergosterol in the fungal cell membrane.

Microbiology	Infectious Diseases	Antibiotic resistance
Subject	System	Topic

Copyright © UWorld. All rights reserved.

1
2
3
4
5
6
7
8
9
10
11
12
13
14
15
16
17
18
19
20
21
22
23
24
25
26
27
28
29
30
31

A 24-year-old woman, gravida 1 para 0, at 26 weeks gestation comes to the emergency department due to abdominal cramping and vaginal bleeding. She recently emigrated from Bolivia and reports no prior medical problems. The patient's only medication is a daily multivitamin. Immunization status is unknown. The patient spontaneously delivers a stillborn fetus with multiple congenital malformations. Fetal autopsy reveals microcephaly with thin cerebral cortices, ventriculomegaly, and subcortical calcifications. Viral RNA of a neurotropic virus is detected in body fluids of the mother and the fetus. Transplacental transmission of this virus causes apoptosis of neural progenitor cells in the developing fetus, leading to disruption of neuronal proliferation, migration, and differentiation. Which of the following viruses most likely caused this patient's in utero infection?

A. Cytomegalovirus
B. Herpes simplex virus
C. Parvovirus B19
D. Rubella virus
E. Varicella zoster virus
F. Zika virus

Submit

1
2
3
4
5
6
7
8
9
10
11
12
13
14
15
16
17
18
19
20
21
22
23
24
25
26
27
28
29
30
31

A 24-year-old woman, gravida 1 para 0, at 26 weeks gestation comes to the emergency department due to abdominal cramping and vaginal bleeding. She recently emigrated from Bolivia and reports no prior medical problems. The patient's only medication is a daily multivitamin. Immunization status is unknown. The patient spontaneously delivers a stillborn fetus with multiple congenital malformations. Fetal autopsy reveals microcephaly with thin cerebral cortices, ventriculomegaly, and subcortical calcifications. Viral RNA of a neurotropic virus is detected in body fluids of the mother and the fetus. Transplacental transmission of this virus causes apoptosis of neural progenitor cells in the developing fetus, leading to disruption of neuronal proliferation, migration, and differentiation. Which of the following viruses most likely caused this patient's in utero infection?

A. Cytomegalovirus (25%)
B. Herpes simplex virus (1%)
C. Parvovirus B19 (4%)
D. Rubella virus (13%)
E. Varicella zoster virus (1%)
✓ F. Zika virus (53%)

Omitted
Correct answer
F

53%
Answered correctly

02 secs
Time Spent

04/28/2020
Last Updated

Explanation

Congenital Zika syndrome

Congenital Zika syndrome	
Pathogenesis	• Single-stranded RNA *Flavivirus* • Transplacental transmission to fetus • Targets neural progenitor cells
Clinical features	• Microcephaly, craniofacial disproportion • Neurologic abnormalities (eg, spasticity, seizures) • Ocular abnormalities
Diagnosis	• Neuroimaging: Calcifications, ventriculomegaly, cortical thinning • Zika RNA detection

Zika virus is a **single-stranded RNA** virus belonging to the *Flavivirus* genus. Transmission occurs primarily via an *Aedes* mosquito bite, but infected patients can also spread the virus via genital secretions. The neurotropic virus can cross the placenta and infect and destroy **fetal neural progenitor cells**, causing congenital Zika syndrome and possible fetal demise. Fetal brain development is impaired due to disruption of normal proliferation, migration, and differentiation of neurons.

Classic findings in affected newborns include **microcephaly** with facial features out of proportion to head size, **arthrogryposis** (contractures), seizures, hypertonia, and ocular abnormalities. Loss of brain mass (eg, **cortical thinning**, ventriculomegaly) as well as subcortical calcifications are typically present. Diagnosis is confirmed by detection of Zika RNA (real-time reverse transcriptase PCR) in serum, urine, or cerebrospinal fluid.

The mainstay of treatment for surviving infants is supportive care with management of feeding difficulties, hydrocephalus, and seizures. Pregnant women should be counseled to avoid traveling to areas with ongoing Zika transmission (eg, South and Central America, Asia, Africa, Mexico, the Caribbean).

(Choices A, B, and E) Cytomegalovirus (CMV), herpes simplex virus (HSV), and varicella zoster virus (VZV) are double-stranded DNA viruses that can be transmitted in utero and cause CNS abnormalities in the fetus. Typical CMV findings include hearing loss, chorioretinitis, jaundice, and periventricular calcifications. When transmitted in utero, HSV and VZV can cause diffuse cutaneous lesions and severe brain destruction; hypoplasia of the limbs and eyes is also commonly seen with fetal VZV infection.

- Zika RNA detection

Zika virus is a **single-stranded RNA** virus belonging to the *Flavivirus* genus. Transmission occurs primarily via an *Aedes* mosquito bite, but infected patients can also spread the virus via genital secretions. The neurotropic virus can cross the placenta and infect and destroy **fetal neural progenitor cells**, causing congenital Zika syndrome and possible fetal demise. Fetal brain development is impaired due to disruption of normal proliferation, migration, and differentiation of neurons.

Classic findings in affected newborns include **microcephaly** with facial features out of proportion to head size, **arthrogryposis** (contractures), seizures, hypertonia, and ocular abnormalities. Loss of brain mass (eg, **cortical thinning**, ventriculomegaly) as well as subcortical calcifications are typically present. Diagnosis is confirmed by detection of Zika RNA (real-time reverse transcriptase PCR) in serum, urine, or cerebrospinal fluid.

The mainstay of treatment for surviving infants is supportive care with management of feeding difficulties, hydrocephalus, and seizures. Pregnant women should be counseled to avoid traveling to areas with ongoing Zika transmission (eg, South and Central America, Asia, Africa, Mexico, the Caribbean).

(Choices A, B, and E) Cytomegalovirus (CMV), herpes simplex virus (HSV), and varicella zoster virus (VZV) are double-stranded DNA viruses that can be transmitted in utero and cause CNS abnormalities in the fetus. Typical CMV findings include hearing loss, chorioretinitis, jaundice, and periventricular calcifications. When transmitted in utero, HSV and VZV can cause diffuse cutaneous lesions and severe brain destruction; hypoplasia of the limbs and eyes is also commonly seen with fetal VZV infection.

(Choice C) Parvovirus B19 is a single-stranded DNA virus that infects and destroys erythroid progenitor cells and can result in fetal hydrops when the infection is contracted during pregnancy.

(Choice D) Rubella virus is a single-stranded RNA virus that typically presents with cardiac defects, hearing loss, and cataracts.

Educational objective:
Zika virus is a single-stranded RNA virus that infects fetal neural progenitor cells, causing severe congenital malformations (eg, microcephaly, arthrogryposis), cerebral cortical thinning, and possible fetal demise.

References

- Congenital Zika virus infection: beyond neonatal microcephaly.

1 2 3 4 5 6 7 8 9 10 11 12 13 14 15 16 17 18 19 20 21 22 23 24 25 26 27 28 29 30 31

seizures, hypertonia, and ocular abnormalities. Loss of brain mass (eg, **cortical thinning**, ventriculomegaly) as well as subcortical calcifications are typically present. Diagnosis is confirmed by detection of Zika RNA (real-time reverse transcriptase PCR) in serum, urine, or cerebrospinal fluid.

The mainstay of treatment for surviving infants is supportive care with management of feeding difficulties, hydrocephalus, and seizures. Pregnant women should be counseled to avoid traveling to areas with ongoing Zika transmission (eg, South and Central America, Asia, Africa, Mexico, the Caribbean).

(Choices A, B, and E) Cytomegalovirus (CMV), herpes simplex virus (HSV), and varicella zoster virus (VZV) are double-stranded DNA viruses that can be transmitted in utero and cause CNS abnormalities in the fetus. Typical CMV findings include hearing loss, chorioretinitis, jaundice, and periventricular calcifications. When transmitted in utero, HSV and VZV can cause diffuse cutaneous lesions and severe brain destruction; hypoplasia of the limbs and eyes is also commonly seen with fetal VZV infection.

(Choice C) Parvovirus B19 is a single-stranded DNA virus that infects and destroys erythroid progenitor cells and can result in fetal hydrops when the infection is contracted during pregnancy.

(Choice D) Rubella virus is a single-stranded RNA virus that typically presents with cardiac defects, hearing loss, and cataracts.

Educational objective:
Zika virus is a single-stranded RNA virus that infects fetal neural progenitor cells, causing severe congenital malformations (eg, microcephaly, arthrogryposis), cerebral cortical thinning, and possible fetal demise.

References

- Congenital Zika virus infection: beyond neonatal microcephaly.
- Zika virus infection.

Microbiology	Infectious Diseases	Zika virus
Subject	System	Topic

Copyright © UWorld. All rights reserved.

1
2
3
4
5
6
7
8
9
10
11
12
13
14
15
16
17
18
19
20
21
22
23
24
25
26
27
28
29
30
31

A 35-year-old man comes to the office due to 3 months of progressive swelling under his left jaw. The swelling spontaneously opened and drained pus a month ago but has not improved or resolved. The patient has no medical conditions other than dental caries; he had a tooth extracted prior to symptom onset. Physical examination shows an indurated, nontender mass in the left submandibular area with a small opening on the overlying skin. Gentle pressure on the mass yields thick pus containing sand/grain-like particles. The microbial pathogen with which of the following characteristics is the most likely cause of this patient's condition?

A. Bipolar-staining, gram-negative bacilli

B. Coagulase-producing, gram-positive cocci

C. Conidia-forming, dimorphic fungus

D. Filamentous, branching, gram-positive bacilli

E. Oxidase-positive, gram-negative bacilli

Submit

A 35-year-old man comes to the office due to 3 months of progressive swelling under his left jaw. The swelling spontaneously opened and drained pus a month ago but has not improved or resolved. The patient has no medical conditions other than dental caries; he had a tooth extracted prior to symptom onset. Physical examination shows an indurated, nontender mass in the left submandibular area with a small opening on the overlying skin. Gentle pressure on the mass yields thick pus containing sand/grain-like particles. The microbial pathogen with which of the following characteristics is the most likely cause of this patient's condition?

- A. Bipolar-staining, gram-negative bacilli (1%)
- B. Coagulase-producing, gram-positive cocci (14%)
- C. Conidia-forming, dimorphic fungus (1%)
- ✓ D. Filamentous, branching, gram-positive bacilli (77%)
- E. Oxidase-positive, gram-negative bacilli (3%)

Omitted
Correct answer
D

77%
Answered correctly

02 secs
Time Spent

04/10/2020
Last Updated

Explanation

Cervicofacial *Actinomyces*	
Organism	• Gram-positive facultative/strict anaerobe • Branching & **filamentous growth** • Normal GI commensal

Cervicofacial *Actinomyces*	
Organism	• Gram-positive facultative/strict anaerobe • Branching & **filamentous growth** • Normal GI commensal
Pathophysiology	• Inoculated into submucosa (dental infection/**extraction**) → low oxygen tension → growth without regard to tissue planes
Manifestations	• Upper/lower jaw (**mandible)** • **Slowly progressive**, **nonpainful**, indurated mass • Sinus tracts with **sulfur granules** • Fever/lymphadenopathy are uncommon

GI = gastrointestinal.

Actinomyces are anaerobic, **gram-positive bacilli** that have a branching, filamentous growth pattern similar to the mycelial form of fungi (hence their "fungus-like" name). They exist as normal commensals of the human gastrointestinal tract and rarely cause illness. However, introduction of the bacteria into the submucosa during a mechanical trauma (eg, **tooth extraction**) can sometimes lead to invasive disease, particularly when the wound is associated with low oxygen tension (ie, due to necrosis or infection).

Infections with *Actinomyces* most commonly involve the **cervicofacial** region. The bacteria grow slowly and without regard to tissue planes, resulting in a chronic, nontender, **indurated perimandibular mass** that enlarges over time and evolves into multiple abscesses and **draining sinus tracts**. A characteristic finding is the presence of **sulfur granules**, yellow-orange granules in pus that resemble (but do not contain) sulfur. Sulfur granules are intertwined *Actinomyces* filaments mixed with necrotic tissue.

(Choice A) *Pasteurella multocida* is a gram-negative rod that exhibits bipolar staining (ends of bacilli stain more than the middle). This organism causes a rapidly progressive soft tissue infection following an animal (usually a cat) bite. Although *Pasteurella* infection may cause draining cutaneous sinus tracts, infections are acute and not associated with tooth extraction or sulfur granules.

(Choice B) *Staphylococcus aureus* is the leading cause of acute suppurative parotitis, which is associated with firm, erythematous swelling in the

Actinomyces are anaerobic, **gram-positive bacilli** that have a branching, filamentous growth pattern similar to the mycelial form of fungi (hence their "fungus-like" name). They exist as normal commensals of the human gastrointestinal tract and rarely cause illness. However, introduction of the bacteria into the submucosa during a mechanical trauma (eg, **tooth extraction**) can sometimes lead to invasive disease, particularly when the wound is associated with low oxygen tension (ie, due to necrosis or infection).

Infections with *Actinomyces* most commonly involve the **cervicofacial** region. The bacteria grow slowly and without regard to tissue planes, resulting in a chronic, nontender, **indurated perimandibular mass** that enlarges over time and evolves into multiple abscesses and **draining sinus tracts**. A characteristic finding is the presence of **sulfur granules**, yellow-orange granules in pus that resemble (but do not contain) sulfur. Sulfur granules are intertwined *Actinomyces* filaments mixed with necrotic tissue.

(Choice A) *Pasteurella multocida* is a gram-negative rod that exhibits bipolar staining (ends of bacilli stain more than the middle). This organism causes a rapidly progressive soft tissue infection following an animal (usually a cat) bite. Although *Pasteurella* infection may cause draining cutaneous sinus tracts, infections are acute and not associated with tooth extraction or sulfur granules.

(Choice B) *Staphylococcus aureus* is the leading cause of acute suppurative parotitis, which is associated with firm, erythematous swelling in the area of the mandibular angle. However, *S aureus* soft tissue abscesses progress rapidly and are painful and tender.

(Choice C) *Sporothrix schenckii* is a conidia-forming, dimorphic fungus that causes cutaneous sporotrichosis when contaminated soil is inoculated into skin or soft tissue. Manifestations include an ulcerating papule at the site of inoculation with proximal spread along the lymphatics leading to additional lesions.

(Choice E) *Pseudomonas* is an oxidase-positive, gram-negative bacillus that can produce a green pigment. Cutaneous *Pseudomonas* infections are most common after hot tub use and are usually associated with acute folliculitis (tender, pruritic papules or nodules).

Educational objective:
Actinomyces species are gram-positive, branching, filamentous bacteria that may cause cervicofacial infections when introduced to the submucosa during mechanical trauma (eg, tooth extraction). Manifestations include a slowly enlarging, nonpainful, chronic mandibular mass that evolves into multiple abscesses and sinus tracts draining yellow-orange sulfur granules.

Microbiology	Infectious Diseases	Actinomycosis
Subject	System	Topic

- Inoculated into submucosa (dental infection/**extraction**) → low oxygen tension → growth without regard to tissue

Exhibit Display

Actinomyces species

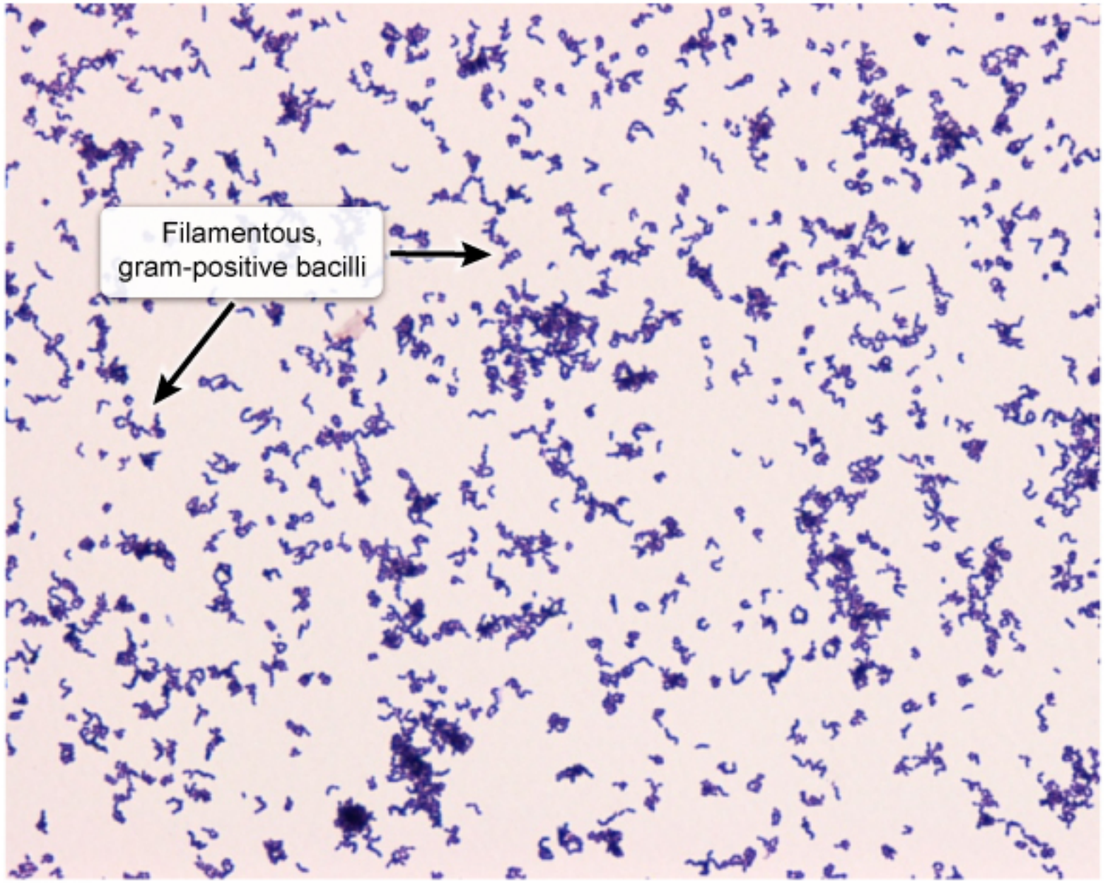

©UWorld

Zoom In | Zoom Out | Reset | Add To New Card | Existing Card

(Choice E) *Pseudomonas* is an oxidase-positive, gram-negative bacillus that can produce a green pigment. Cutaneous *Pseudomonas* infections

1
2
3
4
5
6
7
8
9
10
11
12
13
14
15
16
17
18
19
20
21
22
23
24
25
26
27
28
29
30
31

A 34-year-old man comes to the emergency department due to 2 days of fever, malaise, and myalgia. He has also had worsening shortness of breath and cough. The patient works in the mail room at a large company, does not smoke cigarettes, and drinks alcohol occasionally. Chest imaging shows lung infiltrates and prominent widening of the mediastinum. Sputum and blood cultures yield large, gram-positive rods that form colonies resembling a "Medusa head." Which of the following is the most likely bacterial virulence factor contributing to this patient's condition?

A. Antiphagocytic D-glutamate capsule

B. Antiphagocytic polysaccharide capsule

C. IgG-binding, outer membrane protein

D. Intracellular polyphosphate granules

E. Peritrichous flagella

Submit

A 34-year-old man comes to the emergency department due to 2 days of fever, malaise, and myalgia. He has also had worsening shortness of breath and cough. The patient works in the mail room at a large company, does not smoke cigarettes, and drinks alcohol occasionally. Chest imaging shows lung infiltrates and prominent widening of the mediastinum. Sputum and blood cultures yield large, gram-positive rods that form colonies resembling a "Medusa head." Which of the following is the most likely bacterial virulence factor contributing to this patient's condition?

- ✓ A. Antiphagocytic D-glutamate capsule (67%)
- B. Antiphagocytic polysaccharide capsule (15%)
- C. IgG-binding, outer membrane protein (4%)
- D. Intracellular polyphosphate granules (6%)
- E. Peritrichous flagella (6%)

Omitted
Correct answer
A

67%
Answered correctly

02 secs
Time Spent

01/12/2020
Last Updated

Explanation

Bacillus anthracis is a large, nonmotile, nonhemolytic, gram-positive rod that forms colonies in culture with multiple curled extensions at the edges that resemble a "**Medusa head**." Because the organism proliferates in soil contaminated with manure, pasture-grazing herbivores such as sheep, cattle, and horses are at greatest risk for infection. However, transmission to humans occasionally occurs when *B anthracis* **spores** are inhaled, ingested, or inoculated into the skin.

Inhalation of spores into the alveoli causes **pulmonary anthrax**. Alveolar macrophages phagocytose the spores and bring them to mediastinal lymph nodes, where the spores germinate into vegetative rods and multiply. The vegetative form of the bacteria contains a **polypeptide capsule**

Bacillus anthracis is a large, nonmotile, nonhemolytic, gram-positive rod that forms colonies in culture with multiple curled extensions at the edges that resemble a "**Medusa head**." Because the organism proliferates in soil contaminated with manure, pasture-grazing herbivores such as sheep, cattle, and horses are at greatest risk for infection. However, transmission to humans occasionally occurs when *B anthracis* **spores** are inhaled, ingested, or inoculated into the skin.

Inhalation of spores into the alveoli causes **pulmonary anthrax**. Alveolar macrophages phagocytose the spores and bring them to mediastinal lymph nodes, where the spores germinate into vegetative rods and multiply. The vegetative form of the bacteria contains a **polypeptide capsule** composed of **D-glutamic acid**, which is antiphagocytic. *B anthracis* rods also produce a potent **exotoxin complex** composed of edema factor, lethal factor, and protective antigen, which enter host cells and cause cell death.

Initial manifestations of infection are nonspecific (eg, myalgia, fever, malaise), but proliferation of the bacteria in the mediastinum eventually causes **hemorrhagic mediastinitis** (often visible on chest x-ray as a widened mediastinum). Subsequent dissemination through the bloodstream causes shock, brain edema/hemorrhage, and death. Although pulmonary anthrax is quite rare, it can be seen in individuals who handle contaminated hides or animal hair ("woolsorter's disease") or those exposed to aerosolized **biologic weapons** (eg, opening contaminated mail).

(Choice B) Many bacteria (eg, *Streptococcus pneumoniae*) are resistant to phagocytosis due to the presence of a polysaccharide capsule. However, *B anthracis* has a polypeptide, not polysaccharide, capsule.

(Choice C) *Staphylococcus aureus* produces protein A, which binds the Fc portion of IgG. This inhibits opsonization and complement-mediated killing of the bacteria.

(Choice D) Intracellular polyphosphate granules are characteristic of *Corynebacterium diphtheriae*; they can be visualized on microscopy after growing the pathogen on Loeffler medium and staining it with methylene blue.

(Choice E) Peritrichous flagella (flagella distributed uniformly over the entire surface of a bacterial cell) are not present on the surface of *B anthracis* as this organism is nonmotile. Peritrichous flagella are characteristic of highly motile organisms such as *Proteus mirabilis*.

Educational objective:
Bacillus anthracis is a large, sporulating, gram-positive rod that is encased in an antiphagocytic polypeptide capsule composed of D-glutamic acid. Inhalation of *B anthracis* spores can cause pulmonary anthrax, which is usually characterized by nonspecific symptoms followed by hemorrhagic mediastinitis, shock, and death.

1 2 3 4 5 6 7 8 9 10 11 12 13 14 15 16 17 18 19 20 21 22 23 24 25 26 27 28 29 30 31

Inhalation of spores into the alveoli causes **pulmonary anthrax**. Alveolar macrophages phagocytose the spores and bring them to mediastinal lymph nodes, where the spores germinate into vegetative rods and multiply. The vegetative form of the bacteria contains a **polypeptide capsule** composed of **D-glutamic acid**, which is antiphagocytic. *B anthracis* rods also produce a potent **exotoxin complex** composed of edema factor, lethal factor, and protective antigen, which enter host cells and cause cell death.

Initial manifestations of infection are nonspecific (eg, myalgia, fever, malaise), but proliferation of the bacteria in the mediastinum eventually causes **hemorrhagic mediastinitis** (often visible on chest x-ray as a widened mediastinum). Subsequent dissemination through the bloodstream causes shock, brain edema/hemorrhage, and death. Although pulmonary anthrax is quite rare, it can be seen in individuals who handle contaminated hides or animal hair ("woolsorter's disease") or those exposed to aerosolized **biologic weapons** (eg, opening contaminated mail).

(Choice B) Many bacteria (eg, *Streptococcus pneumoniae*) are resistant to phagocytosis due to the presence of a polysaccharide capsule. However, *B anthracis* has a polypeptide, not polysaccharide, capsule.

(Choice C) *Staphylococcus aureus* produces protein A, which binds the Fc portion of IgG. This inhibits opsonization and complement-mediated killing of the bacteria.

(Choice D) Intracellular polyphosphate granules are characteristic of *Corynebacterium diphtheriae*; they can be visualized on microscopy after growing the pathogen on Loeffler medium and staining it with methylene blue.

(Choice E) Peritrichous flagella (flagella distributed uniformly over the entire surface of a bacterial cell) are not present on the surface of *B anthracis* as this organism is nonmotile. Peritrichous flagella are characteristic of highly motile organisms such as *Proteus mirabilis*.

Educational objective:
Bacillus anthracis is a large, sporulating, gram-positive rod that is encased in an antiphagocytic polypeptide capsule composed of D-glutamic acid. Inhalation of *B anthracis* spores can cause pulmonary anthrax, which is usually characterized by nonspecific symptoms followed by hemorrhagic mediastinitis, shock, and death.

Microbiology	Infectious Diseases	Anthrax
Subject	System	Topic

Copyright © UWorld. All rights reserved.

1
2
3
4
5
6
7
8
9
10
11
12
13
14
15
16
17
18
19
20
21
22
23
24
25
26
27
28
29
30
31

A 46-year-old man comes to the emergency department due to fever. He returned from a vacation in Southeast Asia a week ago and began having symptoms toward the end of his trip. The patient describes continuous fever that has risen slowly to reach a high plateau and is relieved only by antipyretics. He has also had headaches and abdominal discomfort; he initially had constipation but has had loose stools for the past several days. Temperature is 40 C (104 F), blood pressure is 114/68 mm Hg, and pulse is 62/min. No oropharyngeal lesions, cervical lymphadenopathy, or neck rigidity is present. Lungs are clear on auscultation, and heart sounds are normal. Abdominal examination shows mild distension and generalized tenderness with hepatosplenomegaly. There is a faint, erythematous, macular skin rash over the trunk and abdomen. Laboratory studies reveal mild, normocytic, normochromic anemia and leukopenia with left shift. Peripheral blood smear is normal. Which of the following is the most likely route of transmission of this patient's infection?

- A. Bite from a vector insect
- B. Exposure to a carrier animal
- C. Ingestion of contaminated food
- D. Inhalation of infectious droplets
- E. Sexual contact with infected person

Submit

A 46-year-old man comes to the emergency department due to fever. He returned from a vacation in Southeast Asia a week ago and began having symptoms toward the end of his trip. The patient describes continuous fever that has risen slowly to reach a high plateau and is relieved only by antipyretics. He has also had headaches and abdominal discomfort; he initially had constipation but has had loose stools for the past several days. Temperature is 40 C (104 F), blood pressure is 114/68 mm Hg, and pulse is 62/min. No oropharyngeal lesions, cervical lymphadenopathy, or neck rigidity is present. Lungs are clear on auscultation, and heart sounds are normal. Abdominal examination shows mild distension and generalized tenderness with hepatosplenomegaly. There is a faint, erythematous, macular skin rash over the trunk and abdomen. Laboratory studies reveal mild, normocytic, normochromic anemia and leukopenia with left shift. Peripheral blood smear is normal. Which of the following is the most likely route of transmission of this patient's infection?

- A. Bite from a vector insect (40%)
- B. Exposure to a carrier animal (6%)
- ✓ C. Ingestion of contaminated food (45%)
- D. Inhalation of infectious droplets (4%)
- E. Sexual contact with infected person (3%)

Omitted
Correct answer
C

45%
Answered correctly

02 secs
Time Spent

03/27/2020
Last Updated

Explanation

	Clinical manifestations of typhoid fever

1
2
3
4
5
6
7
8
9
10
11
12
13
14
15
16
17
18
19
20
21
22
23
24
25
26
27
28
29
30
31

	Clinical manifestations of typhoid fever
Week 1	• Rising fever • Bacteremia • Relative bradycardia (pulse-temperature dissociation)
Week 2	• Abdominal pain • Rose spots on trunk & abdomen
Week 3	• Hepatosplenomegaly • Intestinal bleeding & perforation

Typhoid fever is a life-threatening infection caused by *Salmonella* Typhi or Paratyphi. These gram-negative, enteric pathogens reside only in the gastrointestinal tract of humans **(Choice B)**. Transmission occurs via the **fecal-oral route**, primarily due to ingestion of **food or water contaminated** by human feces. Therefore, most cases arise in the developing world where sanitation is poor. Travelers who have not been vaccinated (with typhoid vaccine) are at risk and may return clinically ill.

Typhoidal *Salmonella* species invade enterocytes, travel from the apical to the basolateral end of the cell in vacuoles, and emerge in the intestinal submucosa. Here, the organism is phagocytosed by macrophages but is able to evade destruction due to a specialized capsular antigen (Vi) that impairs the macrophage-mediated oxidative burst. The pathogen subsequently replicates in an unchecked fashion within macrophages and spreads through the lymphatic and reticuloendothelial system, leading to widespread, systemic illness.

Manifestations typically develop over weeks in a step-wise fashion. Patients usually develop a **progressive fever**, often with relative bradycardia (**pulse-temperature dissociation**), followed by abdominal pain, salmon-colored macules on the trunk ("**rose spots**"), and constipation or diarrhea. Dissemination through the reticuloendothelial system often causes hepatosplenomegaly, anemia, and leukopenia. Later, ulceration of Peyer patches (lymphoid aggregations in the small intestine submucosa) can result in gastrointestinal bleeding or intestinal perforation. Antibiotic treatment is required to prevent complications and death.

(Choice A) Malaria is transmitted by the bite of the female *Anopheles* mosquito and typically causes paroxysmal fever with nonspecific symptoms (eg, chills, fatigue, headache, myalgias). However, the fever is almost always associated with tachycardia (not bradycardia), and peripheral blood

1 2 3 4 5 6 7 8 9 10 11 12 13 14 15 16 17 18 19 20 21 22 23 24 25 26 27 28 29 30 31

Typhoid fever is a life-threatening infection caused by *Salmonella* Typhi or Paratyphi. These gram-negative, enteric pathogens reside only in the gastrointestinal tract of humans **(Choice B)**. Transmission occurs via the **fecal-oral route**, primarily due to ingestion of **food or water contaminated** by human feces. Therefore, most cases arise in the developing world where sanitation is poor. Travelers who have not been vaccinated (with typhoid vaccine) are at risk and may return clinically ill.

Typhoidal *Salmonella* species invade enterocytes, travel from the apical to the basolateral end of the cell in vacuoles, and emerge in the intestinal submucosa. Here, the organism is phagocytosed by macrophages but is able to evade destruction due to a specialized capsular antigen (Vi) that impairs the macrophage-mediated oxidative burst. The pathogen subsequently replicates in an unchecked fashion within macrophages and spreads through the lymphatic and reticuloendothelial system, leading to widespread, systemic illness.

Manifestations typically develop over weeks in a step-wise fashion. Patients usually develop a **progressive fever**, often with relative bradycardia (**pulse-temperature dissociation**), followed by abdominal pain, salmon-colored macules on the trunk ("**rose spots**"), and constipation or diarrhea. Dissemination through the reticuloendothelial system often causes hepatosplenomegaly, anemia, and leukopenia. Later, ulceration of Peyer patches (lymphoid aggregations in the small intestine submucosa) can result in gastrointestinal bleeding or intestinal perforation. Antibiotic treatment is required to prevent complications and death.

(Choice A) Malaria is transmitted by the bite of the female *Anopheles* mosquito and typically causes paroxysmal fever with nonspecific symptoms (eg, chills, fatigue, headache, myalgias). However, the fever is almost always associated with tachycardia (not bradycardia), and peripheral blood smear will usually demonstrate the parasite and/or signs of red blood cell lysis.

(Choice D) Meningococcal meningitis is transmitted by aerosolized droplets from a carrier or infected patient and is associated with rapid-onset confusion, sepsis, hypotension, and a petechial/purpuric rash.

(Choice E) *Treponema pallidum*, the spirochete that causes syphilis, is transmitted sexually. Secondary syphilis is usually characterized by a widespread maculopapular rash that involves the palms and soles, generalized lymphadenopathy, and constitutional symptoms such as fever, headache, and myalgias. This patient's pulse-temperature dissociation, limited rash, and lack of adenopathy make syphilis less likely than typhoid fever.

Educational objective:
Typhoid fever is caused by *Salmonella* Typhi or Paratyphi and presents with escalating fever, followed by abdominal pain, formation of rose spots on the chest/abdomen, and hemorrhagic enteritis with possible bowel perforation. Humans are the only reservoir; transmission is fecal-oral and primarily occurs due to ingestion of food or water contaminated with feces.

1
2
3
4
5
6
7
8
9
10
11
12
13
14
15
16
17
18
19
20
21
22
23
24
25
26
27
28
29
30
31

impairs the macrophage-mediated oxidative burst. The pathogen subsequently replicates in an unchecked fashion within macrophages and spreads through the lymphatic and reticuloendothelial system, leading to widespread, systemic illness.

Manifestations typically develop over weeks in a step-wise fashion. Patients usually develop a **progressive fever**, often with relative bradycardia (**pulse-temperature dissociation**), followed by abdominal pain, salmon-colored macules on the trunk ("**rose spots**"), and constipation or diarrhea. Dissemination through the reticuloendothelial system often causes hepatosplenomegaly, anemia, and leukopenia. Later, ulceration of Peyer patches (lymphoid aggregations in the small intestine submucosa) can result in gastrointestinal bleeding or intestinal perforation. Antibiotic treatment is required to prevent complications and death.

(Choice A) Malaria is transmitted by the bite of the female *Anopheles* mosquito and typically causes paroxysmal fever with nonspecific symptoms (eg, chills, fatigue, headache, myalgias). However, the fever is almost always associated with tachycardia (not bradycardia), and peripheral blood smear will usually demonstrate the parasite and/or signs of red blood cell lysis.

(Choice D) Meningococcal meningitis is transmitted by aerosolized droplets from a carrier or infected patient and is associated with rapid-onset confusion, sepsis, hypotension, and a petechial/purpuric rash.

(Choice E) *Treponema pallidum*, the spirochete that causes syphilis, is transmitted sexually. Secondary syphilis is usually characterized by a widespread maculopapular rash that involves the palms and soles, generalized lymphadenopathy, and constitutional symptoms such as fever, headache, and myalgias. This patient's pulse-temperature dissociation, limited rash, and lack of adenopathy make syphilis less likely than typhoid fever.

Educational objective:
Typhoid fever is caused by *Salmonella* Typhi or Paratyphi and presents with escalating fever, followed by abdominal pain, formation of rose spots on the chest/abdomen, and hemorrhagic enteritis with possible bowel perforation. Humans are the only reservoir; transmission is fecal-oral and primarily occurs due to ingestion of food or water contaminated with feces.

Microbiology	Infectious Diseases	Typhoid
Subject	System	Topic

Copyright © UWorld. All rights reserved.

impairs the macrophage-mediated oxidative burst. The pathogen subsequently replicates in an unchecked fashion within macrophages and

Exhibit Display

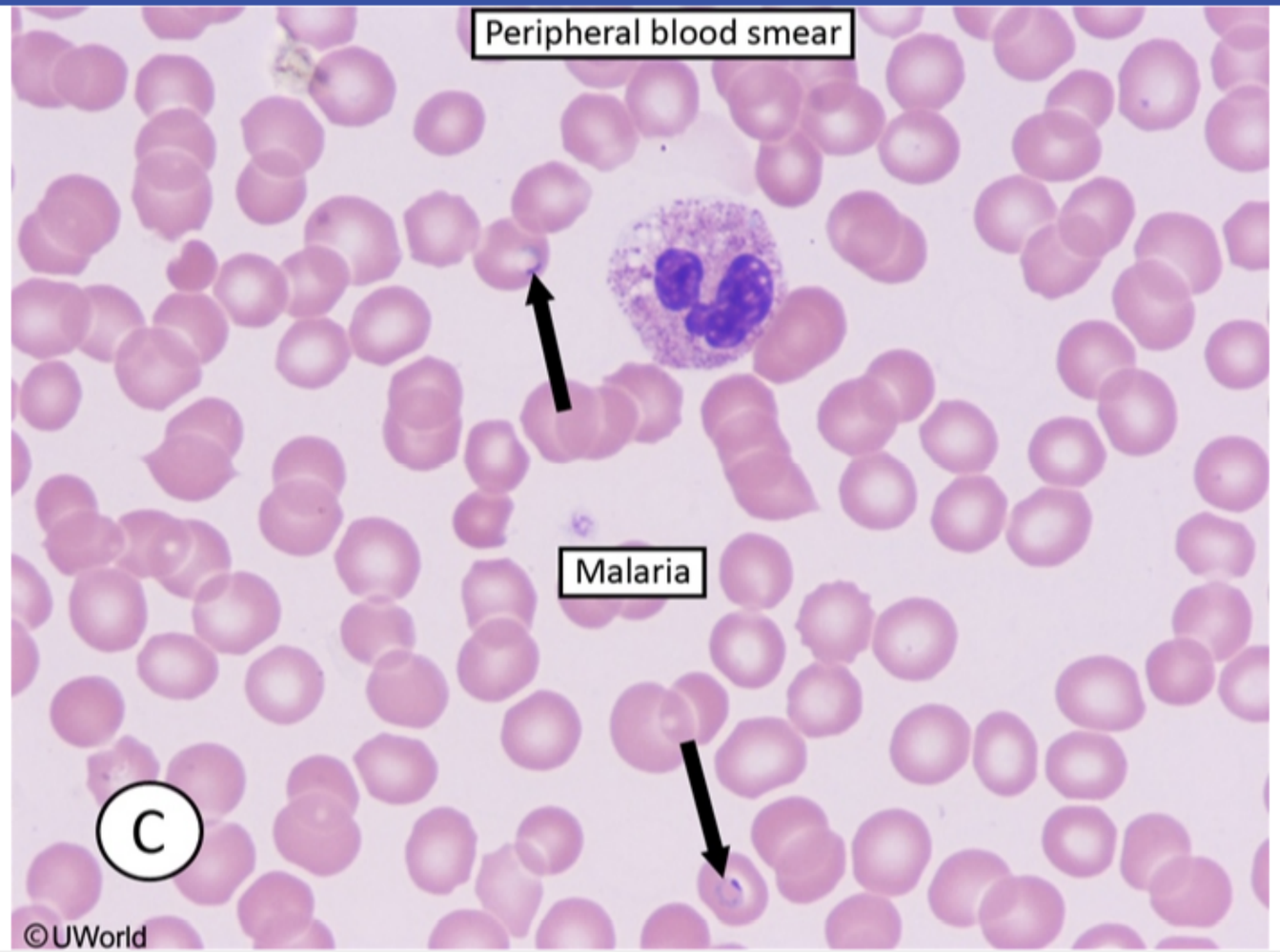

Zoom In | Zoom Out | Reset | Add To New Card | Existing Card

1
2
3
4
5
6
7
8
9
10
11
12
13
14
15
16
17
18
19
20
21
22
23
24
25
26
27
28
29
30
31

A 43-year-old immigrant from Southern Asia suffers from a cough that has lasted for several months duration. He comes to the clinic today because of recent onset hemoptysis. On further evaluation, he reports a 15-lb weight loss over the past four months. Sputum cultures grow acid-fast bacilli that are susceptible to most antimycobacterial drugs *in vitro*. Isoniazid monotherapy in this patient would most likely result in:

A. Bacteriocidal effect on only extracellular bacilli

B. Decreased transport protein expression on the cell surface

C. β-lactamase induction within bacterial cells

D. Rapid mycobacterial elimination from the body

E. Selective survival of bacterial cells secondary to gene mutation

Submit

1
2
3
4
5
6
7
8
9
10
11
12
13
14
15
16
17
18
19
20
21
22
23
24
25
26
27
28
29
30
31

A 43-year-old immigrant from Southern Asia suffers from a cough that has lasted for several months duration. He comes to the clinic today because of recent onset hemoptysis. On further evaluation, he reports a 15-lb weight loss over the past four months. Sputum cultures grow acid-fast bacilli that are susceptible to most antimycobacterial drugs *in vitro*. Isoniazid monotherapy in this patient would most likely result in:

A. Bacteriocidal effect on only extracellular bacilli (16%)

B. Decreased transport protein expression on the cell surface (10%)

C. β-lactamase induction within bacterial cells (1%)

D. Rapid mycobacterial elimination from the body (8%)

✓ E. Selective survival of bacterial cells secondary to gene mutation (62%)

Omitted
Correct answer
E

62%
Answered correctly

02 secs
Time Spent

01/15/2020
Last Updated

Explanation

This patient most likely has active tuberculosis, which should never be treated with drug monotherapy due to the rapid emergence of antibiotic resistance in *M. tuberculosis*. Isoniazid resistance specifically occurs by two selective gene mutations. The first is a decrease in bacterial expression of the catalase-peroxidase enzyme that is required for isoniazid activation once the drug enters the bacterial cell. The second mechanism of resistance occurs through modification of the protein target binding site for isoniazid. Treatment of active tuberculosis is accomplished by combining multiple antibiotics to avoid selecting for resistant strains. Commonly used drug regimens include isoniazid and rifampin in addition to streptomycin, ethambutol, and/or pyrazinamide.

This patient most likely has active tuberculosis, which should never be treated with drug monotherapy due to the rapid emergence of antibiotic resistance in *M. tuberculosis*. Isoniazid resistance specifically occurs by two selective gene mutations. The first is a decrease in bacterial expression of the catalase-peroxidase enzyme that is required for isoniazid activation once the drug enters the bacterial cell. The second mechanism of resistance occurs through modification of the protein target binding site for isoniazid. Treatment of active tuberculosis is accomplished by combining multiple antibiotics to avoid selecting for resistant strains. Commonly used drug regimens include isoniazid and rifampin in addition to streptomycin, ethambutol, and/or pyrazinamide.

Isoniazid monotherapy may be used for patients who have a positive PPD and a negative chest x-ray (i.e., no evidence of clinical disease).

(Choice A) For isoniazid monotherapy to result in the selective survival of intracellular bacilli would suggest that isoniazid is unable to penetrate into (or is otherwise degraded by) macrophages that house *M. tuberculosis*. However, this is not the case. Isoniazid can reach therapeutic levels within macrophages, areas of caseous necrosis, and cerebrospinal fluid.

(Choice B) Decreased transport protein expression at the cell surface would interfere with the effectiveness of drugs that require protein-mediated transport into the bacterial cell to reach the intended target (eg, fluoroquinolones, macrolides, aminoglycosides).

(Choice C) β-lactamase induction within bacterial cells would not result from isoniazid exposure because isoniazid is not a beta-lactam antibiotic.

(Choice D) Rapid mycobacterial elimination from the body occurs when a small inoculum is recognized and quickly destroyed by the cell-mediated immune system. This happens in the majority of exposures. By the time tuberculosis has progressed to active, symptomatic disease, large caseous and liquefactive necrotic granulomas have usually formed and a lengthy treatment period with appropriate multidrug therapy is required to eradicate the organism. Antibiotic therapy for tuberculosis lasts a minimum of six months.

Educational Objective:
Active tuberculosis is never treated with drug monotherapy due to the fast emergence of mycobacterial antibiotic resistance from rapid, selective gene mutations. Isoniazid monotherapy may be used for patients who have a positive PPD and a negative chest x-ray (ie, no evidence of clinical disease).

References

- The catalase-peroxidase gene and isoniazid resistance of Mycobacterium tuberculosis.
- Modification of the NADH of the isoniazid target (InhA) from Mycobacterium tuberculosis.

1
2
3
4
5
6
7
8
9
10
11
12
13
14
15
16
17
18
19
20
21
22
23
24
25
26
27
28
29
30
31

rifampin in addition to streptomycin, ethambutol, and/or pyrazinamide.

Isoniazid monotherapy may be used for patients who have a positive PPD and a negative chest x-ray (i.e., no evidence of clinical disease).

(Choice A) For isoniazid monotherapy to result in the selective survival of intracellular bacilli would suggest that isoniazid is unable to penetrate into (or is otherwise degraded by) macrophages that house *M. tuberculosis*. However, this is not the case. Isoniazid can reach therapeutic levels within macrophages, areas of caseous necrosis, and cerebrospinal fluid.

(Choice B) Decreased transport protein expression at the cell surface would interfere with the effectiveness of drugs that require protein-mediated transport into the bacterial cell to reach the intended target (eg, fluoroquinolones, macrolides, aminoglycosides).

(Choice C) β-lactamase induction within bacterial cells would not result from isoniazid exposure because isoniazid is not a beta-lactam antibiotic.

(Choice D) Rapid mycobacterial elimination from the body occurs when a small inoculum is recognized and quickly destroyed by the cell-mediated immune system. This happens in the majority of exposures. By the time tuberculosis has progressed to active, symptomatic disease, large caseous and liquefactive necrotic granulomas have usually formed and a lengthy treatment period with appropriate multidrug therapy is required to eradicate the organism. Antibiotic therapy for tuberculosis lasts a minimum of six months.

Educational Objective:
Active tuberculosis is never treated with drug monotherapy due to the fast emergence of mycobacterial antibiotic resistance from rapid, selective gene mutations. Isoniazid monotherapy may be used for patients who have a positive PPD and a negative chest x-ray (ie, no evidence of clinical disease).

References

- The catalase-peroxidase gene and isoniazid resistance of Mycobacterium tuberculosis.
- Modification of the NADH of the isoniazid target (InhA) from Mycobacterium tuberculosis.

Microbiology	Infectious Diseases	Tuberculosis
Subject	System	Topic

Copyright © UWorld. All rights reserved.

1
2
3
4
5
6
7
8
9
10
11
12
13
14
15
16
17
18
19
20
21
22
23
24
25
26
27
28
29
30
31

A 31-year-old man comes to the emergency department after a witnessed tonic-clonic seizure. The patient has no known medical problems. He grew up in a rural part of Guatemala and immigrated to the United States 3 years ago. He works as an architect and owns a cat. He has no history of tuberculosis. On examination, he is afebrile and has no focal neurologic deficits or meningeal signs. An HIV antibody test and an interferon-gamma release assay test are negative. Chest x-ray is normal. An MRI of the brain reveals a 2.5-centimeter cyst within the left sylvian fissure that has minimal enhancement and no associated edema. Which of the following is the most likely means of acquisition of the infection responsible for this patient's findings?

A. Absorption through skin on feet
B. Exposure to infected stool
C. Handling of cat litter box
D. Inhalation of fungal spores
E. Scratch from a cat
F. Sexual transmission

Submit

A 31-year-old man comes to the emergency department after a witnessed tonic-clonic seizure. The patient has no known medical problems. He grew up in a rural part of Guatemala and immigrated to the United States 3 years ago. He works as an architect and owns a cat. He has no history of tuberculosis. On examination, he is afebrile and has no focal neurologic deficits or meningeal signs. An HIV antibody test and an interferon-gamma release assay test are negative. Chest x-ray is normal. An MRI of the brain reveals a 2.5-centimeter cyst within the left sylvian fissure that has minimal enhancement and no associated edema. Which of the following is the most likely means of acquisition of the infection responsible for this patient's findings?

- A. Absorption through skin on feet (6%)
- ✓ B. Exposure to infected stool (37%)
- C. Handling of cat litter box (38%)
- D. Inhalation of fungal spores (8%)
- E. Scratch from a cat (5%)
- F. Sexual transmission (3%)

Omitted
Correct answer
B

37%
Answered correctly

02 secs
Time Spent

01/23/2020
Last Updated

Explanation

Neurocysticercosis

1
2
3
4
5
6
7
8
9
10
11
12
13
14
15
16
17
18
19
20
21
22
23
24
25
26
27
28
29
30
31

Neurocysticercosis	
Microbiology	• Ingestion of ***Taenia solium*** **(pork tapeworm) eggs** excreted in feces of human carriers
Clinical presentation	• Common in **Central & South America**, sub-Saharan Africa, Asia • Prolonged incubation (months to years) • **Seizures**, focal neurologic symptoms, intracranial hypertension (CSF obstruction)
Diagnosis	• CT/MRI - **cysts**, **scolex** • **Eosinophilia**, ↑ESR
Management	• Antiparasitic therapy (albendazole)

CSF = cerebrospinal fluid; **ESR** = erythrocyte sedimentation rate.

©UWorld

This patient who grew up in a rural part of Guatemala and has no underlying immunocompromising conditions had a seizure and is found to have a cystic brain lesion on MRI. This presentation is most consistent with **neurocysticercosis** caused by ***Taenia solium***, the **pork tapeworm**. Although rare in the United States, *T solium* is endemic in **Central and South America** (particularly in rural areas), and neurocysticercosis should be considered in patients from these areas who develop **seizures** or neurologic symptoms.

Ingestion of **eggs** from the **stool** of tapeworm carriers can lead to cysticercosis (consumption of infected uncooked pork, which contains the larval cysts but not the eggs, can lead to tapeworm infestation [taeniasis] but not cysticercosis). Embryos attach to and penetrate the wall of the small intestine and subsequently migrate hematogenously to tissues, including the brain, where they form **cysticerci**, fluid-filled **larval cysts**

©UWorld

This patient who grew up in a rural part of Guatemala and has no underlying immunocompromising conditions had a seizure and is found to have a cystic brain lesion on MRI. This presentation is most consistent with **neurocysticercosis** caused by ***Taenia solium***, the **pork tapeworm**. Although rare in the United States, *T solium* is endemic in **Central and South America** (particularly in rural areas), and neurocysticercosis should be considered in patients from these areas who develop **seizures** or neurologic symptoms.

Ingestion of **eggs** from the **stool** of tapeworm carriers can lead to cysticercosis (consumption of infected uncooked pork, which contains the larval cysts but not the eggs, can lead to tapeworm infestation [taeniasis] but not cysticercosis). Embryos attach to and penetrate the wall of the small intestine and subsequently migrate hematogenously to tissues, including the brain, where they form **cysticerci**, fluid-filled **larval cysts** surrounding the invaginated scolex (head of tapeworm with hooklets).

(Choice A) *Strongyloides stercoralis* infection can be caused by larvae penetration through the exposed skin of feet. Manifestations include eosinophilia and gastrointestinal disease (among immunocompetent individuals) or hyperinfection (typically among immunocompromised patients). Brain cysts would be unlikely.

(Choice C) Cat feces contain *Toxoplasma gondii*. Reactivation of disease in immunocompromised patients, particularly those with AIDS, can cause cerebral toxoplasmosis (multiple ring-enhancing lesions). However, brain infection is exceedingly rare among immunocompetent patients and would be extremely unlikely in this patient who does not have HIV.

(Choice D) Infections caused by endemic dimorphic mycoses, including histoplasmosis and blastomycosis, may be due to spore inhalation. However, neurologic presentations are rare and would be very uncommon in the absence of pulmonary abnormalities.

(Choice E) Cat scratch disease, caused by *Bartonella henselae*, is most commonly associated with localized skin/soft tissue infection and (often self-limiting) proximal lymphadenitis.

(Choice F) Syphilis, a sexually transmitted infection, can present with neurologic manifestations, including meningitis, cranial nerve palsies, and tabes dorsalis. Seizures and a cystic brain lesion in a patient from rural Guatemala are more suggestive of neurocysticercosis.

Educational objective:
Neurocysticercosis is a relatively common cause of seizures in patients from Central and South America and should be considered in patients with suggestive symptoms and imaging (eg, cystic brain lesion) and characteristic epidemiological risk factors.

1
2
3
4
5
6
7
8
9
10
11
12
13
14
15
16
17
18
19
20
21
22
23
24
25
26
27
28
29
30
31

Although rare in the United States, *T solium* is endemic in **Central and South America** (particularly in rural areas), and neurocysticercosis should be considered in patients from these areas who develop **seizures** or neurologic symptoms.

Ingestion of **eggs** from the **stool** of tapeworm carriers can lead to cysticercosis (consumption of infected uncooked pork, which contains the larval cysts but not the eggs, can lead to tapeworm infestation [taeniasis] but not cysticercosis). Embryos attach to and penetrate the wall of the small intestine and subsequently migrate hematogenously to tissues, including the brain, where they form **cysticerci**, fluid-filled **larval cysts** surrounding the invaginated scolex (head of tapeworm with hooklets).

(Choice A) *Strongyloides stercoralis* infection can be caused by larvae penetration through the exposed skin of feet. Manifestations include eosinophilia and gastrointestinal disease (among immunocompetent individuals) or hyperinfection (typically among immunocompromised patients). Brain cysts would be unlikely.

(Choice C) Cat feces contain *Toxoplasma gondii*. Reactivation of disease in immunocompromised patients, particularly those with AIDS, can cause cerebral toxoplasmosis (multiple ring-enhancing lesions). However, brain infection is exceedingly rare among immunocompetent patients and would be extremely unlikely in this patient who does not have HIV.

(Choice D) Infections caused by endemic dimorphic mycoses, including histoplasmosis and blastomycosis, may be due to spore inhalation. However, neurologic presentations are rare and would be very uncommon in the absence of pulmonary abnormalities.

(Choice E) Cat scratch disease, caused by *Bartonella henselae*, is most commonly associated with localized skin/soft tissue infection and (often self-limiting) proximal lymphadenitis.

(Choice F) Syphilis, a sexually transmitted infection, can present with neurologic manifestations, including meningitis, cranial nerve palsies, and tabes dorsalis. Seizures and a cystic brain lesion in a patient from rural Guatemala are more suggestive of neurocysticercosis.

Educational objective:
Neurocysticercosis is a relatively common cause of seizures in patients from Central and South America and should be considered in patients with suggestive symptoms and imaging (eg, cystic brain lesion) and characteristic epidemiological risk factors.

References

- Clinical symptoms, diagnosis and treatment of neurocysticercosis.
- Cysticercosis: An emerging parasitic disease.

Although rare in the United States, *T solium* is endemic in **Central and South America** (particularly in rural areas), and neurocysticercosis should

Exhibit Display

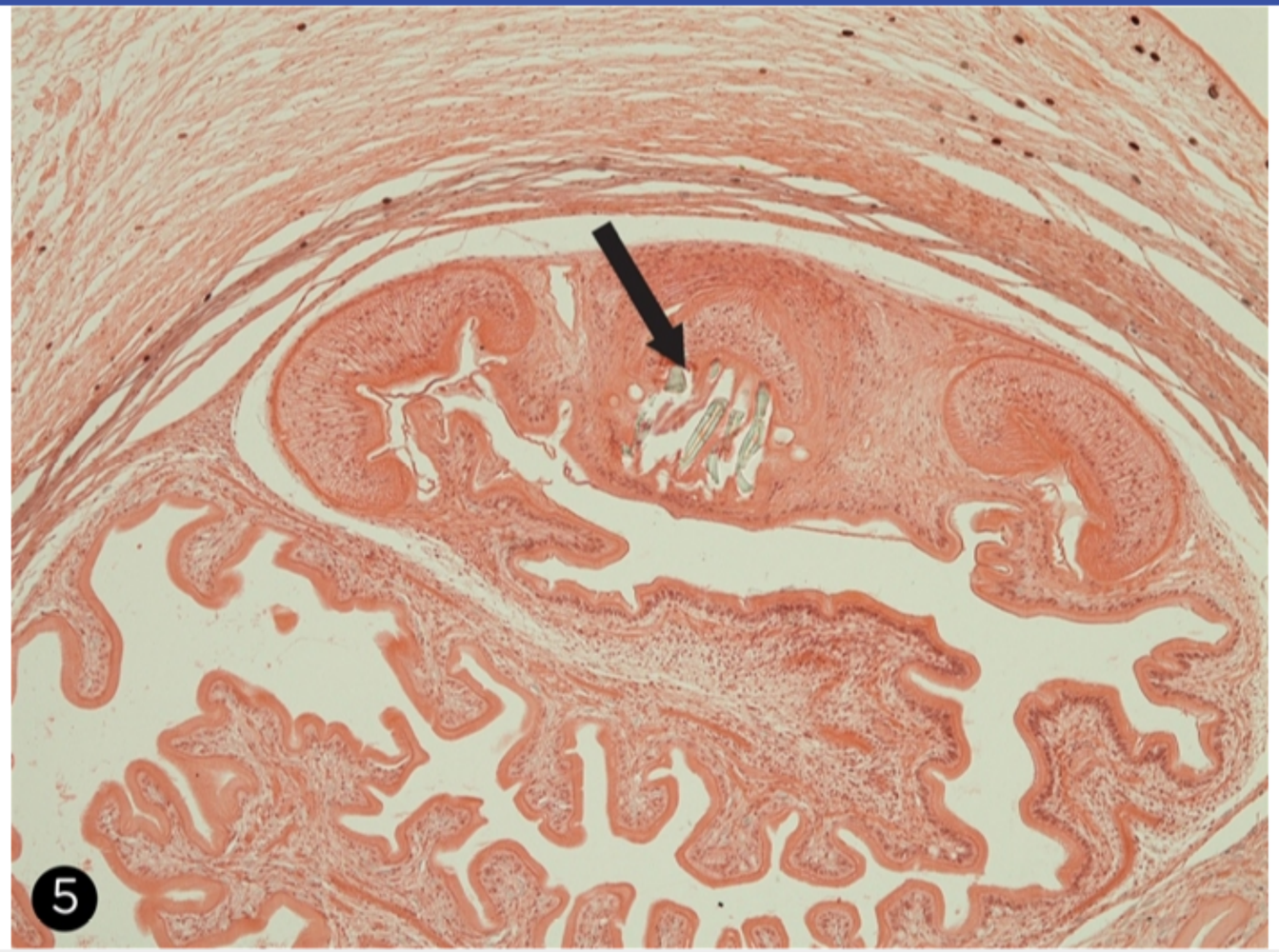

Zoom In | Zoom Out | Reset | Add To New Card | Existing Card

- Cysticercosis: An emerging parasitic disease.

1
2
3
4
5
6
7
8
9
10
11
12
13
14
15
16
17
18
19
20
21
22
23
24
25
26
27
28
29
30
31

Ingestion of **eggs** from the **stool** of tapeworm carriers can lead to cysticercosis (consumption of infected uncooked pork, which contains the larval cysts but not the eggs, can lead to tapeworm infestation [taeniasis] but not cysticercosis). Embryos attach to and penetrate the wall of the small intestine and subsequently migrate hematogenously to tissues, including the brain, where they form **cysticerci**, fluid-filled **larval cysts** surrounding the invaginated scolex (head of tapeworm with hooklets).

(Choice A) *Strongyloides stercoralis* infection can be caused by larvae penetration through the exposed skin of feet. Manifestations include eosinophilia and gastrointestinal disease (among immunocompetent individuals) or hyperinfection (typically among immunocompromised patients). Brain cysts would be unlikely.

(Choice C) Cat feces contain *Toxoplasma gondii*. Reactivation of disease in immunocompromised patients, particularly those with AIDS, can cause cerebral toxoplasmosis (multiple ring-enhancing lesions). However, brain infection is exceedingly rare among immunocompetent patients and would be extremely unlikely in this patient who does not have HIV.

(Choice D) Infections caused by endemic dimorphic mycoses, including histoplasmosis and blastomycosis, may be due to spore inhalation. However, neurologic presentations are rare and would be very uncommon in the absence of pulmonary abnormalities.

(Choice E) Cat scratch disease, caused by *Bartonella henselae*, is most commonly associated with localized skin/soft tissue infection and (often self-limiting) proximal lymphadenitis.

(Choice F) Syphilis, a sexually transmitted infection, can present with neurologic manifestations, including meningitis, cranial nerve palsies, and tabes dorsalis. Seizures and a cystic brain lesion in a patient from rural Guatemala are more suggestive of neurocysticercosis.

Educational objective:
Neurocysticercosis is a relatively common cause of seizures in patients from Central and South America and should be considered in patients with suggestive symptoms and imaging (eg, cystic brain lesion) and characteristic epidemiological risk factors.

References

- Clinical symptoms, diagnosis and treatment of neurocysticercosis.
- Cysticercosis: An emerging parasitic disease.

Microbiology Infectious Diseases Neurocysticercosis

1
2
3
4
5
6
7
8
9
10
11
12
13
14
15
16
17
18
19
20
21
22
23
24
25
26
27
28
29
30
31

A 34-year-old woman comes to the emergency department due to 6 days of fatigue and intermittent fever. Medical history is significant for depression. She does not use tobacco, alcohol, or illicit drugs and has no drug allergies. The patient lives in New York City and recently traveled to central Africa, where she helped establish a nutrition program. Her blood microscopy findings are shown in the exhibit. Urine pregnancy test is negative. Which of the following is the best treatment for this patient?

A. Atovaquone and proguanil

B. Ceftriaxone and doxycycline

C. Chloroquine and primaquine

D. Metronidazole and paromomycin

E. Trimethoprim and sulfamethoxazole

Submit

1
2
3
4
5
6
7
8
9
10
11
12
13
14
15
16
17
18
19
20
21
22
23
24
25
26
27
28
29
30
31

A 34-year-old woman comes to the emergency department due to 6 days of fatigue and intermittent fever. Medical history is significant for depression. She does not use tobacco, alcohol, or illicit drugs and has no drug allergies. The patient lives in New York City and recently traveled to central Africa, where she helped establish a nutrition program. Her blood microscopy findings are shown in the exhibit. Urine pregnancy test is negative. Which of the following is the best treatment for this patient?

- ✓ A. Atovaquone and proguanil (27%)
- B. Ceftriaxone and doxycycline (1%)
- C. Chloroquine and primaquine (68%)
- D. Metronidazole and paromomycin (1%)
- E. Trimethoprim and sulfamethoxazole (1%)

Omitted
Correct answer
A

27%
Answered correctly

02 secs
Time Spent

04/14/2020
Last Updated

Explanation

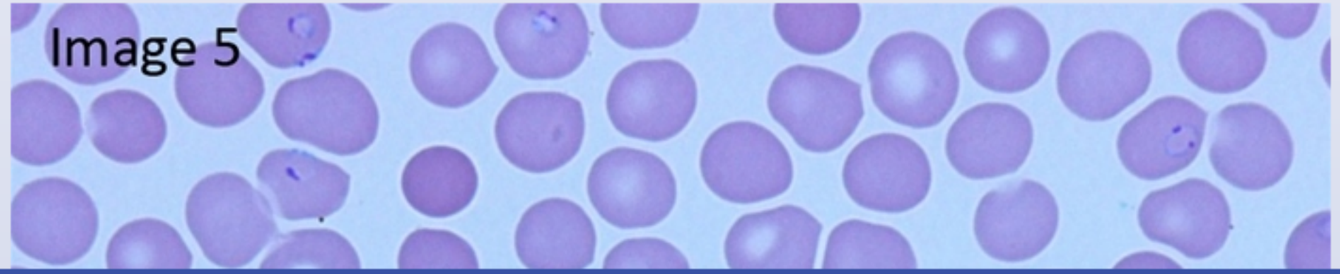

1
2
3
4
5
6
7
8
9
10
11
12
13
14
15
16
17
18
19
20
21
22
23
24
25
26
27
28
29
30
31

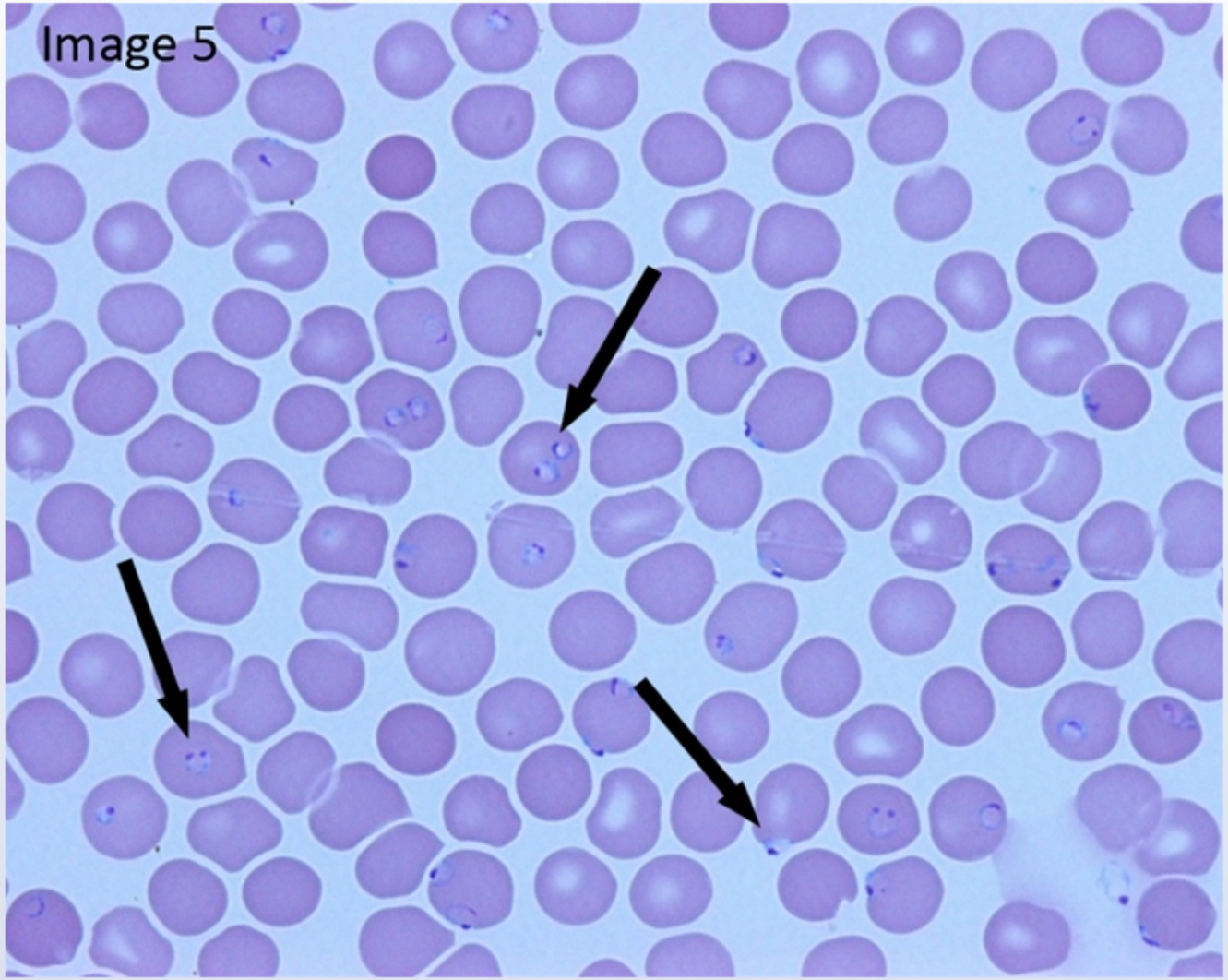

Although fever and fatigue are nonspecific symptoms, this patient's peripheral blood smear is diagnostic of **malaria**, a disease endemic to Africa and Latin America that is caused by 4 main species of ***Plasmodium***. The diagnosis is frequently made by examination of a peripheral blood

1
2
3
4
5
6
7
8
9
10
11
12
13
14
15
16
17
18
19
20
21
22
23
24
25
26
27
28
29
30
31

Although fever and fatigue are nonspecific symptoms, this patient's peripheral blood smear is diagnostic of **malaria**, a disease endemic to Africa and Latin America that is caused by 4 main species of ***Plasmodium***. The diagnosis is frequently made by examination of a peripheral blood smear with Giemsa staining. In *Plasmodium falciparum* infection, red blood cells have multiple **small rings** representing developing **trophozoites** (arrows) and banana-shaped gametocytes (not shown).

For malaria acquired in areas known to have chloroquine-sensitive organisms, chloroquine is the treatment of choice. Many African species are **chloroquine-resistant**; these can be treated with **atovaquone-proguanil** or **artemisinins**, which are well tolerated and have excellent cure rates. *P vivax* and *P ovale* have dormant liver forms (hypnozoites) that require the addition of primaquine therapy.

(Choice B) Early disseminated Lyme disease is associated with neurologic (eg, facial nerve palsy) and cardiac (eg, atrioventricular block, carditis) manifestations and is often treated with ceftriaxone. *Ixodes scapularis*, the tick that transmits Lyme disease, can also transmit babesiosis and ehrlichiosis, which can be treated with doxycycline. Although *Babesia* can appear as ring-like structures within blood cells, it is differentiated by the presence of 4 rings arranged in a Maltese cross pattern, which is pathognomonic for the disease.

(Choice C) *P falciparum* is the predominant malaria strain in Africa. Most *P falciparum* in Africa are resistant to chloroquine, so alternate agents (eg, atovaquone-proguanil, artemisinins) are required for treatment. Because *P falciparum* does not have a dormant hepatic phase, primaquine is not required.

(Choice D) *Entamoeba histolytica* is an amebic parasite that can cause dysentery (bloody diarrhea) and extraintestinal abscess in the liver (most common), lung, or brain. It is typically treated with metronidazole, to kill the trophozoites, and paromomycin, to eliminate residual cysts in the gastrointestinal lumen.

(Choice E) Trimethoprim-sulfamethoxazole is used to treat *Pneumocystis* pneumonia, which is most common in individuals with untreated AIDS or those taking chronic steroids. Patients usually present with slowly worsening dyspnea, dry cough, hypoxia, and diffuse interstitial infiltrates.

Educational objective:
Red blood cells filled with multiple, small rings suggest *Plasmodium* infection (malaria). Erythrocytic forms of this parasite may be treated with antimalarials such as chloroquine (in non-resistant areas), atovaquone-proguanil, and artemisinins. Primaquine is required to kill *P vivax* and *P ovale* liver hypnozoites.

References

1
2
3
4
5
6
7
8
9
10
11
12
13
14
15
16
17
18
19
20
21
22
23
24
25
26
27
28
29
30
31

Exhibit Display

Map of malaria regions

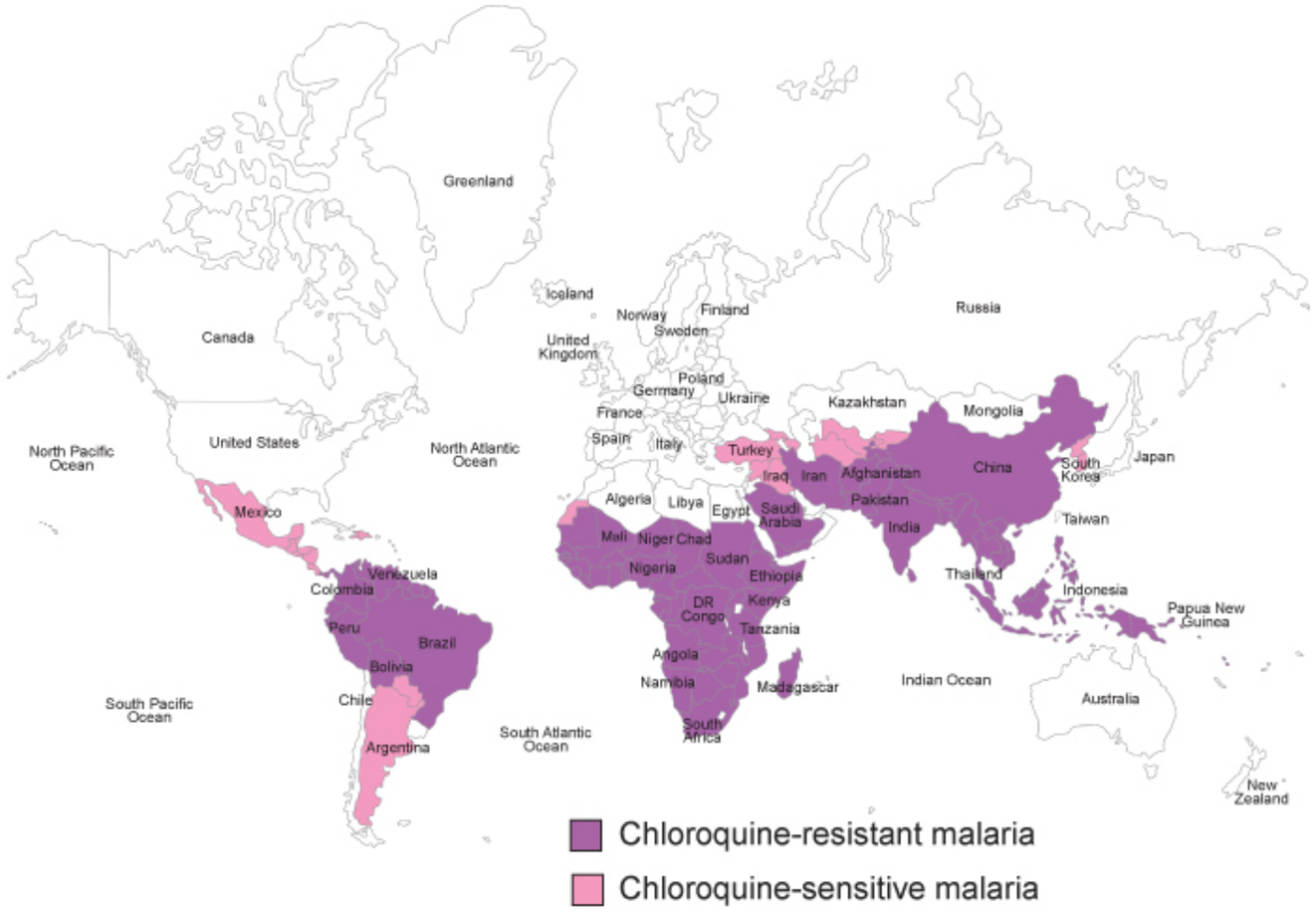

Zoom In | Zoom Out | Reset | Add To New Card | Existing Card

References

1
2
3
4
5
6
7
8
9
10
11
12
13
14
15
16
17
18
19
20
21
22
23
24
25
26
27
28
29
30
31

Exhibit Display

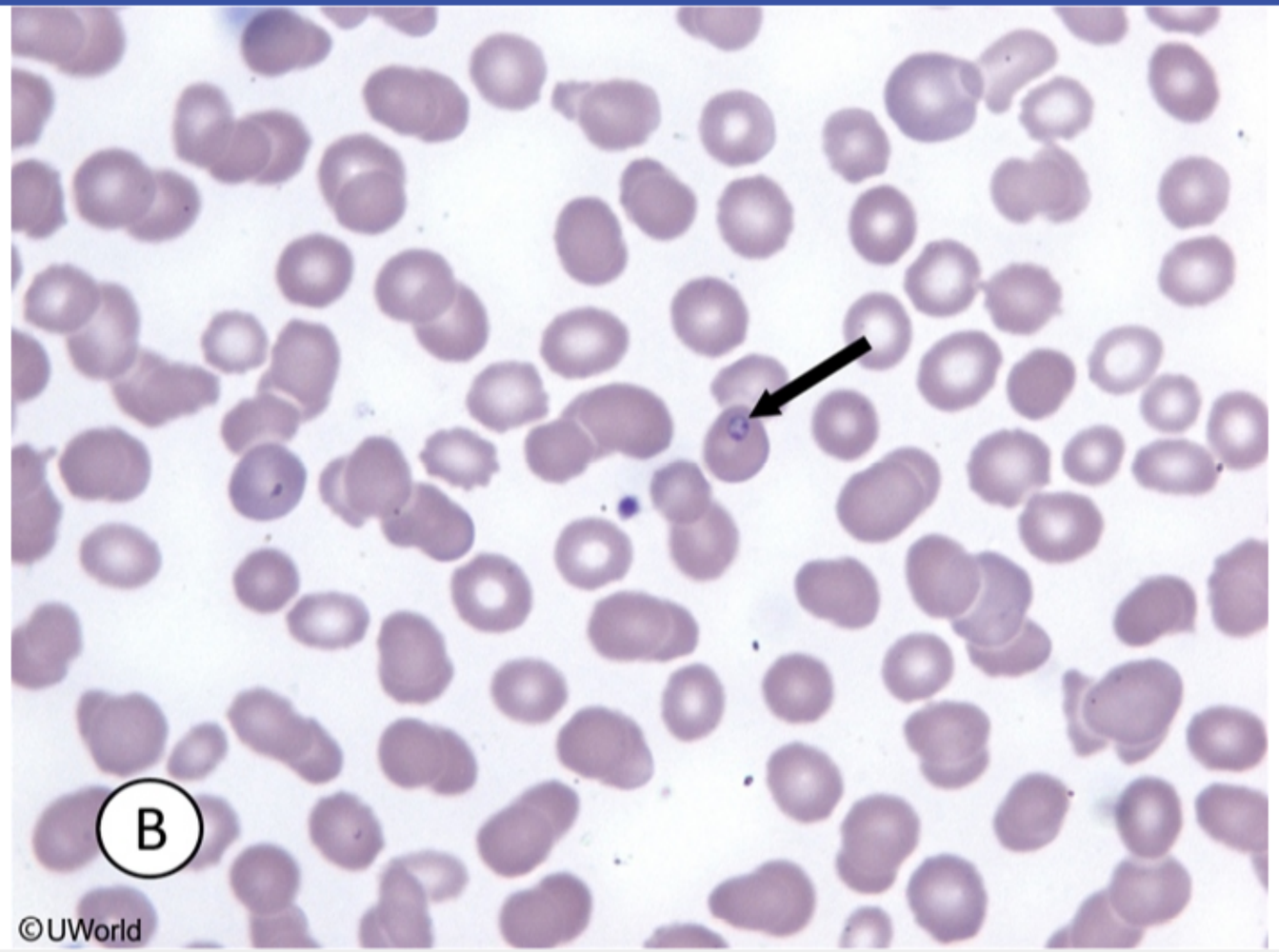

Zoom In | Zoom Out | Reset | Add To New Card | Existing Card

References

1
2
3
4
5
6
7
8
9
10
11
12
13
14
15
16
17
18
19
20
21
22
23
24
25
26
27
28
29
30
31

Exhibit Display

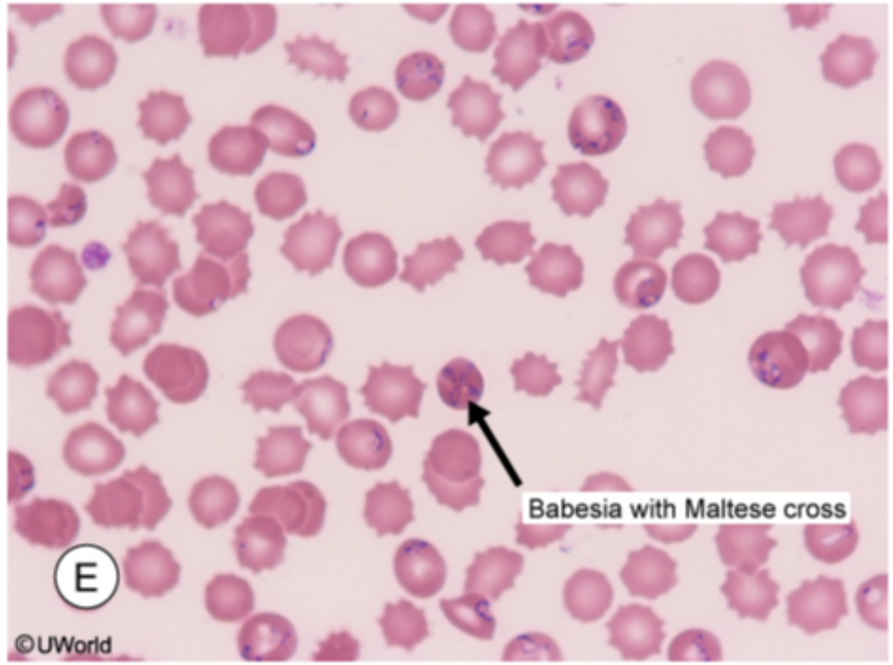

Zoom In | Zoom Out | Reset | Add To New Card | Existing Card

References

1
2
3
4
5
6
7
8
9
10
11
12
13
14
15
16
17
18
19
20
21
22
23
24
25
26
27
28
29
30
31

An 86-year-old woman is hospitalized for a urinary tract infection due to *Escherichia coli* and is being treated with ceftriaxone. She has a history of advanced dementia, coronary artery disease, and congestive heart failure. On the fifth day of hospitalization, she seems agitated. The nurse also reports that the patient had 3 episodes of diarrhea the previous night. Her temperature is 38.3 C (101 F). In addition to appropriate hand hygiene, which of the following equipment is necessary before examining this patient?

- A. Facemask, non-sterile gloves, and gown
- B. Respirator, sterile gloves, and gown
- C. Nonsterile gloves and gown
- D. Nonsterile gloves only
- E. Sterile gloves and gown
- F. Sterile gloves only

Submit

An 86-year-old woman is hospitalized for a urinary tract infection due to *Escherichia coli* and is being treated with ceftriaxone. She has a history of advanced dementia, coronary artery disease, and congestive heart failure. On the fifth day of hospitalization, she seems agitated. The nurse also reports that the patient had 3 episodes of diarrhea the previous night. Her temperature is 38.3 C (101 F). In addition to appropriate hand hygiene, which of the following equipment is necessary before examining this patient?

- A. Facemask, non-sterile gloves, and gown (19%)
- B. Respirator, sterile gloves, and gown (4%)
- ✓ C. Nonsterile gloves and gown (33%)
- D. Nonsterile gloves only (11%)
- E. Sterile gloves and gown (22%)
- F. Sterile gloves only (9%)

Omitted
Correct answer
C

33%
Answered correctly

02 secs
Time Spent

06/20/2020
Last Updated

Explanation

Contact precautions	
Organisms	• MDR organisms (eg, MRSA, VRE) • Enteric organisms (eg, *Clostridium difficile*) • Scabies

Contact precautions	
Organisms	• MDR organisms (eg, MRSA, VRE) • Enteric organisms (eg, *Clostridium difficile*) • Scabies
Infection-control measures	• Hand hygiene **(soap & water for *C difficile*)** • Nonsterile gloves • **Gown** • Private room preferred

MDR = multidrug-resistant; **MRSA** = methicillin-resistant *Staphylococcus aureus*; **VRE** = vancomycin-resistant *Enterococcus*.

This hospitalized patient's fever and diarrhea a few days after antibiotic initiation are concerning for ***Clostridium difficile*** infection. All hospitalized patients require **standard precautions**, including handwashing before and after patient contact, proper disposal of cleaning instruments and linens, and occasional use of gowns and gloves as required (eg, contact with body fluids).

However, cases of suspected or proven *C difficile* infection require additional **contact precautions**, including handwashing with **soap and water** (alcohol-based hand sanitizers do **not** kill the spores), **gown** for **any** patient contact, and nonsterile **gloves** that should be changed after contact with contaminated secretions. Gloves alone would not be sufficient **(Choice D)**. In addition, a dedicated stethoscope and blood pressure cuff should be left in the patient's room.

(Choice A) Certain pathogens are transmitted by droplets (>5 microns) that remain suspended in air for limited periods only (eg, *Neisseria meningitides*, influenza, *Bordetella pertussis, Mycoplasma pneumoniae*, respiratory syncytial virus). In such cases, healthcare workers need to wear a simple facemask when within 6-10 feet of affected patients (droplet precautions). Gloves and gowns are not required.

(Choice B) Airborne precautions include an isolated room with negative pressure ventilation and a respirator mask with filtering capacity (eg, N95 mask) to avoid potential exposure to aerosolized particles (<5 microns) that can remain suspended in air for extended periods. Gloves and gowns are not needed. Airborne precautions are required for certain bacteria (eg, tuberculosis) and viruses (eg, varicella), but not for *C difficile*.

(Choices E and F) Sterile gloves generally are used for minor procedures or surgeries but are not required in patients with contact precautions.

This hospitalized patient's fever and diarrhea a few days after antibiotic initiation are concerning for ***Clostridium difficile*** infection. All hospitalized patients require **standard precautions**, including handwashing before and after patient contact, proper disposal of cleaning instruments and linens, and occasional use of gowns and gloves as required (eg, contact with body fluids).

However, cases of suspected or proven *C difficile* infection require additional **contact precautions**, including handwashing with **soap and water** (alcohol-based hand sanitizers do **not** kill the spores), **gown** for **any** patient contact, and nonsterile **gloves** that should be changed after contact with contaminated secretions. Gloves alone would not be sufficient **(Choice D)**. In addition, a dedicated stethoscope and blood pressure cuff should be left in the patient's room.

(Choice A) Certain pathogens are transmitted by droplets (>5 microns) that remain suspended in air for limited periods only (eg, *Neisseria meningitides*, influenza, *Bordetella pertussis, Mycoplasma pneumoniae*, respiratory syncytial virus). In such cases, healthcare workers need to wear a simple facemask when within 6-10 feet of affected patients (droplet precautions). Gloves and gowns are not required.

(Choice B) Airborne precautions include an isolated room with negative pressure ventilation and a respirator mask with filtering capacity (eg, N95 mask) to avoid potential exposure to aerosolized particles (<5 microns) that can remain suspended in air for extended periods. Gloves and gowns are not needed. Airborne precautions are required for certain bacteria (eg, tuberculosis) and viruses (eg, varicella), but not for *C difficile*.

(Choices E and F) Sterile gloves generally are used for minor procedures or surgeries but are not required in patients with contact precautions.

Educational objective:
Clostridium difficile requires additional contact precautions, including handwashing with soap and water, a gown for any patient contact, and nonsterile gloves that should be changed after contact with contaminated secretions. Alcohol-based hand sanitizers do not kill the bacterial spores.

References

- Environmental interventions to control Clostridium difficile.

Microbiology	Infectious Diseases	Clostridium difficile infection
Subject	System	Topic

Copyright © UWorld. All rights reserved.

1
2
3
4
5
6
7
8
9
10
11
12
13
14
15
16
17
18
19
20
21
22
23
24
25
26
27
28
29
30
31

A 54-year-old man comes to the emergency department due to fever, chills, and malaise over the past day. His other medical problems include recently diagnosed Hodgkin disease. Temperature is 39.4 C (103 F), blood pressure is 102/61 mm Hg, and pulse is 114/min. The patient appears ill. Blood cultures grow motile gram-positive rods that produce a very narrow zone of beta hemolysis on blood agar. The bacteria are also found to grow well at refrigerated temperature. Which of the following processes is most important for eliminating these bacteria from the body?

A. Cell-mediated immunity

B. Eosinophil action

C. Immunoglobulin secretion

D. Mast cell activation

E. Terminal complement cascade

Submit

A 54-year-old man comes to the emergency department due to fever, chills, and malaise over the past day. His other medical problems include recently diagnosed Hodgkin disease. Temperature is 39.4 C (103 F), blood pressure is 102/61 mm Hg, and pulse is 114/min. The patient appears ill. Blood cultures grow motile gram-positive rods that produce a very narrow zone of beta hemolysis on blood agar. The bacteria are also found to grow well at refrigerated temperature. Which of the following processes is most important for eliminating these bacteria from the body?

- ✓ A. Cell-mediated immunity (59%)
- B. Eosinophil action (0%)
- C. Immunoglobulin secretion (25%)
- D. Mast cell activation (1%)
- E. Terminal complement cascade (13%)

Omitted
Correct answer
A

59%
Answered correctly

02 secs
Time Spent

03/15/2020
Last Updated

Explanation

Common intracellular pathogens*	
	Chlamydia *Francisella tularensis* *Legionella* *Listeria monocytogenes*

Common intracellular pathogens*	
Bacteria	*Chlamydia* *Francisella tularensis* *Legionella* *Listeria monocytogenes* *Mycobacterium* *Neisseria gonorrhoeae* *Nocardia* *Rickettsia* *Salmonella typhi* *Yersinia pestis*
Fungi	*Cryptococcus neoformans* *Histoplasma capsulatum*
Protozoa	*Cryptosporidium parvum* *Leishmania* *Plasmodium* *Toxoplasma gondii* *Trypanosoma*

*Facultative intracellular pathogens are also included.

Listeria monocytogenes is a facultative intracellular, gram-positive rod that produces a **very narrow zone of beta hemolysis** on blood agar (similar to group B *Streptococcus* [*Streptococcus agalactiae*]). *Listeria* is immotile at body temperature but demonstrates **tumbling motility at room temperature**. The pathogen is also distinguished by an ability to multiply at refrigerated temperatures (**cold enrichment**), which is one reason *Listeria* is an important cause of foodborne illness (eg, refrigerated soft cheese, meats, unpasteurized milk).

The elimination of intracellular pathogens is largely reliant on the **cell-mediated immune response** as bacteria within cells are protected from

Listeria monocytogenes is a facultative intracellular, gram-positive rod that produces a **very narrow zone of beta hemolysis** on blood agar (similar to group B *Streptococcus* [*Streptococcus agalactiae*]). *Listeria* is immotile at body temperature but demonstrates **tumbling motility at room temperature**. The pathogen is also distinguished by an ability to multiply at refrigerated temperatures (**cold enrichment**), which is one reason *Listeria* is an important cause of foodborne illness (eg, refrigerated soft cheese, meats, unpasteurized milk).

The elimination of intracellular pathogens is largely reliant on the **cell-mediated immune response** as bacteria within cells are protected from circulating immune factors (eg, antibodies, complement). Cells infected by intracellular bacteria display bacterial protein fragments on their surface, which triggers cell lysis by **cytotoxic T cells**. This releases the organism from the protected intracellular space and exposes it to phagocytosis by macrophages. Although intracellular pathogens can often replicate within inactivated macrophages due to virulence factors that prevent phagolysosome destruction, cytotoxic T-cells release **interferon gamma** to **activate macrophages** leading to the formation of fully mature (acidified) phagolysosomes capable of destroying the bacteria.

As the elimination of *Listeria* is reliant on the cell mediated immune response, patients with **impaired cell-mediated** immunity are at greatest risk for invasive *Listeria* infections (eg, sepsis, meningitis), particularly those at the extremes of age (ie, neonates, elderly) or patients who are immunosuppressed (eg, Hodgkin disease, AIDS) or pregnant.

(Choice B) Eosinophils are a component of the innate immune system and are tasked primarily with the eradication of parasitic infections (eg, helminths). Eosinophils play a minor role in the phagocytosis and destruction of intracellular bacteria.

(Choice C) The humoral immune system secretes immunoglobulins and is largely tasked with eliminating extracellular infections such as *Streptococci* and *Staphylococci*. This system is not able to effectively target intracellular bacteria as immunoglobulins cannot access the intracellular space.

(Choice D) Mast cells contribute to defense against parasites and play an important role in allergic responses, particularly immediate hypersensitivity reactions; they do not confer immunity to intracellular pathogens.

(Choice E) The complement system is part of the innate immune system and aids in the opsonization and destruction of bacteria. The terminal complement components (eg, C5b-C9) create a membrane attack complex to lyse bacteria and are particularly important against *Neisseria* infections.

Educational objective:

Listeria monocytogenes is a facultative intracellular, gram-positive rod that produces a very narrow zone of beta hemolysis on blood agar, shows

As the elimination of *Listeria* is reliant on the cell mediated immune response, patients with **impaired cell-mediated** immunity are at greatest risk for invasive *Listeria* infections (eg, sepsis, meningitis), particularly those at the extremes of age (ie, neonates, elderly) or patients who are immunosuppressed (eg, Hodgkin disease, AIDS) or pregnant.

(Choice B) Eosinophils are a component of the innate immune system and are tasked primarily with the eradication of parasitic infections (eg, helminths). Eosinophils play a minor role in the phagocytosis and destruction of intracellular bacteria.

(Choice C) The humoral immune system secretes immunoglobulins and is largely tasked with eliminating extracellular infections such as *Streptococci* and *Staphylococci*. This system is not able to effectively target intracellular bacteria as immunoglobulins cannot access the intracellular space.

(Choice D) Mast cells contribute to defense against parasites and play an important role in allergic responses, particularly immediate hypersensitivity reactions; they do not confer immunity to intracellular pathogens.

(Choice E) The complement system is part of the innate immune system and aids in the opsonization and destruction of bacteria. The terminal complement components (eg, C5b-C9) create a membrane attack complex to lyse bacteria and are particularly important against *Neisseria* infections.

Educational objective:
Listeria monocytogenes is a facultative, intracellular, gram-positive rod that produces a very narrow zone of beta hemolysis on blood agar, shows tumbling motility at room temperature, and can grow at refrigerated temperatures. Intracellular pathogens such as *Listeria* are largely eliminated by the cell-mediated immune response (eg, T-cells, macrophages, cytokines). Patients with impaired cell-mediated immunity are at risk for invasive *Listeria* infections.

References

- Innate and adaptive immune responses to Listeria monocytogenes: a short overview. Page(s): PMC2042024

Microbiology	Infectious Diseases	Listeria
Subject	System	Topic

Copyright © UWorld. All rights reserved.

1
2
3
4
5
6
7
8
9
10
11
12
13
14
15
16
17
18
19
20
21
22
23
24
25
26
27
28
29
30
31

Microbiology researchers conduct a series of experiments to determine how pathogenicity is transmitted among different strains of *Streptococcus pneumoniae*. In the first experiment, they inject nonvirulent strain A into the peritoneal cavity of laboratory mice and observe no ill effects. In the second experiment, researchers subject virulent strain B to a detergent agent that kills and lyses the bacterial cells. They then inject the lysate into the peritoneal cavity of a new group of mice and again observe no ill effects. During a third experiment, they inject live strain A bacteria in combination with the killed strain B lysate, resulting in death of the mice. Which of the following genetic processes most likely accounts for the observed findings of these experiments?

A. Direct uptake of extracellular DNA

B. Phage-mediated DNA transfer

C. Pilus-mediated DNA transfer

D. Spontaneous DNA mutation

E. Transposon-mediated DNA transfer

Submit

1
2
3
4
5
6
7
8
9
10
11
12
13
14
15
16
17
18
19
20
21
22
23
24
25
26
27
28
29
30
31

Microbiology researchers conduct a series of experiments to determine how pathogenicity is transmitted among different strains of *Streptococcus pneumoniae*. In the first experiment, they inject nonvirulent strain A into the peritoneal cavity of laboratory mice and observe no ill effects. In the second experiment, researchers subject virulent strain B to a detergent agent that kills and lyses the bacterial cells. They then inject the lysate into the peritoneal cavity of a new group of mice and again observe no ill effects. During a third experiment, they inject live strain A bacteria in combination with the killed strain B lysate, resulting in death of the mice. Which of the following genetic processes most likely accounts for the observed findings of these experiments?

- ✓ A. Direct uptake of extracellular DNA (73%)
- B. Phage-mediated DNA transfer (11%)
- C. Pilus-mediated DNA transfer (8%)
- D. Spontaneous DNA mutation (0%)
- E. Transposon-mediated DNA transfer (5%)

Omitted
Correct answer
A

73%
Answered correctly

01 sec
Time Spent

04/26/2020
Last Updated

Explanation

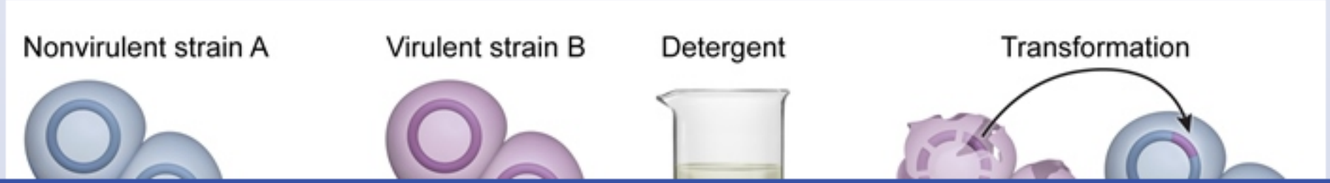

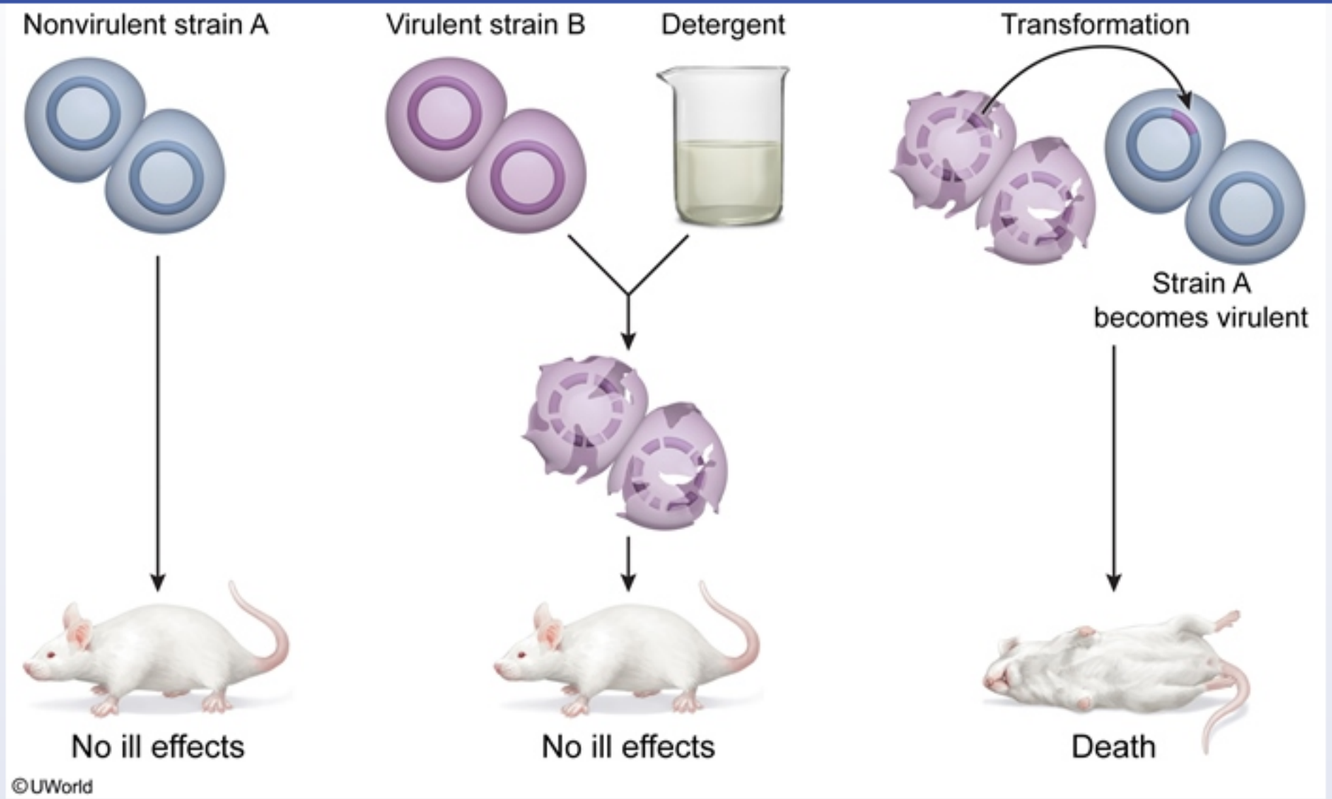

Certain strains of *Streptococcus pneumoniae* express capsular polysaccharides that inhibit phagocytosis, making it a successful pathogen. Strains lacking the capsule are not pathogenic; however, *S pneumoniae* is able to obtain new genetic material from the environment that is released following the death and lysis of neighboring bacterial cells. This process, known as transformation, allows the bacterium to **take up exogenous DNA** fragments, integrate the DNA into its genome, and express the encoded proteins. Through this method, nonvirulent strains of *S pneumoniae* that do not form a capsule can acquire the genes that code for the capsule and therefore **gain virulence**.

Bacteria that have the innate capacity to undergo transformation are said to be naturally competent and include *Haemophilus*, *Streptococcus*, *Bacillus*, and *Neisseria* species.

(Choice B) In transduction, a bacteriophage (virus) transfers DNA from one bacterial cell to another. While replicating within a host bacterium, a

©UWorld

Certain strains of *Streptococcus pneumoniae* express capsular polysaccharides that inhibit phagocytosis, making it a successful pathogen. Strains lacking the capsule are not pathogenic; however, *S pneumoniae* is able to obtain new genetic material from the environment that is released following the death and lysis of neighboring bacterial cells. This process, known as transformation, allows the bacterium to **take up exogenous DNA** fragments, integrate the DNA into its genome, and express the encoded proteins. Through this method, nonvirulent strains of *S pneumoniae* that do not form a capsule can acquire the genes that code for the capsule and therefore **gain virulence**.

Bacteria that have the innate capacity to undergo transformation are said to be naturally competent and include *Haemophilus*, *Streptococcus*, *Bacillus*, and *Neisseria* species.

(Choice B) In transduction, a bacteriophage (virus) transfers DNA from one bacterial cell to another. While replicating within a host bacterium, a bacteriophage may accidentally incorporate host bacterial DNA into the phage particle. Once released, it can then transfer DNA from the previous host into a newly infected bacterium. By this mechanism, bacteria can acquire genes for virulence and antibiotic resistance.

(Choice C) Conjugation is a form of one-way DNA transfer performed by bacteria carrying a plasmid with the fertility (F) factor. The process begins with the donating bacterium producing a sex pilus, which then forms a direct connection with the receiving bacterium. Next, the donating bacterium transfers a single DNA strand containing the F factor to the recipient organism, after which, complementary DNA strands are synthesized.

(Choice D) Spontaneous or induced mutations change the nucleotide sequence of a gene, potentially altering the amino acid sequence of the protein product. Through this mechanism, bacteria form novel proteins with potentially useful functions to aid with survival.

(Choice E) Transposons are mobile genetic elements that can mediate DNA transfer from plasmids to a bacterial chromosome, move genetic material from one position to another along a bacterial chromosome, or transfer genes from a bacterial chromosome to a plasmid. The location of a gene in the genome is important as it determines its proximity to promoter or suppressor regions.

Educational objective:
Streptococcus pneumoniae is able to undergo transformation, which allows the bacterium to take up exogenous DNA fragments and express the encoded proteins. Through this method, strains of *S pneumoniae* that do not form a capsule can acquire the genes that code for the capsule and therefore gain virulence.

©UWorld

Exhibit Display

Transformation

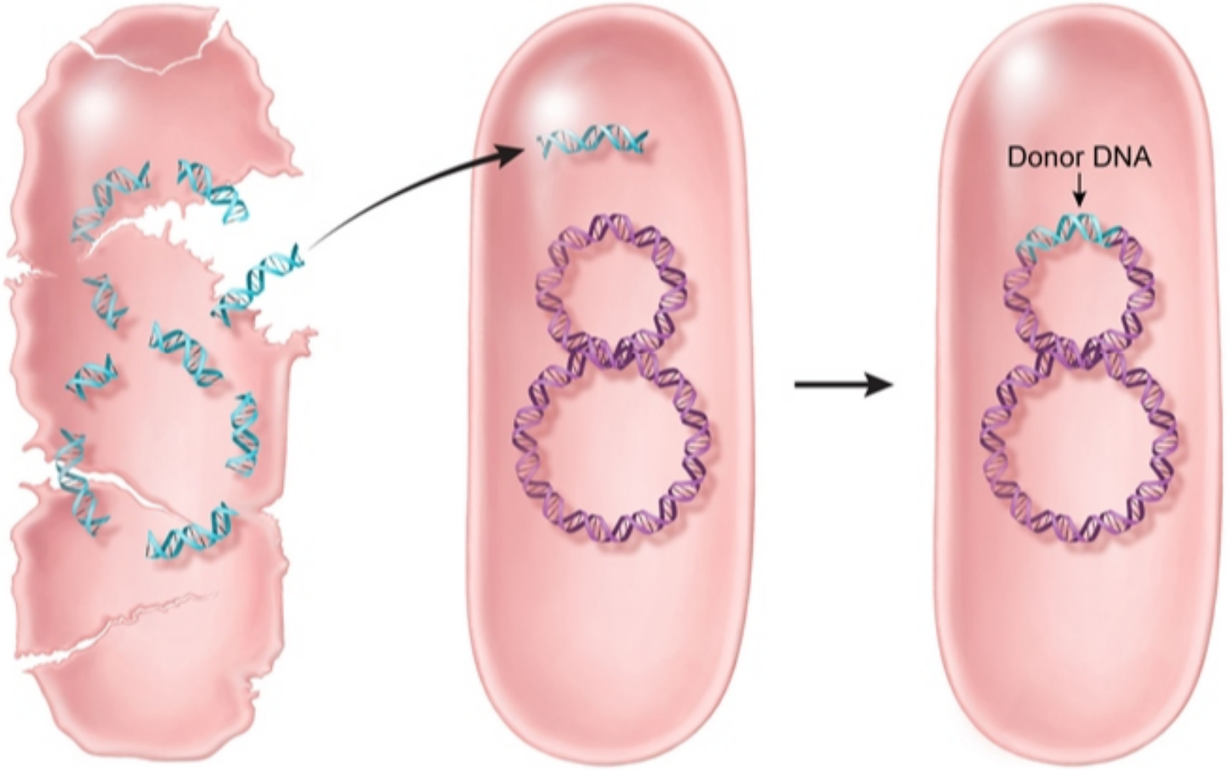

Cell lysis & release of DNA fragments

Uptake by naturally competent bacteria

Integration into host genome

Zoom In | Zoom Out | Reset | Add To New Card | Existing Card

exogenous DNA fragments, integrate the DNA into its genome, and express the encoded proteins. Through this method, nonvirulent strains of *S*

Exhibit Display

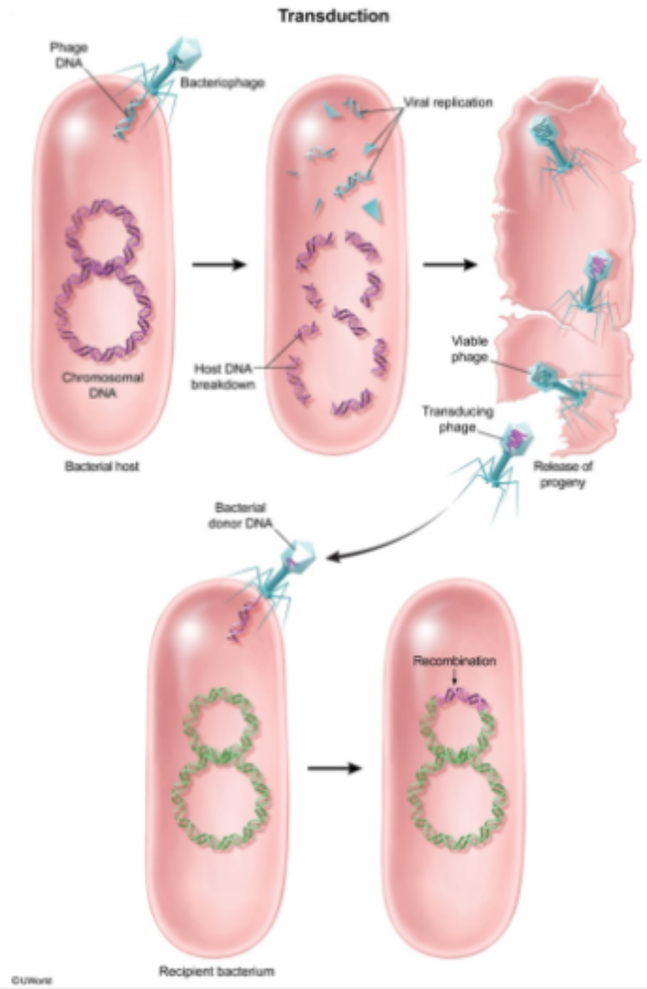

Zoom In | Zoom Out | Reset | Add To New Card | Existing Card

exogenous DNA fragments, integrate the DNA into its genome, and express the encoded proteins. Through this method, nonvirulent strains of *S*

Exhibit Display

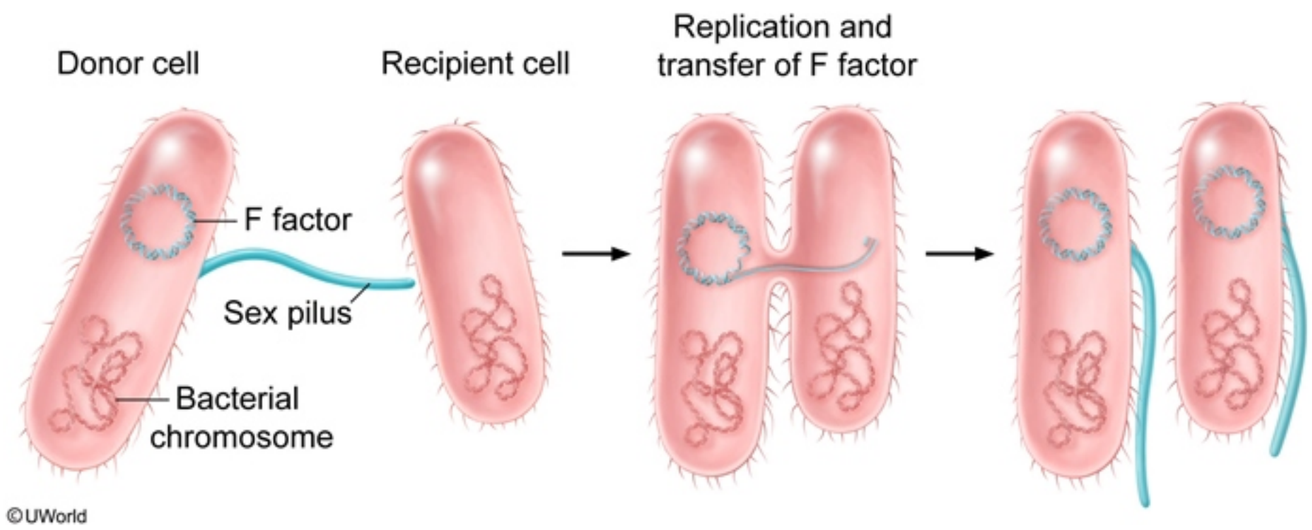

Zoom In | Zoom Out | Reset | Add To New Card | Existing Card

1
2
3
4
5
6
7
8
9
10
11
12
13
14
15
16
17
18
19
20
21
22
23
24
25
26
27
28
29
30
31

A 34-year-old man comes to the office due to a painless penile ulcer, which he first noticed 3 days ago. He had unprotected sexual intercourse with a new partner a few weeks ago. The patient has no significant medical history and takes no medications. Temperature is 37.1 C (98.8 F). Examination reveals a 2-cm nontender ulcer close to the glans penis with a raised, indurated margin and a clean base. There are no surrounding lesions or vesicles. There are several bilateral enlarged inguinal lymph nodes, which are firm, nontender, and rubbery. Physical examination is otherwise unremarkable. Rapid plasma reagin and HIV testing are negative. Infection with which of the following is the most likely cause of this patient's symptoms?

A. *Chlamydia trachomatis* (L serovars)

B. *Haemophilus ducreyi*

C. Herpes simplex virus

D. *Neisseria gonorrhoeae*

E. *Treponema pallidum*

Submit

A 34-year-old man comes to the office due to a painless penile ulcer, which he first noticed 3 days ago. He had unprotected sexual intercourse with a new partner a few weeks ago. The patient has no significant medical history and takes no medications. Temperature is 37.1 C (98.8 F). Examination reveals a 2-cm nontender ulcer close to the glans penis with a raised, indurated margin and a clean base. There are no surrounding lesions or vesicles. There are several bilateral enlarged inguinal lymph nodes, which are firm, nontender, and rubbery. Physical examination is otherwise unremarkable. Rapid plasma reagin and HIV testing are negative. Infection with which of the following is the most likely cause of this patient's symptoms?

A. *Chlamydia trachomatis* (L serovars) (28%)

B. *Haemophilus ducreyi* (6%)

C. Herpes simplex virus (3%)

D. *Neisseria gonorrhoeae* (1%)

✓ E. *Treponema pallidum* (59%)

Omitted
Correct answer
E

59%
Answered correctly

02 secs
Time Spent

02/14/2020
Last Updated

Explanation

Genital ulcer disease				
	Syphilis	Genital herpes	Chancroid	Granuloma inguinale (donovanosis)

A 34-year-old man comes to the office due to a painless penile ulcer, which he first noticed 3 days ago. He had unprotected sexual intercourse with a new partner a few weeks ago. The patient has no significant medical history and takes no medications. Temperature is 37.1 C (98.8 F). Examination reveals a 2-cm nontender ulcer close to the glans penis with a raised, indurated margin and a clean base. There are no surrounding lesions or vesicles. There are several bilateral enlarged inguinal lymph nodes, which are firm, nontender, and rubbery. Physical examination is otherwise unremarkable. Rapid plasma reagin and HIV testing are negative. Infection with which of the following is the most likely cause of this patient's symptoms?

A. *Chlamydia trachomatis* (L serovars) (28%)

B. *Haemophilus ducreyi* (6%)

C. Herpes simplex virus (3%)

D. *Neisseria gonorrhoeae* (1%)

✓ E. *Treponema pallidum* (59%)

Omitted
Correct answer
E

59%
Answered correctly

02 secs
Time Spent

02/14/2020
Last Updated

Explanation

Genital ulcer disease				
	Syphilis	Genital herpes	Chancroid	Granuloma inguinale (donovanosis)

Genital ulcer disease				
	Syphilis	**Genital herpes**	**Chancroid**	**Granuloma inguinale (donovanosis)**
Causative agent	*Treponema pallidum*	Herpes simplex virus	*Haemophilus ducreyi*	*Klebsiella granulomatis*
Description	Single, **painless** ulcer at inoculation site with heaped-up borders & clean base	Multiple, **painful superficial vesicles** or **ulcerations** with erythematous base	**Deep**, **purulent**, painful ulcers with matted/**suppurative** lymphadenitis	**Painless**, progressive, red serpiginous ulcerative lesions **without** lymphadenopathy
Diagnostic tests	• VDRL/RPR • Dark-field microscopy	• PCR • Tzanck smear	• Gram stain & culture • PCR	• Gram stain & culture (difficult) • Biopsy (Donovan bodies)

PCR = polymerase chain reaction; **RPR** = rapid plasma reagin; **VDRL** = Venereal Disease Research Laboratory.

This patient developed a **genital ulcer** a few weeks after unprotected intercourse, raising suspicion for a sexually transmitted infection. A wide range of pathogens can cause genital ulcers, but a **solitary**, **painless ulcer** with heaped-up borders and a clean base usually indicates **primary syphilis** (syphilitic chancre). Syphilis is caused by ***Treponema pallidum***, a gram-negative spirochete that cannot be cultured and cannot be detected on Gram stain due to its small size.

The diagnosis of syphilis relies primarily on nontreponemal (eg, rapid plasma reagin, VDRL) and treponemal (eg, fluorescent treponemal antibody absorption) serologic testing. However, because humoral antibody response often takes 4 weeks to develop, **false-negative serologic testing** is common early in the course of disease. Nontreponemal tests are particularly susceptible to initial false-negative results (as in this patient); treponemal tests are more sensitive in early infection and are often used preferentially in this setting.

Although not widely available, the diagnostic gold standard for syphilis is to directly visualize the organism in tissue scrapings from a cutaneous

This patient developed a **genital ulcer** a few weeks after unprotected intercourse, raising suspicion for a sexually transmitted infection. A wide range of pathogens can cause genital ulcers, but a **solitary**, **painless ulcer** with heaped-up borders and a clean base usually indicates **primary syphilis** (syphilitic chancre). Syphilis is caused by ***Treponema pallidum***, a gram-negative spirochete that cannot be cultured and cannot be detected on Gram stain due to its small size.

The diagnosis of syphilis relies primarily on nontreponemal (eg, rapid plasma reagin, VDRL) and treponemal (eg, fluorescent treponemal antibody absorption) serologic testing. However, because humoral antibody response often takes 4 weeks to develop, **false-negative serologic testing** is common early in the course of disease. Nontreponemal tests are particularly susceptible to initial false-negative results (as in this patient); treponemal tests are more sensitive in early infection and are often used preferentially in this setting.

Although not widely available, the diagnostic gold standard for syphilis is to directly visualize the organism in tissue scrapings from a cutaneous lesion (eg, chancre). This can involve fluorescent antibody testing or **dark-field microscopy**, which will show **motile**, **helical spirochetes**.

(Choice A) L serovars of *Chlamydia trachomatis* cause lymphogranuloma venereum. Although initial infection is associated with a painless genital ulcer, patients primarily present after the disease has spread to the regional lymph nodes, which results in painful lymphadenitis. This disease is very rare in the United States and occurs mostly in tropical and subtropical regions.

(Choice B) *Haemophilus ducreyi* is a small gram-negative rod that causes chancroid, a sexually transmitted infection characterized by painful (not painless) genital ulcers with an erythematous base. Lesions typically begin as papules or pustules and evolve into an ulcer. More than one lesion is often present.

(Choice C) Herpes simplex virus usually causes multiple, bilateral, painful, ulcerating lesions. Initial infections are frequently associated with systemic symptoms (eg, fever, headache, myalgia) and tender lymphadenopathy.

(Choice D) *Neisseria gonorrhoeae*, a gram-negative diplococcus, is a leading cause of cervicitis, urethritis, and pelvic inflammatory disease. Infected patients usually have copious purulent discharge from the urethra; ulcerative genital lesions are not a feature of this organism.

Educational objective:
Patients with early syphilis (eg, chancre) often have false-negative initial serologic testing. Direct visualization of the organism (*Treponema pallidum*) by dark-field microscopy or fluorescent antibody testing is the gold standard for diagnosis but is not widely available.

The diagnosis of syphilis relies primarily on nontreponemal (eg, rapid plasma reagin, VDRL) and treponemal (eg, fluorescent treponemal antibody absorption) serologic testing. However, because humoral antibody response often takes 4 weeks to develop, **false-negative serologic testing** is common early in the course of disease. Nontreponemal tests are particularly susceptible to initial false-negative results (as in this patient); treponemal tests are more sensitive in early infection and are often used preferentially in this setting.

Although not widely available, the diagnostic gold standard for syphilis is to directly visualize the organism in tissue scrapings from a cutaneous lesion (eg, chancre). This can involve fluorescent antibody testing or **dark-field microscopy**, which will show **motile**, **helical spirochetes**.

(Choice A) L serovars of *Chlamydia trachomatis* cause lymphogranuloma venereum. Although initial infection is associated with a painless genital ulcer, patients primarily present after the disease has spread to the regional lymph nodes, which results in painful lymphadenitis. This disease is very rare in the United States and occurs mostly in tropical and subtropical regions.

(Choice B) *Haemophilus ducreyi* is a small gram-negative rod that causes chancroid, a sexually transmitted infection characterized by painful (not painless) genital ulcers with an erythematous base. Lesions typically begin as papules or pustules and evolve into an ulcer. More than one lesion is often present.

(Choice C) Herpes simplex virus usually causes multiple, bilateral, painful, ulcerating lesions. Initial infections are frequently associated with systemic symptoms (eg, fever, headache, myalgia) and tender lymphadenopathy.

(Choice D) *Neisseria gonorrhoeae*, a gram-negative diplococcus, is a leading cause of cervicitis, urethritis, and pelvic inflammatory disease. Infected patients usually have copious purulent discharge from the urethra; ulcerative genital lesions are not a feature of this organism.

Educational objective:
Patients with early syphilis (eg, chancre) often have false-negative initial serologic testing. Direct visualization of the organism (*Treponema pallidum*) by dark-field microscopy or fluorescent antibody testing is the gold standard for diagnosis but is not widely available.

Microbiology	Infectious Diseases	Syphilis
Subject	System	Topic

Copyright © UWorld. All rights reserved.

1
2
3
4
5
6
7
8
9
10
11
12
13
14
15
16
17
18
19
20
21
22
23
24
25
26
27
28
29
30
31

A 35-year-old man is found to have elevated alanine aminotransferase and aspartate aminotransferase levels. He has no abdominal pain, nausea, or vomiting. The patient has used intravenous drugs in the past but denies significant alcohol use. His past medical history is negative for blood transfusions or excessive acetaminophen use. Physical examination findings are normal. Laboratory studies show high titers of IgG directed against the hepatitis C envelope protein. Which of the following is the most likely reason that these antibodies do not confer effective immunity against the infection?

A. Envelope proteins are lost after recurrent viral replication

B. Envelope proteins are sequestered within hepatocytes

C. Envelope proteins have low immunogenicity

D. Envelope proteins have variations in their antigenic structure

E. The antibodies do not have neutralizing properties

Submit

1
2
3
4
5
6
7
8
9
10
11
12
13
14
15
16
17
18
19
20
21
22
23
24
25
26
27
28
29
30
31

A 35-year-old man is found to have elevated alanine aminotransferase and aspartate aminotransferase levels. He has no abdominal pain, nausea, or vomiting. The patient has used intravenous drugs in the past but denies significant alcohol use. His past medical history is negative for blood transfusions or excessive acetaminophen use. Physical examination findings are normal. Laboratory studies show high titers of IgG directed against the hepatitis C envelope protein. Which of the following is the most likely reason that these antibodies do not confer effective immunity against the infection?

A. Envelope proteins are lost after recurrent viral replication (5%)

B. Envelope proteins are sequestered within hepatocytes (10%)

C. Envelope proteins have low immunogenicity (10%)

✓ D. Envelope proteins have variations in their antigenic structure (68%)

E. The antibodies do not have neutralizing properties (5%)

Omitted
Correct answer
D

68%
Answered correctly

02 secs
Time Spent

03/09/2020
Last Updated

Explanation

1
2
3
4
5
6
7
8
9
10
11
12
13
14
15
16
17
18
19
20
21
22
23
24
25
26
27
28
29
30
31

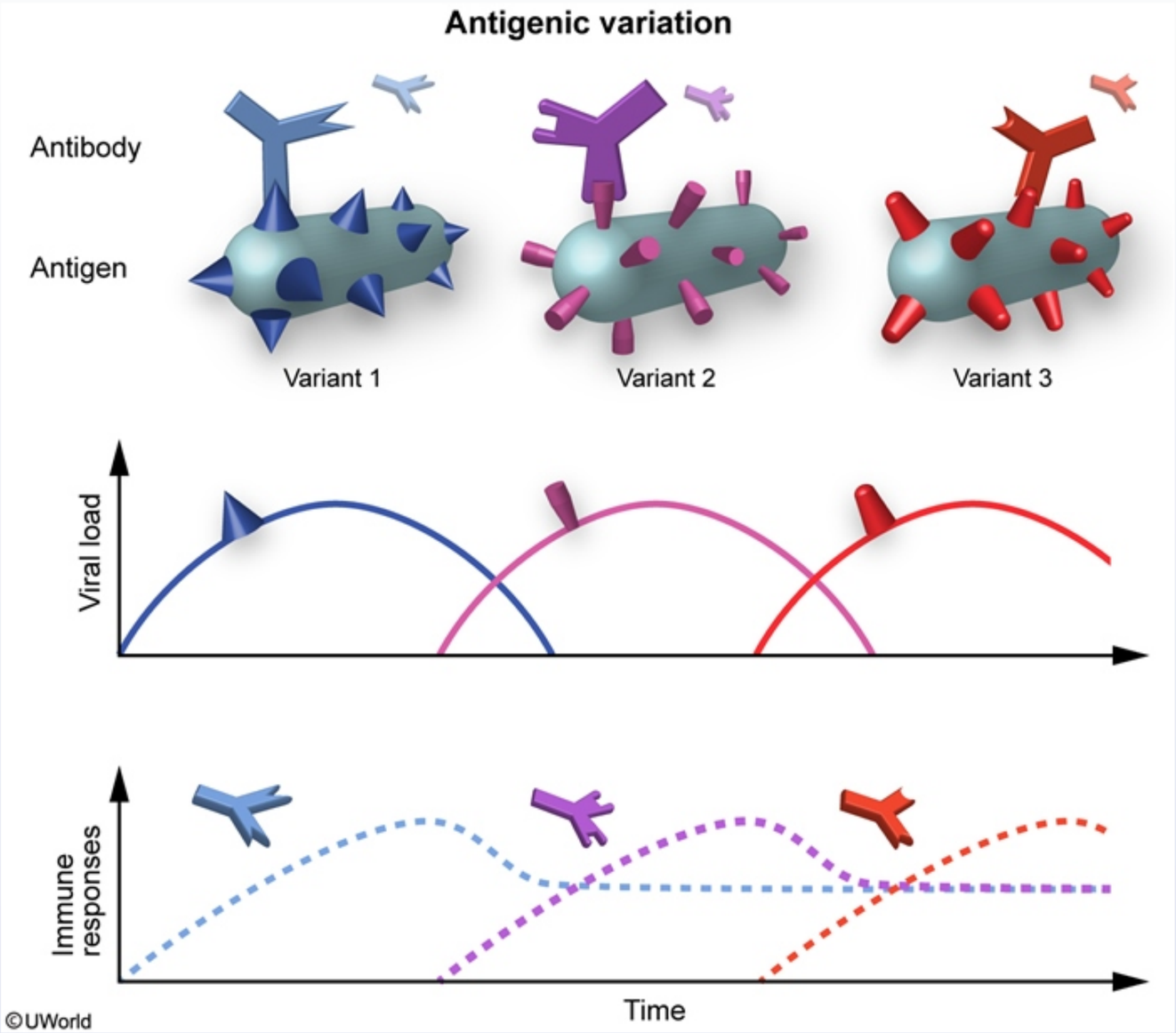

Hepatitis C virus (HCV) has 6 or more genotypes and multiple subtypes that differ in genomic composition by as much as 30%-35%. This is

1
2
3
4
5
6
7
8
9
10
11
12
13
14
15
16
17
18
19
20
21
22
23
24
25
26
27
28
29
30
31

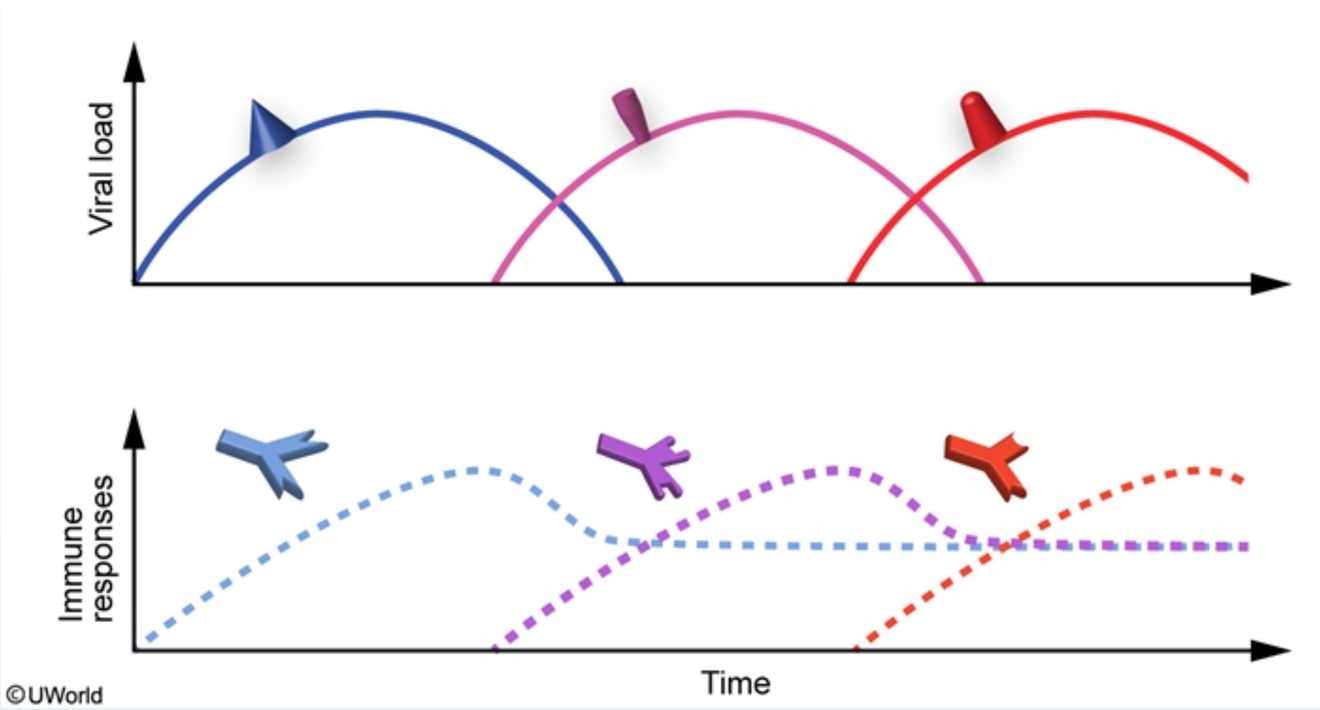

Hepatitis C virus (HCV) has 6 or more genotypes and multiple subtypes that differ in genomic composition by as much as 30%-35%. This is largely due to the fact that the virion-encoded **RNA-dependent RNA polymerase** has **no proofreading** 3' → 5' exonuclease activity, which results in many errors during replication.

Although most patients are infected with a single genotype, the high mutation rate leads to the development of distinct quasispecies within infected individuals over time. These variant strains differ primarily at **hypervariable genomic regions**, such as those found in the sequences coding for its **envelope glycoproteins**. The continuous generation of novel envelope glycoproteins prevents infected individuals from mounting an effective immune response. As production of host antibodies against a quasispecies commences, that strain dies off and new ones take its place. The tremendous antigenic variety of HCV has significantly slowed efforts to develop an effective vaccine.

(Choices A and B) The envelope proteins of HCV are not lost after recurrent viral replication nor are they sequestered within hepatocytes. These proteins are necessary for viral infectivity as they mediate membrane adhesion and fusion with host hepatocytes.

©UWorld

Hepatitis C virus (HCV) has 6 or more genotypes and multiple subtypes that differ in genomic composition by as much as 30%-35%. This is largely due to the fact that the virion-encoded **RNA-dependent RNA polymerase** has **no proofreading** 3' → 5' exonuclease activity, which results in many errors during replication.

Although most patients are infected with a single genotype, the high mutation rate leads to the development of distinct quasispecies within infected individuals over time. These variant strains differ primarily at **hypervariable genomic regions**, such as those found in the sequences coding for its **envelope glycoproteins**. The continuous generation of novel envelope glycoproteins prevents infected individuals from mounting an effective immune response. As production of host antibodies against a quasispecies commences, that strain dies off and new ones take its place. The tremendous antigenic variety of HCV has significantly slowed efforts to develop an effective vaccine.

(Choices A and B) The envelope proteins of HCV are not lost after recurrent viral replication nor are they sequestered within hepatocytes. These proteins are necessary for viral infectivity as they mediate membrane adhesion and fusion with host hepatocytes.

(Choice C) Like most foreign (nonself) proteins, the envelope proteins of HCV are highly immunogenic.

(Choice E) Host antibodies against HCV have neutralizing properties and are effective in eliminating more established hepatitis C quasispecies. It is the constantly emerging mutant strains that pose the greatest challenge to the host immune system.

Educational objective:
Genetic variations created during hepatitis C virus (HCV) replication result in marked variety in the antigenic structure of HCV envelope proteins. The production of host antibodies lags behind that of new mutant HCV strains, preventing infected individuals from mounting an effective immune response.

References

- Virus-neutralizing antibodies to hepatitis C virus.
- Hepatitis C virus hypervariable region 1 modulates receptor interactions, conceals the CD81 binding site, and protects conserved neutralizing epitopes.

Microbiology	Infectious Diseases	Hepatitis c
Subject	System	Topic

1
2
3
4
5
6
7
8
9
10
11
12
13
14
15
16
17
18
19
20
21
22
23
24
25
26
27
28
29
30
31

A 23-year-old man comes to the office due to dysuria and a small amount of urethral discharge. He has no medical problems, takes no medications, and has no known allergies. Temperature is 37.1 C (98.8 F). On genitourinary examination, urethral discharge is present. Under the microscope, the discharge is neutrophil-rich with intracellular gram-negative diplococci. A single intramuscular injection of ceftriaxone is administered. A week later, the patient returns to the office because his symptoms have not improved. Which of the following is most likely to improve his condition?

A. Intramuscular penicillin

B. Oral azithromycin

C. Oral fluconazole

D. Oral metronidazole

E. Repeat intramuscular ceftriaxone

Submit

A 23-year-old man comes to the office due to dysuria and a small amount of urethral discharge. He has no medical problems, takes no medications, and has no known allergies. Temperature is 37.1 C (98.8 F). On genitourinary examination, urethral discharge is present. Under the microscope, the discharge is neutrophil-rich with intracellular gram-negative diplococci. A single intramuscular injection of ceftriaxone is administered. A week later, the patient returns to the office because his symptoms have not improved. Which of the following is most likely to improve his condition?

- A. Intramuscular penicillin (4%)
- ✓ B. Oral azithromycin (85%)
- C. Oral fluconazole (0%)
- D. Oral metronidazole (4%)
- E. Repeat intramuscular ceftriaxone (4%)

Omitted
Correct answer
B

85%
Answered correctly

02 secs
Time Spent

06/02/2020
Last Updated

Explanation

This patient has **infectious urethritis**, which, in young men, is usually a sexually transmitted infection. Sexually transmitted urethritis is classified as gonococcal (due to *Neisseria gonorrhoeae*) or nongonococcal (most commonly caused by *Chlamydia trachomatis*). With *N gonorrhoeae* infection, gram-negative intracellular diplococci are likely to be seen in urethral exudate; in contrast, *C trachomatis* is an obligate intracellular organism that does not stain well with Gram stain.

A single intramuscular dose of ceftriaxone can treat gonococcal urethritis; however, as coinfection with *C trachomatis* (not seen on microscopy) is

1
2
3
4
5
6
7
8
9
10
11
12
13
14
15
16
17
18
19
20
21
22
23
24
25
26
27
28
29
30
31

Explanation

This patient has **infectious urethritis**, which, in young men, is usually a sexually transmitted infection. Sexually transmitted urethritis is classified as gonococcal (due to *Neisseria gonorrhoeae*) or nongonococcal (most commonly caused by *Chlamydia trachomatis*). With *N gonorrhoeae* infection, gram-negative intracellular diplococci are likely to be seen in urethral exudate; in contrast, *C trachomatis* is an obligate intracellular organism that does not stain well with Gram stain.

A single intramuscular dose of ceftriaxone can treat gonococcal urethritis; however, as coinfection with *C trachomatis* (not seen on microscopy) is common, it is recommended that patients with gonococcal urethritis also be treated for nongonococcal urethritis. This patient's failure to improve following ceftriaxone therapy (effective against *N gonorrhoeae*) suggests *C trachomatis* coinfection. **Doxycycline** and **macrolide** antibiotics (eg, erythromycin, azithromycin) are effective against *C trachomatis*. *C trachomatis* has an unusual peptidoglycan cell wall. As a result, beta-lactam-based antibiotics such as penicillins and cephalosporins are not effective **(Choices A and E)**.

(Choice C) Fluconazole is a triazole-class antifungal used to treat candidiasis, cryptococcosis, histoplasmosis, blastomycosis, and coccidioidomycosis.

(Choice D) Metronidazole is classically used to treat infections caused by anaerobic bacteria or protozoa. It has no activity against *C trachomatis*.

Educational objective:
Urethritis in a young man is most likely to be due to *Neisseria gonorrhoeae* or *Chlamydia trachomatis*, both of which cause dysuria and mucopurulent urethral discharge. The standard treatment for suspected gonococcal urethritis presumes infection by both organisms. Therefore, ceftriaxone is given for *N gonorrhoeae*, and doxycycline or azithromycin is given for *C trachomatis*.

Microbiology	Infectious Diseases	Urethritis
Subject	System	Topic

Copyright © UWorld. All rights reserved.

1
2
3
4
5
6
7
8
9
10
11
12
13
14
15
16
17
18
19
20
21
22
23
24
25
26
27
28
29
30
31

The following vignette applies to the next **2** items. The items in the set must be answered in sequential order. Once you click **Proceed to Next Item**, you will not be able to add or change an answer.

An isolate of *Streptococcus pneumoniae* from a patient with meningitis is incubated with low-dose radiolabeled ceftriaxone and then subjected to protein electrophoresis. Five distinct bands are detected by radioautography.

Item 1 of 2

These bands most likely represent radiolabeled ceftriaxone that is bound to which of the following?

A. Cell wall glycoproteins

B. DNA replication proteins

C. Porins

D. Ribosomal proteins

E. Transpeptidases

Submit

1
2
3
4
5
6
7
8
9
10
11
12
13
14
15
16
17
18
19
20
21
22
23
24
25
26
27
28
29
30
31

The following vignette applies to the next **2** items. The items in the set must be answered in sequential order. Once you click **Proceed to Next Item**, you will not be able to add or change an answer.

An isolate of *Streptococcus pneumoniae* from a patient with meningitis is incubated with low-dose radiolabeled ceftriaxone and then subjected to protein electrophoresis. Five distinct bands are detected by radioautography.

Item 1 of 2

These bands most likely represent radiolabeled ceftriaxone that is bound to which of the following?

A. Cell wall glycoproteins (50%)
B. DNA replication proteins (3%)
C. Porins (1%)
D. Ribosomal proteins (6%)
✓ E. Transpeptidases (38%)

Omitted
Correct answer
E

38%
Answered correctly

02 secs
Time Spent

04/27/2020
Last Updated

Explanation

Penicillins and cephalosporins function by **irreversibly** binding to penicillin-binding proteins. Transpeptidases are one form of penicillin-binding protein that function to cross-link peptidoglycan in the bacterial cell wall. Inhibition of transpeptidase (which occurs with the use of the cephalosporin ceftriaxone) leads to cell wall instability and bacteriolysis. Many bacterial species synthesize multiple different penicillin-binding

1
2
3
4
5
6
7
8
9
10
11
12
13
14
15
16
17
18
19
20
21
22
23
24
25
26
27
28
29
30
31

Omitted
Correct answer
E

38%
Answered correctly

02 secs
Time Spent

04/27/2020
Last Updated

Explanation

Penicillins and cephalosporins function by **irreversibly** binding to penicillin-binding proteins. Transpeptidases are one form of penicillin-binding protein that function to cross-link peptidoglycan in the bacterial cell wall. Inhibition of transpeptidase (which occurs with the use of the cephalosporin ceftriaxone) leads to cell wall instability and bacteriolysis. Many bacterial species synthesize multiple different penicillin-binding proteins; the laboratory study described in this question stem identifies 5 such proteins that are produced by this isolate of *Streptococcus pneumoniae*.

(Choice A) Vancomycin binds to the terminal D-alanine residues of cell wall glycoproteins and prevents transpeptidases from forming cross-links.

(Choice B) Fluoroquinolones interfere with DNA replication by binding to proteins such as DNA gyrase.

(Choice C) Porins are utilized by bacterial organisms as a means of controlling diffusion of small to medium-sized metabolites. Antibiotic resistance can develop through porin mutations that prevent antibiotic diffusion through the outer membrane of gram-negative bacteria. No known antibiotics function by binding to porins.

(Choice D) Ribosomal proteins are bound by multiple antibiotics including macrolides, tetracyclines, and others.

Educational objective:
Penicillins and cephalosporins function by irreversibly binding to penicillin-binding proteins such as transpeptidases.

Microbiology	Infectious Diseases	Cephalosporins
Subject	System	Topic

Copyright © UWorld. All rights reserved.

Item 2 of 2

Another isolate of *Streptococcus pneumoniae* from a patient with meningitis is also incubated with low-dose radioactive ceftriaxone and subjected to protein electrophoresis. Only two bands are detected using radioautography. Which of the following best explains the observed finding?

- A. Action of beta-lactamases (37%)
- ✓ B. Change in protein structure (52%)
- C. Salvage metabolic pathway (0%)
- D. Transmembranous efflux pumps (7%)
- E. Upregulation of protein synthesis (1%)

Omitted
Correct answer
B

52%
Answered correctly

05 secs
Time Spent

05/09/2020
Last Updated

Explanation

The isolate of *S. pneumoniae* in the prior question had five penicillin-binding proteins identified, whereas the isolate in the current question only has two. This indicates that three of the penicillin-binding proteins have been altered in such a way that inhibits the binding of ceftriaxone. Structural changes in penicillin-binding proteins that prevent ceftriaxone from binding is one mechanism for ceftriaxone resistance.

(Choice A) Beta-lactamases function to degrade penicillin and cephalosporins. Production of a beta-lactamase would prevent ceftriaxone from being able to bind to the penicillin-binding proteins. Because ceftriaxone is so much smaller than the penicillin-binding proteins, unbound ceftriaxone would likely accumulate at one of the electrodes. This would lead to no bands being found within the electrophoresis area.

1
2
3
4
5
6
7
8
9
10
11
12
13
14
15
16
17
18
19
20
21
22
23
24
25
26
27
28
29
30
31

Correct answer
B

Answered correctly

Time Spent

Last Updated

Explanation

The isolate of *S. pneumoniae* in the prior question had five penicillin-binding proteins identified, whereas the isolate in the current question only has two. This indicates that three of the penicillin-binding proteins have been altered in such a way that inhibits the binding of ceftriaxone. Structural changes in penicillin-binding proteins that prevent ceftriaxone from binding is one mechanism for ceftriaxone resistance.

(Choice A) Beta-lactamases function to degrade penicillin and cephalosporins. Production of a beta-lactamase would prevent ceftriaxone from being able to bind to the penicillin-binding proteins. Because ceftriaxone is so much smaller than the penicillin-binding proteins, unbound ceftriaxone would likely accumulate at one of the electrodes. This would lead to no bands being found within the electrophoresis area.

(Choice C) A salvage metabolic pathway can restore metabolic function that would otherwise be inhibited by an antibiotic such as trimethoprim or sulfamethoxazole.

(Choice D) Transmembranous efflux pumps confer resistance to antibiotics that require entry into the cell to function (e.g., tetracyclines and macrolides). However, penicillins and cephalosporins function outside of the bacterial cell at the peptidoglycan cell wall.

(Choice E) Upregulation of protein synthesis can occur to overcome the effect of an antibiotic that binds to and irreversibly inhibits the action of that protein. However, if this were the mechanism for resistance, five bands would still be identified on the radioautography test.

Educational objective:
A change in the structure of penicillin-binding proteins that prevents cephalosporin binding is one mechanism of bacterial resistance to cephalosporins.

Microbiology	Infectious Diseases	Antibiotic resistance
Subject	System	Topic

Copyright © UWorld. All rights reserved.

1
2
3
4
5
6
7
8
9
10
11
12
13
14
15
16
17
18
19
20
21
22
23
24
25
26
27
28
29
30
31

A 22-year-old man with fever and joint pain is found to have atypical lymphocytes on his blood smear. Further evaluation shows that his condition is caused by an enveloped virus containing partially double-stranded circular DNA. An enzyme packed in its virion has RNA-dependent DNA-polymerase activity. This patient is most likely infected with which of the following viruses?

- A. Coxsackie virus
- B. Cytomegalovirus
- C. Epstein-Barr virus
- D. Hepatitis B virus
- E. Human immunodeficiency virus
- F. Parvovirus B19

Submit

1
2
3
4
5
6
7
8
9
10
11
12
13
14
15
16
17
18
19
20
21
22
23
24
25
26
27
28
29
30
31

A 22-year-old man with fever and joint pain is found to have atypical lymphocytes on his blood smear. Further evaluation shows that his condition is caused by an enveloped virus containing partially double-stranded circular DNA. An enzyme packed in its virion has RNA-dependent DNA-polymerase activity. This patient is most likely infected with which of the following viruses?

A. Coxsackie virus (2%)
B. Cytomegalovirus (5%)
C. Epstein-Barr virus (23%)
✓ D. Hepatitis B virus (55%)
E. Human immunodeficiency virus (7%)
F. Parvovirus B19 (5%)

Omitted
Correct answer
D

55%
Answered correctly

01 sec
Time Spent

06/04/2020
Last Updated

Explanation

1
2
3
4
5
6
7
8
9
10
11
12
13
14
15
16
17
18
19
20
21
22
23
24
25
26
27
28
29
30
31

Lifecycle of Hepatitis B

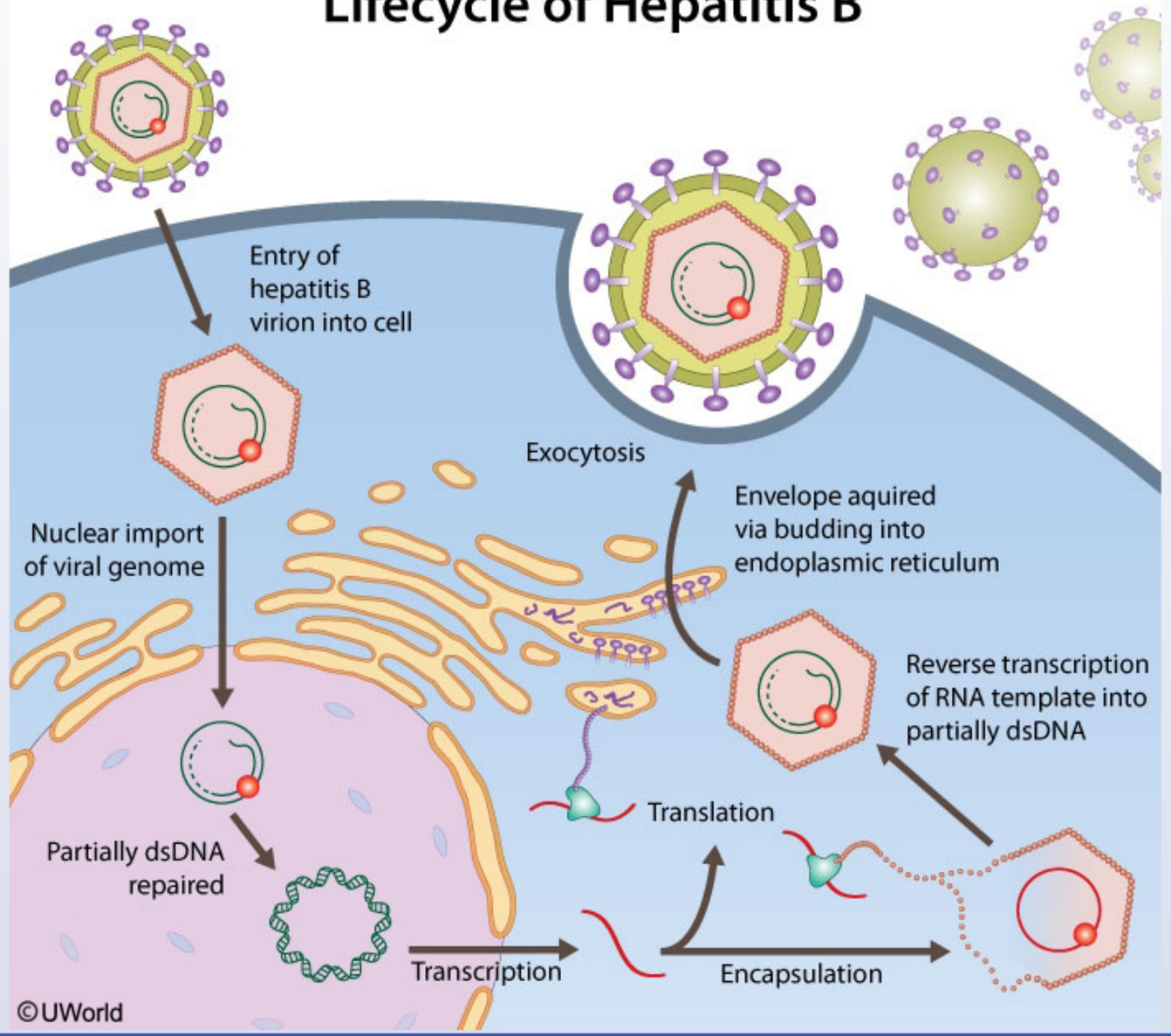

1
2
3
4
5
6
7
8
9
10
11
12
13
14
15
16
17
18
19
20
21
22
23
24
25
26
27
28
29
30
31

This patient's fever and joint pain are nonspecific symptoms of a viral infection. Atypical (reactive) lymphocytes are also nonspecific and are seen with many viral infections (although Epstein-Barr virus and cytomegalovirus usually present with the highest counts).

Based on the described viral morphology, this patient is most likely infected with the hepatitis B virus (HBV), a member of the DNA-containing *Hepadnaviridae* family. The mature virion (called a Dane particle) consists of a hexagonal protein core (capsid) covered with a lipid bilayer envelope studded with proteins and carbohydrates. The HBV genome is a partially double-stranded circular DNA molecule housed within the capsid.

After the virion enters the cell, the capsid is released into the cytoplasm and the viral genome is transferred into the nucleus. The viral DNA is then repaired to form a fully double-stranded circular minichromosome that is capable of being transcribed into viral mRNAs. Replication of the genome occurs within a newly synthesized capsid containing the full-length viral mRNA transcript. Reverse transcriptase (which has both RNA- and DNA-dependent DNA-polymerase activity) acts on this RNA template to create a single-stranded DNA intermediate that is then converted back into circular, partially double-stranded DNA. The mature capsid is then enveloped by a portion of the endoplasmic reticulum containing virally-coded proteins to form the completed virion.

(Choice A) Coxsackie virus is within the *Picornaviridae* family and is composed of an icosahedral nucleocapsid and a + single-stranded RNA genome. The RNA has a protein on the 5' end that acts as a primer for transcription by RNA-dependent RNA polymerase.

(Choices B and C) Cytomegalovirus and Epstein-Barr virus are members of the *Herpesviridae* family. All viruses within this family contain an icosahedral core surrounded by a lipoprotein envelope and have double-stranded, linear DNA. These are the only viruses to acquire their envelopes by budding from the nuclear membrane.

(Choice E) Human immunodeficiency virus is within the *Lentivirus* subgroup of retroviruses. It contains a bar-shaped protein core surrounded by a glycoprotein envelope that includes the gp120 and gp41 glycoproteins. The genome is diploid, consisting of 2 + single-stranded RNA molecules that are transcribed into double-stranded DNA by a reverse transcriptase present in the capsid.

(Choice F) Parvovirus B19 is a small nonenveloped icosahedral virus with a linear, single-stranded DNA genome. There is no polymerase in the virion.

Educational objective:
Replication of the hepatitis B genome occurs within a newly synthesized capsid through the action of reverse transcriptase on an RNA template.
The mature capsid contains partially double-stranded circular DNA and reverse transcriptase.

then repaired to form a fully double-stranded circular minichromosome that is capable of being transcribed into viral mRNAs. Replication of the genome occurs within a newly synthesized capsid containing the full-length viral mRNA transcript. Reverse transcriptase (which has both RNA- and DNA-dependent DNA-polymerase activity) acts on this RNA template to create a single-stranded DNA intermediate that is then converted back into circular, partially double-stranded DNA. The mature capsid is then enveloped by a portion of the endoplasmic reticulum containing virally-coded proteins to form the completed virion.

(Choice A) Coxsackie virus is within the *Picornaviridae* family and is composed of an icosahedral nucleocapsid and a + single-stranded RNA genome. The RNA has a protein on the 5' end that acts as a primer for transcription by RNA-dependent RNA polymerase.

(Choices B and C) Cytomegalovirus and Epstein-Barr virus are members of the *Herpesviridae* family. All viruses within this family contain an icosahedral core surrounded by a lipoprotein envelope and have double-stranded, linear DNA. These are the only viruses to acquire their envelopes by budding from the nuclear membrane.

(Choice E) Human immunodeficiency virus is within the *Lentivirus* subgroup of retroviruses. It contains a bar-shaped protein core surrounded by a glycoprotein envelope that includes the gp120 and gp41 glycoproteins. The genome is diploid, consisting of 2 + single-stranded RNA molecules that are transcribed into double-stranded DNA by a reverse transcriptase present in the capsid.

(Choice F) Parvovirus B19 is a small nonenveloped icosahedral virus with a linear, single-stranded DNA genome. There is no polymerase in the virion.

Educational objective:
Replication of the hepatitis B genome occurs within a newly synthesized capsid through the action of reverse transcriptase on an RNA template. The mature capsid contains partially double-stranded circular DNA and reverse transcriptase.

References

- Molecular virology of hepatitis B virus for clinicians.

Microbiology	Infectious Diseases	Hepatitis b
Subject	System	Topic

Copyright © UWorld. All rights reserved.

1
2
3
4
5
6
7
8
9
10
11
12
13
14
15
16
17
18
19
20
21
22
23
24
25
26
27
28
29
30
31

A 38-year-old woman comes to the emergency department due to abdominal discomfort and diarrhea. Her symptoms began after she returned yesterday from a Caribbean cruise. She consumed bottled water but ate raw, local seafood when visiting one of the islands. The cruise line has reported no other passengers with abdominal illness. On examination, the abdomen is soft with mild, generalized tenderness and hyperactive bowel sounds. A comma-shaped, oxidase-positive, gram-negative rod naturally found in salt water is implicated in her illness. Stool microscopy is most likely to demonstrate which of the following findings?

A. Many leukocytes, with eosinophilic predominance

B. Many leukocytes, with monocytic predominance

C. Many leukocytes, with neutrophilic predominance

D. Numerous erythrocytes and some leukocytes

E. Some mucus and no erythrocytes or leukocytes

Submit

A 38-year-old woman comes to the emergency department due to abdominal discomfort and diarrhea. Her symptoms began after she returned yesterday from a Caribbean cruise. She consumed bottled water but ate raw, local seafood when visiting one of the islands. The cruise line has reported no other passengers with abdominal illness. On examination, the abdomen is soft with mild, generalized tenderness and hyperactive bowel sounds. A comma-shaped, oxidase-positive, gram-negative rod naturally found in salt water is implicated in her illness. Stool microscopy is most likely to demonstrate which of the following findings?

A. Many leukocytes, with eosinophilic predominance (3%)

B. Many leukocytes, with monocytic predominance (5%)

C. Many leukocytes, with neutrophilic predominance (44%)

D. Numerous erythrocytes and some leukocytes (5%)

✓ E. Some mucus and no erythrocytes or leukocytes (41%)

Omitted
Correct answer
E

41%
Answered correctly

01 sec
Time Spent

04/10/2020
Last Updated

Explanation

Stool findings in acute diarrhea			
	Mechanism	**Stool findings**	**Examples of pathogens**
			Vibrio cholerae, enterotoxigenic *Escherichia coli*, *Bacillus cereus*,

Stool findings in acute diarrhea			
	Mechanism	**Stool findings**	**Examples of pathogens**
Watery diarrhea	Noninflammatory (enterotoxin)	No fecal leukocytes No red cells	*Vibrio cholerae*, enterotoxigenic *Escherichia coli*, *Bacillus cereus*, *Staphylococcus aureus*, some viruses, *Giardia lamblia*, *Cryptosporidium* species, *Cyclospora* species, microsporidia
Dysentery or inflammatory diarrhea	Inflammatory (invasion or cytotoxin)	Fecal polymorphonuclear leukocytes With or without red cells	*Shigella* species, *Salmonella* species, *Campylobacter jejuni*, enteroinvasive *E coli*, *Yersinia enterocolitica*, *Clostridium difficile*, *Entamoeba histolytica*
Enteric fever	Penetration & possible dissemination	Fecal mononuclear leukocytes	*Salmonella* Typhi

Vibrio cholerae is an oxidase-positive, gram-negative, comma-shaped organism that requires salt for growth and exists naturally in aquatic environments. Transmission occurs due to ingestion of contaminated food or water. Sporadic cases are often caused by the consumption of **contaminated shellfish**; outbreaks may occur in areas where safe water, sanitation, and health care services are limited.

Pathogens typically cause diarrhea by invading/damaging the intestinal epithelium or releasing enterotoxins. *V cholerae* is a noninvasive organism. It clumps together in colonies along the surface of the small intestine and causes diarrhea via the elaboration of **cholera toxin** (related to enterotoxigenic *Escherichia coli* heat-labile toxin). This enterotoxin enters intestinal epithelial cells and activates adenylate cyclase, leading to increased chloride efflux, reduced sodium reabsorption, and the subsequent movement of water from the enterocyte to the gastrointestinal lumen.

Patients typically present with **high-volume, watery diarrhea** that can cause dehydration and death within 12 hours. Because the pathogen is noninvasive and the toxin does not cause cell death, stool microscopy generally reveals **no leukocytes or erythrocytes**. However, flecks of mucus are often seen (**rice-water stool**) due to the activation of goblet cells. Aggressive fluid resuscitation is the mainstay of therapy.

1
2
3
4
5
6
7
8
9
10
11
12
13
14
15
16
17
18
19
20
21
22
23
24
25
26
27
28
29
30
31

Vibrio cholerae is an oxidase-positive, gram-negative, comma-shaped organism that requires salt for growth and exists naturally in aquatic environments. Transmission occurs due to ingestion of contaminated food or water. Sporadic cases are often caused by the consumption of **contaminated shellfish**; outbreaks may occur in areas where safe water, sanitation, and health care services are limited.

Pathogens typically cause diarrhea by invading/damaging the intestinal epithelium or releasing enterotoxins. *V cholerae* is a noninvasive organism. It clumps together in colonies along the surface of the small intestine and causes diarrhea via the elaboration of **cholera toxin** (related to enterotoxigenic *Escherichia coli* heat-labile toxin). This enterotoxin enters intestinal epithelial cells and activates adenylate cyclase, leading to increased chloride efflux, reduced sodium reabsorption, and the subsequent movement of water from the enterocyte to the gastrointestinal lumen.

Patients typically present with **high-volume, watery diarrhea** that can cause dehydration and death within 12 hours. Because the pathogen is noninvasive and the toxin does not cause cell death, stool microscopy generally reveals **no leukocytes or erythrocytes**. However, flecks of mucus are often seen (**rice-water stool**) due to the activation of goblet cells. Aggressive fluid resuscitation is the mainstay of therapy.

(Choice A) Charcot-Leyden crystals (from eosinophil breakdown) in the stool are sometimes seen in intestinal parasitic infections. Diarrhea with peripheral eosinophilia can be seen with *Strongyloides*, *Ancylostoma*, *Ascaris*, *Toxocara*, and *Trichinella* (but not with *Giardia* or *Entamoeba*).

(Choice B) The presence of leukocytes with monocytic predominance is typical for typhoid fever caused by *Salmonella* Typhi.

(Choices C and D) Invading bacteria that cause dysentery or inflammatory diarrhea (eg, *Shigella* species, *Salmonella* species, *Campylobacter jejuni*, enteroinvasive *E coli* [EIEC]) are usually marked by leukocytes with neutrophilic predominance and erythrocytes. A hemorrhagic organism (eg, enterohemorrhagic *E coli* O157:H7, which causes toxin-mediated enterocyte death and intestinal hemorrhage without mucosal invasion) would be characterized by erythrocytes without leukocytes.

Educational objective:
Vibrio cholerae and enterotoxigenic *Escherichia coli* cause a purely toxin-mediated watery diarrhea. The toxins secreted by these organisms modify electrolyte handling by enterocytes but do not cause cell death; therefore, no erythrocytes or leukocytes are typically noted on stool microscopy.

References

- Laboratory diagnosis of bacterial gastroenteritis.
- Complexity of rice-water stool from patients with Vibrio cholerae plays a role in the transmission of infectious diarrhea.

to enterotoxigenic *Escherichia coli* heat-labile toxin). This enterotoxin enters intestinal epithelial cells and activates adenylate cyclase, leading to increased chloride efflux, reduced sodium reabsorption, and the subsequent movement of water from the enterocyte to the gastrointestinal lumen.

Patients typically present with **high-volume, watery diarrhea** that can cause dehydration and death within 12 hours. Because the pathogen is noninvasive and the toxin does not cause cell death, stool microscopy generally reveals **no leukocytes or erythrocytes**. However, flecks of mucus are often seen (**rice-water stool**) due to the activation of goblet cells. Aggressive fluid resuscitation is the mainstay of therapy.

(Choice A) Charcot-Leyden crystals (from eosinophil breakdown) in the stool are sometimes seen in intestinal parasitic infections. Diarrhea with peripheral eosinophilia can be seen with *Strongyloides*, *Ancylostoma*, *Ascaris*, *Toxocara*, and *Trichinella* (but not with *Giardia* or *Entamoeba*).

(Choice B) The presence of leukocytes with monocytic predominance is typical for typhoid fever caused by *Salmonella* Typhi.

(Choices C and D) Invading bacteria that cause dysentery or inflammatory diarrhea (eg, *Shigella* species, *Salmonella* species, *Campylobacter jejuni*, enteroinvasive *E coli* [EIEC]) are usually marked by leukocytes with neutrophilic predominance and erythrocytes. A hemorrhagic organism (eg, enterohemorrhagic *E coli* O157:H7, which causes toxin-mediated enterocyte death and intestinal hemorrhage without mucosal invasion) would be characterized by erythrocytes without leukocytes.

Educational objective:
Vibrio cholerae and enterotoxigenic *Escherichia coli* cause a purely toxin-mediated watery diarrhea. The toxins secreted by these organisms modify electrolyte handling by enterocytes but do not cause cell death; therefore, no erythrocytes or leukocytes are typically noted on stool microscopy.

References

- Laboratory diagnosis of bacterial gastroenteritis.
- Complexity of rice-water stool from patients with Vibrio cholerae plays a role in the transmission of infectious diarrhea.

Microbiology	Infectious Diseases	Cholera
Subject	System	Topic

Copyright © UWorld. All rights reserved.

1
2
3
4
5
6
7
8
9
10
11
12
13
14
15
16
17
18
19
20
21
22
23
24
25
26
27
28
29
30
31

A 16-year-old previously healthy adolescent developed nonproductive cough, dyspnea, and wheezing after traveling abroad. The patient has no history of allergies and has had no recent upper respiratory illness. The symptoms spontaneously resolved after several days, but soon after, she began having abdominal discomfort, anorexia, and nausea. Stool microscopy results are shown in the following image:

Which of the following was the most likely cause of this patient's pulmonary symptoms?

A. Formation of cross-reacting antibodies

B. Immune response against inhaled spores

C. Parasite-induced cardiac dysfunction

D. Transpulmonary migration of larvae

E. Type IV hypersensitivity to a foreign antigen

Submit

1
2
3
4
5
6
7
8
9
10
11
12
13
14
15
16
17
18
19
20
21
22
23
24
25
26
27
28
29
30
31

A 16-year-old previously healthy adolescent developed nonproductive cough, dyspnea, and wheezing after traveling abroad. The patient has no history of allergies and has had no recent upper respiratory illness. The symptoms spontaneously resolved after several days, but soon after, she began having abdominal discomfort, anorexia, and nausea. Stool microscopy results are shown in the following image:



Which of the following was the most likely cause of this patient's pulmonary symptoms?

A. Formation of cross-reacting antibodies

B. Immune response against inhaled spores

C. Parasite-induced cardiac dysfunction

D. Transpulmonary migration of larvae

E. Type IV hypersensitivity to a foreign antigen

Submit



Which of the following was the most likely cause of this patient's pulmonary symptoms?

- A. Formation of cross-reacting antibodies (3%)
- B. Immune response against inhaled spores (6%)
- C. Parasite-induced cardiac dysfunction (1%)
- ✓ D. Transpulmonary migration of larvae (86%)
- E. Type IV hypersensitivity to a foreign antigen (2%)

Omitted
Correct answer

86%
Answered correctly

06 secs
Time Spent

03/08/2020
Last Updated

1 2 3 4 5 6 7 8 9 10 11 12 13 14 15 16 17 18 19 20 21 22 23 24 25 26 27 28 29 30 31

1
2
3
4
5
6
7
8
9
10
11
12
13
14
15
16
17
18
19
20
21
22
23
24
25
26
27
28
29
30
31

This patient's recent travel, transient pulmonary symptoms, and subsequent gastrointestinal manifestations are suspicious for a **parasitic infection** involving the lungs and intestines. Stool microscopy reveals an oval egg with a thick outer shell and a single interior ovum, thereby confirming ***Ascaris lumbricoides*** (roundworm) infection.

A lumbricoides is a common parasitic infection in Asia, Africa, and South America. Most cases in the United States arise in **travelers** to these regions. Transmission occurs when **eggs are ingested** via contaminated food or water. Eggs hatch into larvae in the small intestine, penetrate the intestinal wall, and **migrate to the alveoli**, where they mature. Pulmonary infection is generally asymptomatic, but a minority of infected individuals develop **Loeffler syndrome**, a transient, **eosinophilic pneumonitis** with pulmonary symptoms (eg, dry cough, dyspnea, wheezing).

After several days, larvae are coughed out of the alveoli and subsequently swallowed into the gastrointestinal tract, where they mature into long (25- to 35-cm) adult worms that shed up to 100,000 eggs per day. Most gastrointestinal infections are asymptomatic, but some patients have abdominal discomfort, nausea/vomiting, and diarrhea. The diagnosis of **gastrointestinal tract infection** is made by inspecting the stool for eggs; treatment with antiparasitic drugs (eg, albendazole) is generally curative.

(Choice A) Rheumatic fever is associated with the formation of cross-reacting antibodies to renal, neuronal, and cardiac antigens following group A *Streptococcus* pharyngitis. Eggs would not be seen in stool.

(Choice B) Hypersensitivity pneumonitis, an immune reaction to an inhaled agent, can occur following exposure to mold dust or spores. Patients generally develop acute fever, nausea, cough, and dyspnea. However, wheezing is uncommon, and eggs would not be shed in stool.

(Choice C) Chagas disease, a parasitic infection caused by *Trypanosoma cruzi*, can cause myopericarditis during acute infection. However, cardiac and gastrointestinal manifestations are much more likely to occur years or decades later. In addition, *T cruzi* is not shed in stool; it can sometimes be visualized on blood smear.

(Choice E) Type IV hypersensitivity reactions are mediated by T cells and are often seen as part of certain drug reactions (eg, Stevens-Johnson syndrome). In contrast, *Ascaris* infections are associated with IgE-mediated (eosinophilic) hypersensitivity.

Educational objective:
Ascaris lumbricoides is transmitted via contaminated food or water. Eggs hatch into larvae in the small intestine, penetrate the intestinal wall, and migrate across the lung into the alveoli. Larvae are subsequently coughed up and swallowed into the gastrointestinal tract, where they mature to adult worms. Most patients are asymptomatic, but some develop early pulmonary manifestations (Loeffler syndrome) or later gastrointestinal

regions. Transmission occurs when **eggs are ingested** via contaminated food or water. Eggs hatch into larvae in the small intestine, penetrate the intestinal wall, and **migrate to the alveoli**, where they mature. Pulmonary infection is generally asymptomatic, but a minority of infected individuals develop **Loeffler syndrome**, a transient, **eosinophilic pneumonitis** with pulmonary symptoms (eg, dry cough, dyspnea, wheezing).

After several days, larvae are coughed out of the alveoli and subsequently swallowed into the gastrointestinal tract, where they mature into long (25- to 35-cm) adult worms that shed up to 100,000 eggs per day. Most gastrointestinal infections are asymptomatic, but some patients have abdominal discomfort, nausea/vomiting, and diarrhea. The diagnosis of **gastrointestinal tract infection** is made by inspecting the stool for eggs; treatment with antiparasitic drugs (eg, albendazole) is generally curative.

(Choice A) Rheumatic fever is associated with the formation of cross-reacting antibodies to renal, neuronal, and cardiac antigens following group A *Streptococcus* pharyngitis. Eggs would not be seen in stool.

(Choice B) Hypersensitivity pneumonitis, an immune reaction to an inhaled agent, can occur following exposure to mold dust or spores. Patients generally develop acute fever, nausea, cough, and dyspnea. However, wheezing is uncommon, and eggs would not be shed in stool.

(Choice C) Chagas disease, a parasitic infection caused by *Trypanosoma cruzi*, can cause myopericarditis during acute infection. However, cardiac and gastrointestinal manifestations are much more likely to occur years or decades later. In addition, *T cruzi* is not shed in stool; it can sometimes be visualized on blood smear.

(Choice E) Type IV hypersensitivity reactions are mediated by T cells and are often seen as part of certain drug reactions (eg, Stevens-Johnson syndrome). In contrast, *Ascaris* infections are associated with IgE-mediated (eosinophilic) hypersensitivity.

Educational objective:
Ascaris lumbricoides is transmitted via contaminated food or water. Eggs hatch into larvae in the small intestine, penetrate the intestinal wall, and migrate across the lung into the alveoli. Larvae are subsequently coughed up and swallowed into the gastrointestinal tract, where they mature to adult worms. Most patients are asymptomatic, but some develop early pulmonary manifestations (Loeffler syndrome) or later gastrointestinal symptoms.

Microbiology	Infectious Diseases	Intestinal helminth parasites
Subject	System	Topic

Copyright © UWorld. All rights reserved.

D. Transpulmonary migration of larvae (86%)

Exhibit Display

Ascaris lumbricoides

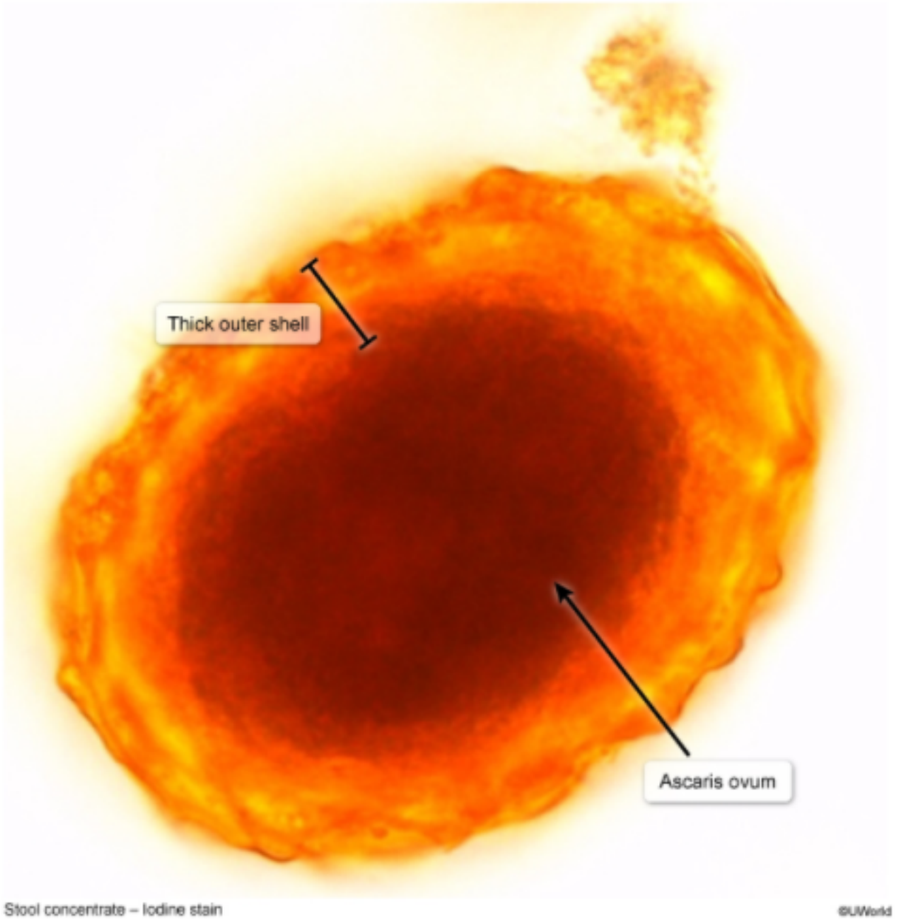

Zoom In | Zoom Out | Reset | Add To New Card | Existing Card

generally develop acute fever, nausea, cough, and dyspnea. However, wheezing is uncommon, and eggs would not be shed in stool.

regions. Transmission occurs when **eggs are ingested** via contaminated food or water. Eggs hatch into larvae in the small intestine, penetrate

Exhibit Display

Zoom In | Zoom Out | Reset | Add To New Card | Existing Card

Copyright © UWorld. All rights reserved.

1
2
3
4
5
6
7
8
9
10
11
12
13
14
15
16
17
18
19
20
21
22
23
24
25
26
27
28
29
30
31

regions. Transmission occurs when **eggs are ingested** via contaminated food or water. Eggs hatch into larvae in the small intestine, penetrate

Exhibit Display

Trypanosoma cruzi

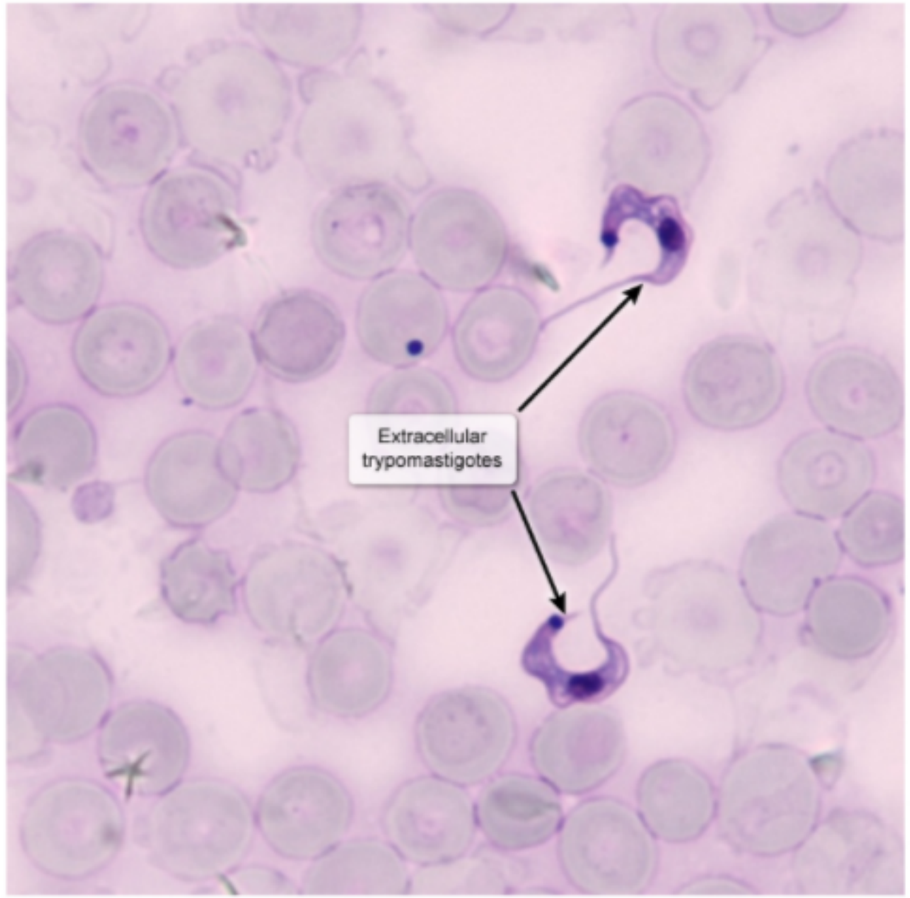

Peripheral blood smear – Giemsa stain ©UWorld

Zoom In | Zoom Out | Reset | Add To New Card | Existing Card

Copyright © UWorld. All rights reserved.

1
2
3
4
5
6
7
8
9
10
11
12
13
14
15
16
17
18
19
20
21
22
23
24
25
26
27
28
29
30
31

A 34-year-old man comes to the physician due to fever, myalgias, malaise, and progressive fatigue over a 2-week period. He has not experienced any sore throat. He recently received a blood transfusion while hospitalized for a bleeding duodenal ulcer. Physical examination shows mild splenomegaly. There is no lymphadenopathy and no jaundice. Lymphocytosis is identified in the peripheral blood with 30% atypical lymphocytes. The patient's serum fails to agglutinate horse erythrocytes. The agglutination test is repeated a week later and, again, no agglutination is noted. HIV testing is negative. Which of the following is the most likely cause of this patient's condition?

A. Coxsackievirus A
B. Cytomegalovirus
C. Epstein-Barr virus
D. Hepatitis C virus
E. JC virus
F. Parvovirus B19

Submit

A 34-year-old man comes to the physician due to fever, myalgias, malaise, and progressive fatigue over a 2-week period. He has not experienced any sore throat. He recently received a blood transfusion while hospitalized for a bleeding duodenal ulcer. Physical examination shows mild splenomegaly. There is no lymphadenopathy and no jaundice. Lymphocytosis is identified in the peripheral blood with 30% atypical lymphocytes. The patient's serum fails to agglutinate horse erythrocytes. The agglutination test is repeated a week later and, again, no agglutination is noted. HIV testing is negative. Which of the following is the most likely cause of this patient's condition?

- A. Coxsackievirus A (2%)
- ✓ B. Cytomegalovirus (62%)
- C. Epstein-Barr virus (15%)
- D. Hepatitis C virus (8%)
- E. JC virus (3%)
- F. Parvovirus B19 (6%)

Omitted
Correct answer
B

62%
Answered correctly

02 secs
Time Spent

03/15/2020
Last Updated

Explanation

Most cases of **infectious mononucleosis (IM)**, caused by the **Epstein-Barr virus (EBV)**, are associated with **serum heterophile antibodies** that agglutinate with erythrocytes from unrelated species (eg, horse erythrocytes in the Monospot test, sheep erythrocytes in the classic Paul-Bunnell test). The agglutination test may be negative at the beginning of the infection and can be repeated later for confirmation. Because the Monospot (horse erythrocyte agglutination) test was negative on 2 separate occasions in this patient with a mononucleosis-like syndrome (fever,

1 2 3 4 5 6 7 8 9 10 11 12 13 14 15 16 17 18 19 20 21 22 23 24 25 26 27 28 29 30 31

Most cases of **infectious mononucleosis (IM)**, caused by the **Epstein-Barr virus (EBV)**, are associated with **serum heterophile antibodies** that agglutinate with erythrocytes from unrelated species (eg, horse erythrocytes in the Monospot test, sheep erythrocytes in the classic Paul-Bunnell test). The agglutination test may be negative at the beginning of the infection and can be repeated later for confirmation. Because the Monospot (horse erythrocyte agglutination) test was negative on 2 separate occasions in this patient with a mononucleosis-like syndrome (fever, fatigue, splenomegaly, atypical lymphocytosis), his symptoms are **unlikely** to be due to EBV; the lack of sore throat and lymphadenopathy is also atypical for classic EBV-associated IM **(Choice C)**.

In immunocompetent patients with a **heterophile antibody-negative mononucleosis-like syndrome**, the most likely diagnosis is **cytomegalovirus (CMV) infection**. Pharyngitis and lymphadenopathy are seen less commonly than with EBV. CMV can be acquired during the transfusion of leukocyte-laden blood products, as the virus infects leukocytes of granulocyte-macrophage lineage. Irradiation helps reduce this risk. Other causes of heterophile antibody-negative mononucleosis-like syndromes include human herpesvirus-6, HIV, and toxoplasmosis.

(Choice A) Coxsackie A viruses cause aseptic meningitis and herpangina (fever, posterior pharyngeal gray vesicles/ulcers) in children.

(Choice D) Acute hepatitis C (HCV) rarely causes symptoms. Transfusion-acquired HCV can cause chronic hepatitis, but highly sensitive blood donor screening tests have led to low transmission rates. Atypical lymphocytosis is less common with HCV than with EBV or CMV.

(Choice E) JC virus causes progressive multifocal leukoencephalopathy (PML), a central nervous system viral infection seen in immunocompromised patients. Clinical manifestations include hemiparesis, visual field defects (eg, hemianopsia), and cognitive impairment.

(Choice F) Parvovirus B19 causes erythema infectiosum, a childhood illness characterized by red, flushed cheeks ("slapped cheeks" appearance). The virus can also cause aplastic crises in patients with sickle cell anemia and hydrops fetalis in the fetus.

Educational objective:
The Monospot test is positive in most cases of Epstein-Barr virus-associated mononucleosis. In immunocompetent patients with a heterophile antibody-negative mononucleosis-like syndrome, the most likely diagnosis is cytomegalovirus infection.

Microbiology	Infectious Diseases	Cytomegalovirus
Subject	System	Topic

Copyright © UWorld. All rights reserved.

A 59-year-old woman is brought to the emergency department with fever, skin flushing, and an altered level of consciousness. Her blood pressure is 50/20 mmHg, and her heart rate is 120/min despite receiving IV fluids. If blood cultures are positive for *E. coli*, which of the following bacterial factors is most directly responsible for this patient's current condition?

- A. Capsule
- B. Fimbrial antigen
- C. Heat-stable exotoxin
- D. Lipid A
- E. O antigen

Submit

A 59-year-old woman is brought to the emergency department with fever, skin flushing, and an altered level of consciousness. Her blood pressure is 50/20 mmHg, and her heart rate is 120/min despite receiving IV fluids. If blood cultures are positive for *E. coli*, which of the following bacterial factors is most directly responsible for this patient's current condition?

- A. Capsule (14%)
- B. Fimbrial antigen (9%)
- C. Heat-stable exotoxin (12%)
- ✓ D. Lipid A (51%)
- E. O antigen (10%)

Omitted
Correct answer
D

51%
Answered correctly

02 secs
Time Spent

04/07/2020
Last Updated

Explanation

This patient has **septic shock** (ie, fluid-refractory hypotension in a patient with sepsis) as a result of the release of **bacterial endotoxins** into the bloodstream. Endotoxins are found in the outer membrane of Gram-negative bacteria (eg, *E. coli*), which is composed of lipopolysaccharide (LPS). LPS is released by destruction of the bacterial cell wall or during cell division. LPS is a very long, heat-stable molecule arranged into three regions: O antigen, core polysaccharide, and Lipid A.

Lipid A is toxic to mammalian cells and acts as a virulence factor by inducing the release of endogenous pyrogens (eg, IL-1, prostaglandins) and inflammatory mediators (eg, TNFa, interferon) from activated macrophages. These cytokines cause the manifestations of septic shock: fever, **hypotension**, increased vascular permeability with third-spacing of fluids, and **organ failure**.

This patient has **septic shock** (ie, fluid-refractory hypotension in a patient with sepsis) as a result of the release of **bacterial endotoxins** into the bloodstream. Endotoxins are found in the outer membrane of Gram-negative bacteria (eg, *E. coli*), which is composed of lipopolysaccharide (LPS). LPS is released by destruction of the bacterial cell wall or during cell division. LPS is a very long, heat-stable molecule arranged into three regions: O antigen, core polysaccharide, and Lipid A.

Lipid A is toxic to mammalian cells and acts as a virulence factor by inducing the release of endogenous pyrogens (eg, IL-1, prostaglandins) and inflammatory mediators (eg, TNFa, interferon) from activated macrophages. These cytokines cause the manifestations of septic shock: fever, **hypotension**, increased vascular permeability with third-spacing of fluids, and **organ failure**.

(Choice A) *E. coli* strains can produce a capsule (eg, K-1 antigen) which provides a defense against phagocytosis by immune cells but does not directly contribute to the manifestations of septic shock.

(Choice B) Fimbriae, or pili, allow bacteria to adhere to the target tissue and establish infection. Although Enterotoxigenic *E. coli* is an example of an organism that uses fimbriae, bacterial adhesion is not directly responsible for the manifestations of septic shock.

(Choice C) Heat-stable exotoxin is one of the enterotoxins produced by Enterotoxigenic *E. coli* but is responsible for secretory diarrhea rather than the manifestations of septic shock.

(Choice E) Although the O antigen is part of the lipopolysaccharide of a gram-negative bacteria and can be used for identification of different strains, it is not directly involved in the manifestations of septic shock.

Educational objective:
Gram-negative sepsis is caused by the release of lipopolysaccharides from bacterial cells during cell division or bacteriolysis. Lipid A is the toxic component of lipopolysaccharides and induces the widespread release of IL-1 and TNF-alpha from activated macrophages. These cytokines cause the signs and symptoms of septic shock (eg, fever, hypotension, organ dysfunction).

Microbiology	Infectious Diseases	Sepsis
Subject	System	Topic

Copyright © UWorld. All rights reserved.

A 19-year-old man comes to the physician due to watery diarrhea for the last 4 months. He visited a student health clinic at his university a month ago and was prescribed a course of antibiotics, but his diarrhea failed to improve. He also has persistent nausea, a bloating sensation, and a 6.8-kg (15-lb) weight loss. Microscopic examination of his stool for ova and parasites following trichrome staining is shown in the image below.

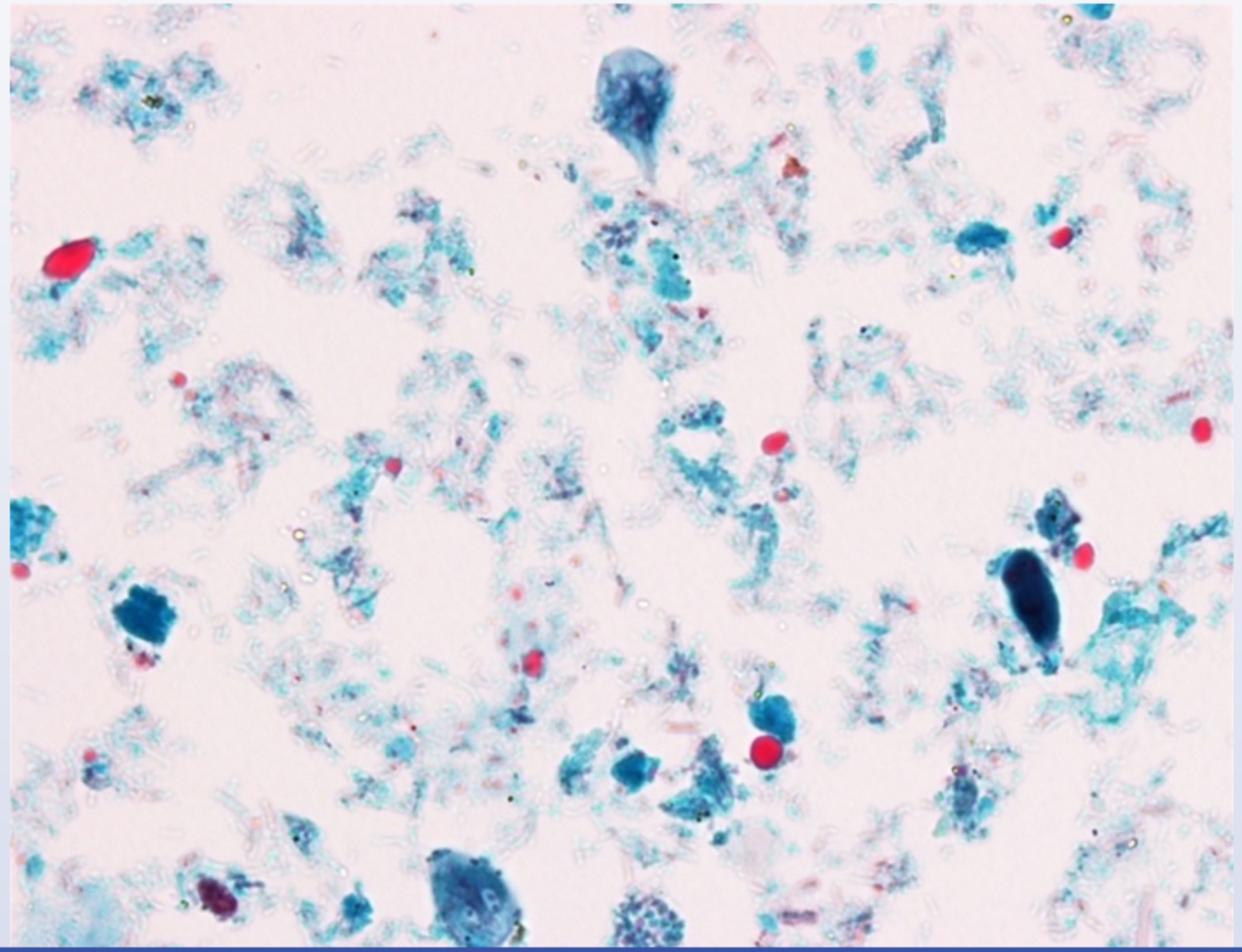

1 2 3 4 5 6 7 8 9 10 11 12 13 14 15 16 17 18 19 20 21 22 23 24 25 26 27 28 29 30 31

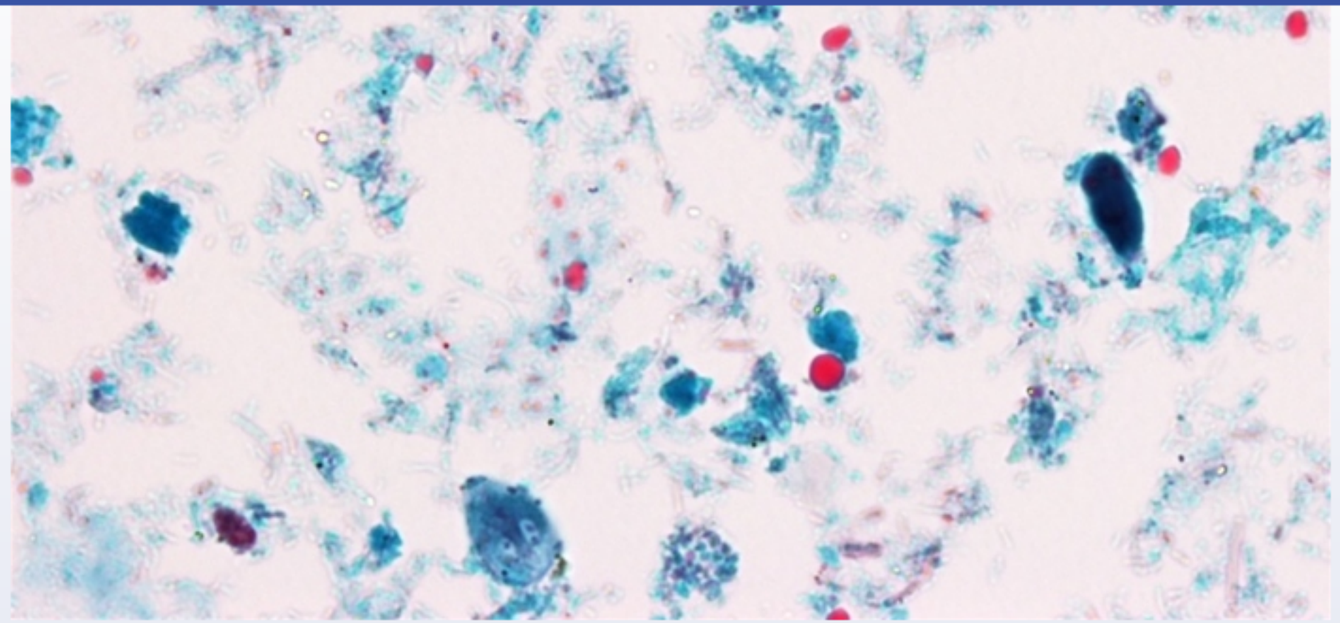

Impairment of which of the following defense mechanisms would most likely predispose to this patient's condition?

A. Bacterial killing by neutrophils

B. CD8+ T lymphocyte-mediated cytotoxicity

C. Eosinophil-mediated cytotoxicity

D. Membrane attack complex formation

E. Secretory IgA production

Submit

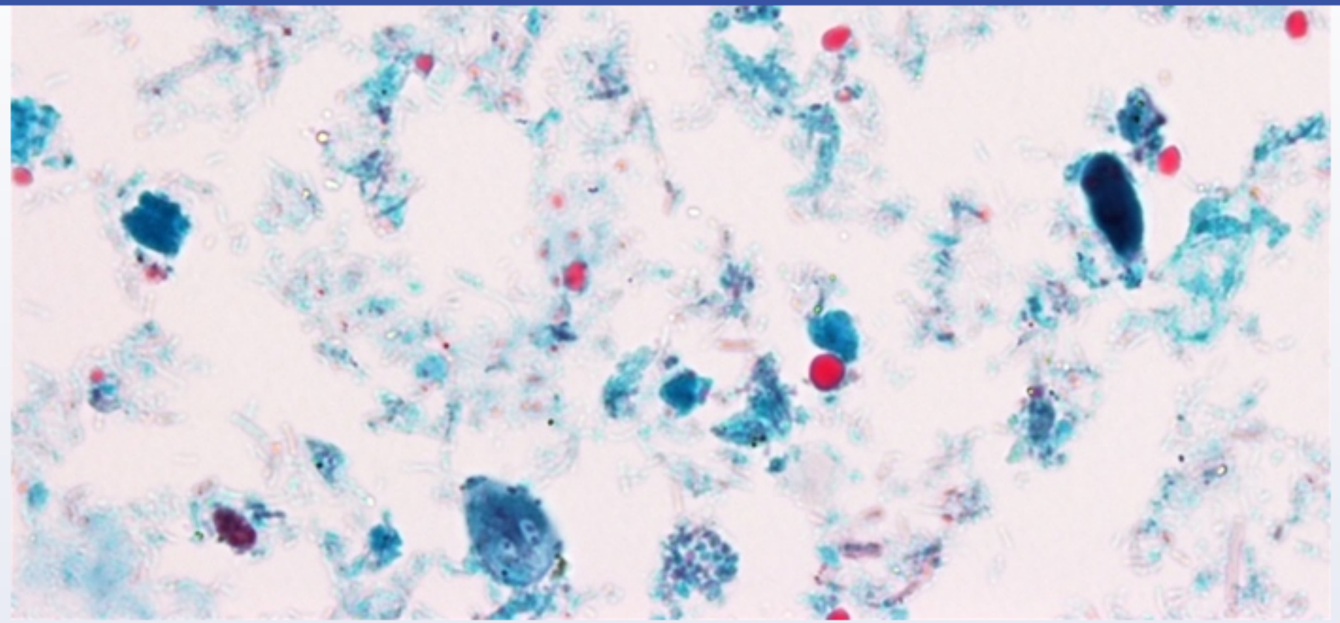

Impairment of which of the following defense mechanisms would most likely predispose to this patient's condition?

A. Bacterial killing by neutrophils (2%)

B. CD8+ T lymphocyte-mediated cytotoxicity (7%)

C. Eosinophil-mediated cytotoxicity (41%)

D. Membrane attack complex formation (2%)

✓ E. Secretory IgA production (45%)

Omitted
Correct answer

45%
Answered correctly

05 secs
Time Spent

06/29/2020
Last Updated

1
2
3
4
5
6
7
8
9
10
11
12
13
14
15
16
17
18
19
20
21
22
23
24
25
26
27
28
29
30
31

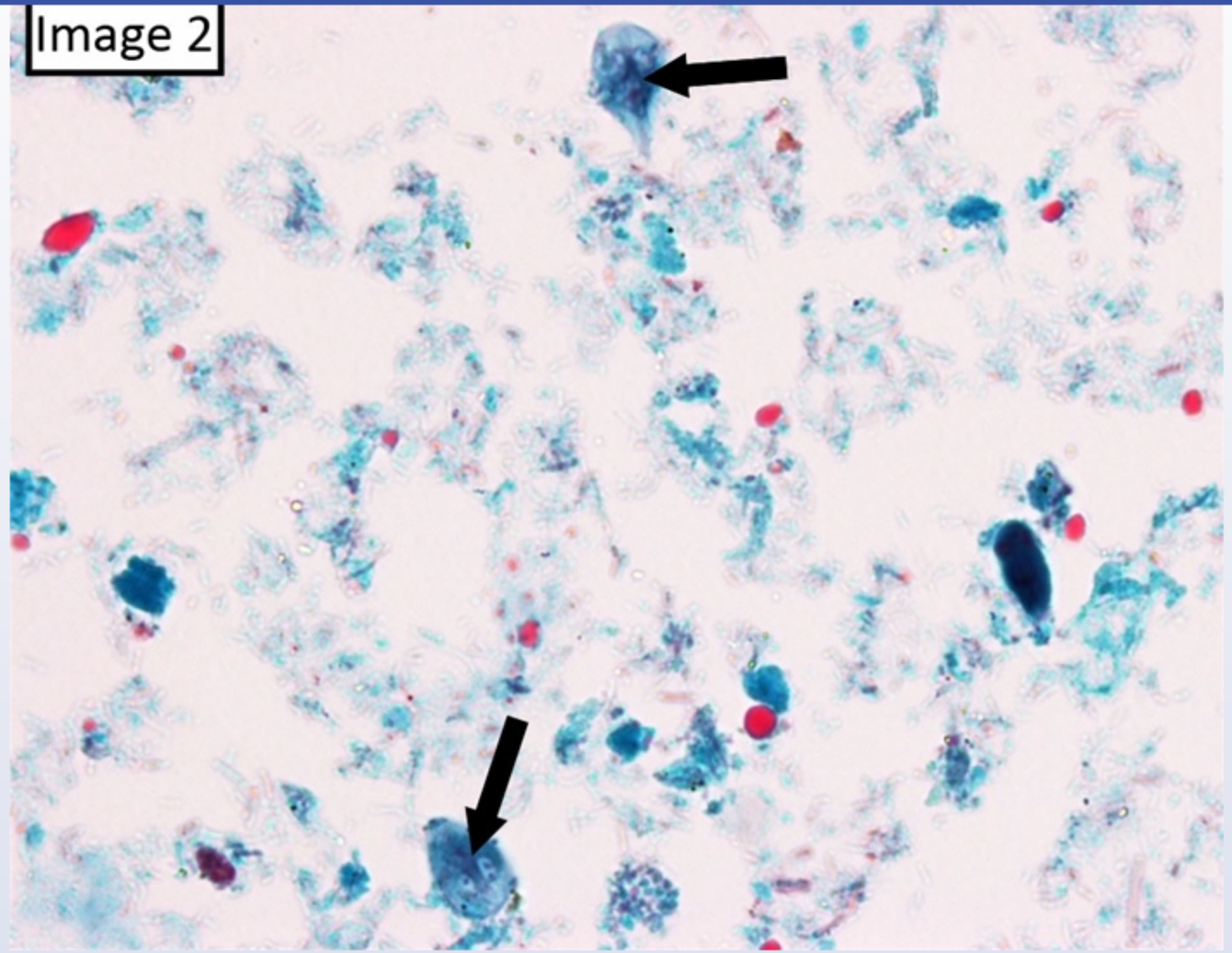

Giardia lamblia is an intestinal flagellate that exists in 2 forms: a trophozoite (pathogenic stage) or a cyst (infective stage). The trophozoite is a bilaterally symmetric, **pear-shaped** organism with multiple flagella and **2 nuclei** (owl's eyes appearance); the cysts are oval and contain up to 4 nuclei. The disease is transmitted by drinking contaminated water (eg, campers, travelers to endemic areas) or via fecal-oral transmission (eg, children in day care centers).

Giardia lamblia is an intestinal flagellate that exists in 2 forms: a trophozoite (pathogenic stage) or a cyst (infective stage). The trophozoite is a bilaterally symmetric, **pear-shaped** organism with multiple flagella and **2 nuclei** (owl's eyes appearance); the cysts are oval and contain up to 4 nuclei. The disease is transmitted by drinking contaminated water (eg, campers, travelers to endemic areas) or via fecal-oral transmission (eg, children in day care centers).

Giardiasis can be asymptomatic or present with a variable combination of **watery diarrhea**, nausea, abdominal cramps, and malabsorption (eg, foul-smelling stools). The diagnosis is confirmed by **stool microscopy for ova and parasites** or fecal immunoassays for *Giardia* antigens. Small-bowel biopsy is sometimes performed when stool studies are nondiagnostic and can show varying degrees of **villus atrophy** and crypt hyperplasia depending on disease severity.

The major immune mechanisms against *Giardia* involve CD4+ T helper cells and **secretory IgA production**. Secretory IgA helps prevent and clear infection by binding to trophozoites and impairing their adherence to the upper small-bowel mucosa. Children with IgA deficiency, X-linked agammaglobulinemia, and common variable immune deficiency have a predisposition to developing chronic giardiasis.

(Choices A and D) Neutrophils and the complement system are important defense mechanisms against bacterial infections. They have no significant role in controlling parasitic infections.

(Choice B) CD8+ T cells are not important in clearing giardiasis; they are more important for combating intracellular intestinal pathogens such as *Cryptosporidium parvum* and *Toxoplasma gondii*.

(Choice C) Eosinophils do not play an important role in immune defense against *Giardia*; eosinophilia is not seen in giardiasis and white cells are usually absent from the stool. Eosinophils are more important for combating intestinal helminthic infections.

Educational objective:
Giardia lamblia causes injury to the duodenal and jejunal mucosa by adhering to the intestinal brush border and releasing molecules that induce a mucosal inflammatory response. Secretory IgA, which impairs adherence, is the major component of adaptive immunity against *G lamblia* infection. Conditions causing IgA deficiency predispose patients to chronic giardiasis.

Microbiology	Infectious Diseases	Giardia
Subject	System	Topic

Copyright © UWorld. All rights reserved.

1
2
3
4
5
6
7
8
9
10
11
12
13
14
15
16
17
18
19
20
21
22
23
24
25
26
27
28
29
30
31

A 23-year-old pregnant woman is found to have chronic viral hepatitis B on liver biopsy. The presence of which of the following serologic markers is most likely to increase the risk of vertical transmission of the virus?

- A. HBcAg
- B. HBsAg
- C. HBeAg
- D. Anti- HBcAg IgG
- E. Anti- HBeAg IgM
- F. Anti-HBsAg IgG

Submit

A 23-year-old pregnant woman is found to have chronic viral hepatitis B on liver biopsy. The presence of which of the following serologic markers is most likely to increase the risk of vertical transmission of the virus?

- A. HBcAg (4%)
- B. HBsAg (9%)
- ✓ C. HBeAg (76%)
- D. Anti- HBcAg IgG (3%)
- E. Anti- HBeAg IgM (3%)
- F. Anti-HBsAg IgG (2%)

Omitted
Correct answer
C

76%
Answered correctly

02 secs
Time Spent

02/03/2020
Last Updated

Explanation

Vertical transmission of hepatitis B from pregnant females to the unborn child can occur with active hepatitis B infection. Typically, such transmission takes place during the passage of the fetus through the birth canal, but transplacental infection can also occur. This is especially common in those women who developed acute hepatitis B infection in the third trimester.

The presence of HBeAg (a soluble protein that is a marker of viral replication and increased infectivity) in the mother significantly increases the risk of vertical transmission of the virus. Were this woman HBeAg negative, her neonate's risk of infection would be 20%. If she were HBeAg positive, however, her neonate's risk of infection would be 95%. Moreover, should the infant become infected, his chance of progression to chronic

Vertical transmission of hepatitis B from pregnant females to the unborn child can occur with active hepatitis B infection. Typically, such transmission takes place during the passage of the fetus through the birth canal, but transplacental infection can also occur. This is especially common in those women who developed acute hepatitis B infection in the third trimester.

The presence of HBeAg (a soluble protein that is a marker of viral replication and increased infectivity) in the mother significantly increases the risk of vertical transmission of the virus. Were this woman HBeAg negative, her neonate's risk of infection would be 20%. If she were HBeAg positive, however, her neonate's risk of infection would be 95%. Moreover, should the infant become infected, his chance of progression to chronic hepatitis is 90%. Because of this concern, the newborns of all mothers with active hepatitis B are passively immunized at birth with hepatitis B immune globulin (HBIG), followed by active immunization with recombinant HBV vaccine.

(Choice A) HBcAg is not detectable in serum as it is normally sequestrated within the HBsAg coat.

(Choice B) HBsAg is the first virological marker detected in the serum after inoculation, preceding both the elevation of serum aminotransferases and the onset of clinical symptoms. It remains detectable during the entire symptomatic phase of acute hepatitis B and suggests infectivity. It is not the most ominous marker in the pregnant woman, however.

(Choice D) Anti-HBc appears in the serum shortly after the emergence of HBsAg and remains detectable long after the patient recovers. The IgM fraction signals the acute phase of disease, whereas the IgG fraction signals recovery from the disease. Because IgM anti-HBc is present in the "window period," it is an important tool for diagnosis when HBsAg has been cleared and anti-HBs is not yet detectable. Thus IgM anti-HBc is the most specific marker for diagnosis of acute hepatitis B.

(Choice E) Anti-HBe suggests the cessation of active viral replication and low infectivity.

(Choice F) Anti-HBsAg IgG appears in the serum after either successful HBV vaccination or the clearance of HBsAg and remains detectable for life. It serves as an indicator of noninfectivity and immunity. However, there is a time lag between the disappearance of HBsAg and the appearance of anti-HBs in the serum, which is termed the "window period."

Educational Objective:
Vertical transmission of hepatitis B from pregnant females to the unborn child can occur in women with active hepatitis B infection. The presence of HBeAg (a marker of viral replication and increased infectivity) in the mother greatly increases the risk of vertical transmission of the virus. Because of this concern, the newborns of all mothers with active hepatitis B are passively immunized at birth with hepatitis B immune globulin

1 2 3 4 5 6 7 8 9 10 11 12 13 14 15 16 17 18 19 20 21 22 23 24 25 26 27 28 29 30 31

however, her neonate's risk of infection would be 95%. Moreover, should the infant become infected, his chance of progression to chronic hepatitis is 90%. Because of this concern, the newborns of all mothers with active hepatitis B are passively immunized at birth with hepatitis B immune globulin (HBIG), followed by active immunization with recombinant HBV vaccine.

(Choice A) HBcAg is not detectable in serum as it is normally sequestrated within the HBsAg coat.

(Choice B) HBsAg is the first virological marker detected in the serum after inoculation, preceding both the elevation of serum aminotransferases and the onset of clinical symptoms. It remains detectable during the entire symptomatic phase of acute hepatitis B and suggests infectivity. It is not the most ominous marker in the pregnant woman, however.

(Choice D) Anti-HBc appears in the serum shortly after the emergence of HBsAg and remains detectable long after the patient recovers. The IgM fraction signals the acute phase of disease, whereas the IgG fraction signals recovery from the disease. Because IgM anti-HBc is present in the "window period," it is an important tool for diagnosis when HBsAg has been cleared and anti-HBs is not yet detectable. Thus IgM anti-HBc is the most specific marker for diagnosis of acute hepatitis B.

(Choice E) Anti-HBe suggests the cessation of active viral replication and low infectivity.

(Choice F) Anti-HBsAg IgG appears in the serum after either successful HBV vaccination or the clearance of HBsAg and remains detectable for life. It serves as an indicator of noninfectivity and immunity. However, there is a time lag between the disappearance of HBsAg and the appearance of anti-HBs in the serum, which is termed the "window period."

Educational Objective:
Vertical transmission of hepatitis B from pregnant females to the unborn child can occur in women with active hepatitis B infection. The presence of HBeAg (a marker of viral replication and increased infectivity) in the mother greatly increases the risk of vertical transmission of the virus. Because of this concern, the newborns of all mothers with active hepatitis B are passively immunized at birth with hepatitis B immune globulin (HBIG), followed by active immunization with recombinant HBV vaccine.

Microbiology	Infectious Diseases	Hepatitis b
Subject	System	Topic

Copyright © UWorld. All rights reserved.

A 24-year-old woman comes to the emergency department due to fevers and chills over the last 24 hours. Three weeks ago, she underwent a partial bowel resection for Crohn disease without complications. Since the surgery, the patient has had difficulty eating and has a peripherally inserted central venous catheter in place through which she is receiving parenteral nutrition. Her temperature is 38.2 C (101 F), blood pressure is 100/60 mm Hg, and pulse is 114/min. The surgical wound healed well, and her abdomen is soft and nontender. The catheter site on the left arm is mildly tender but shows no erythema. Chest x-ray reveals a properly positioned central venous line and is otherwise unremarkable. Admission blood cultures subsequently return positive for yeast. Which of the following is characteristic of the most likely organism causing this bloodstream infection?

A. Broad-based budding morphology

B. Dimorphic fungi endemic to southwestern United States

C. Positive India ink stain

D. Pseudohyphae with blastoconidia

E. Right-angle branching hyphae

Submit

A 24-year-old woman comes to the emergency department due to fevers and chills over the last 24 hours. Three weeks ago, she underwent a partial bowel resection for Crohn disease without complications. Since the surgery, the patient has had difficulty eating and has a peripherally inserted central venous catheter in place through which she is receiving parenteral nutrition. Her temperature is 38.2 C (101 F), blood pressure is 100/60 mm Hg, and pulse is 114/min. The surgical wound healed well, and her abdomen is soft and nontender. The catheter site on the left arm is mildly tender but shows no erythema. Chest x-ray reveals a properly positioned central venous line and is otherwise unremarkable. Admission blood cultures subsequently return positive for yeast. Which of the following is characteristic of the most likely organism causing this bloodstream infection?

- A. Broad-based budding morphology (13%)
- B. Dimorphic fungi endemic to southwestern United States (4%)
- C. Positive India ink stain (9%)
- ✓ D. Pseudohyphae with blastoconidia (58%)
- E. Right-angle branching hyphae (13%)

Omitted
Correct answer
D

58%
Answered correctly

02 secs
Time Spent

04/28/2020
Last Updated

Explanation

Characteristics of pathogenic yeasts		
Organism	Morphology	Clinical syndromes

Characteristics of pathogenic yeasts		
Organism	**Morphology**	**Clinical syndromes**
Candida	**Pseudohyphae** with blastoconidia	Wide range of superficial or invasive infections (eg, candidemia attributed to vascular catheters, skin & soft tissue infections)
Blastomyces	Yeast with distinctive **broad-based budding**	Inhaled, can disseminate to skin & bone
Coccidioides	**Spherules** with **endospores**	Typically transient pulmonary syndrome, can progress to meninges & bone; endemic to southwestern United States
Cryptococcus	**Capsule** (India ink stain)	Meningitis among immunocompromised patients (eg, advanced AIDS)
Histoplasma	**Small**, oval yeast within **macrophages**	Most subclinical, can become invasive in immunocompromised patients; endemic to Mississippi & Ohio river valleys

This patient who has a central venous catheter and is receiving parenteral nutrition has sepsis (fever, tachycardia) with blood cultures growing yeast. Patients receiving **parenteral nutrition** (through a central venous **catheter**) are at high risk for **candidemia** (*Candida* in the bloodstream). *Candida* can colonize the catheter, and the lipid emulsion in the parenteral nutrition solution is thought to promote the growth of some *Candida* species. The morphology of *Candida* includes branching pseudohyphae with blastoconidia. Most species are susceptible to echinocandins, and *C albicans* is nearly always susceptible to fluconazole.

(Choice A) Broad-based budding is characteristic of ***Blastomyces***. This organism can cause pulmonary infection and occasional dissemination, but bloodstream infection in the setting of a vascular catheter is unlikely.

(Choice B) *Coccidioides* is a dimorphic fungi endemic to the southwestern United States. This organism is inhaled and can cause pulmonary infection with occasional dissemination, particularly among immunocompromised patients.

(Choice C) *Cryptococcus* is a yeast with a thick capsule that does not absorb India ink, resulting in a clear halo that can aid in the diagnosis of

This patient who has a central venous catheter and is receiving parenteral nutrition has sepsis (fever, tachycardia) with blood cultures growing yeast. Patients receiving **parenteral nutrition** (through a central venous **catheter**) are at high risk for **candidemia** (*Candida* in the bloodstream). *Candida* can colonize the catheter, and the lipid emulsion in the parenteral nutrition solution is thought to promote the growth of some *Candida* species. The morphology of *Candida* includes branching pseudohyphae with blastoconidia. Most species are susceptible to echinocandins, and *C albicans* is nearly always susceptible to fluconazole.

(Choice A) Broad-based budding is characteristic of ***Blastomyces***. This organism can cause pulmonary infection and occasional dissemination, but bloodstream infection in the setting of a vascular catheter is unlikely.

(Choice B) *Coccidioides* is a dimorphic fungi endemic to the southwestern United States. This organism is inhaled and can cause pulmonary infection with occasional dissemination, particularly among immunocompromised patients.

(Choice C) *Cryptococcus* is a yeast with a thick capsule that does not absorb India ink, resulting in a clear halo that can aid in the diagnosis of cryptococcal infection. The most common cryptococcal infection is meningitis, particularly among immunocompromised patients. Fungemia in the setting of a vascular catheter is uncommon.

(Choice E) Right-angle branching hyphae are characteristic of mucormycosis, a mold infection primarily due to *Mucorales* or *Rhizopus* species. These infections can cause invasive disease in immunocompromised patients, including angioinvasive infections, but the organisms do not grow in blood cultures and are not associated with intravascular catheters.

Educational objective:
The presence of a central vascular catheter and receipt of parenteral nutrition are risk factors for candidemia. *Candida* display a morphology of branching pseudohyphae with blastoconidia.

References

- British Society for Medical Mycology best practice recommendations for the diagnosis of serious fungal diseases.
- Epidemiology of invasive mycoses in North America.

Microbiology	Infectious Diseases	Catheter related bloodstream infection
Subject	System	Topic

1
2
3
4
5
6
7
8
9
10
11
12
13
14
15
16
17
18
19
20
21
22
23
24
25
26
27
28
29
30
31

Exhibit Display

Zoom In | Zoom Out | Reset | Add To New Card | Existing Card

Subject System Topic

1
2
3
4
5
6
7
8
9
10
11
12
13
14
15
16
17
18
19
20
21
22
23
24
25
26
27
28
29
30
31

Exhibit Display

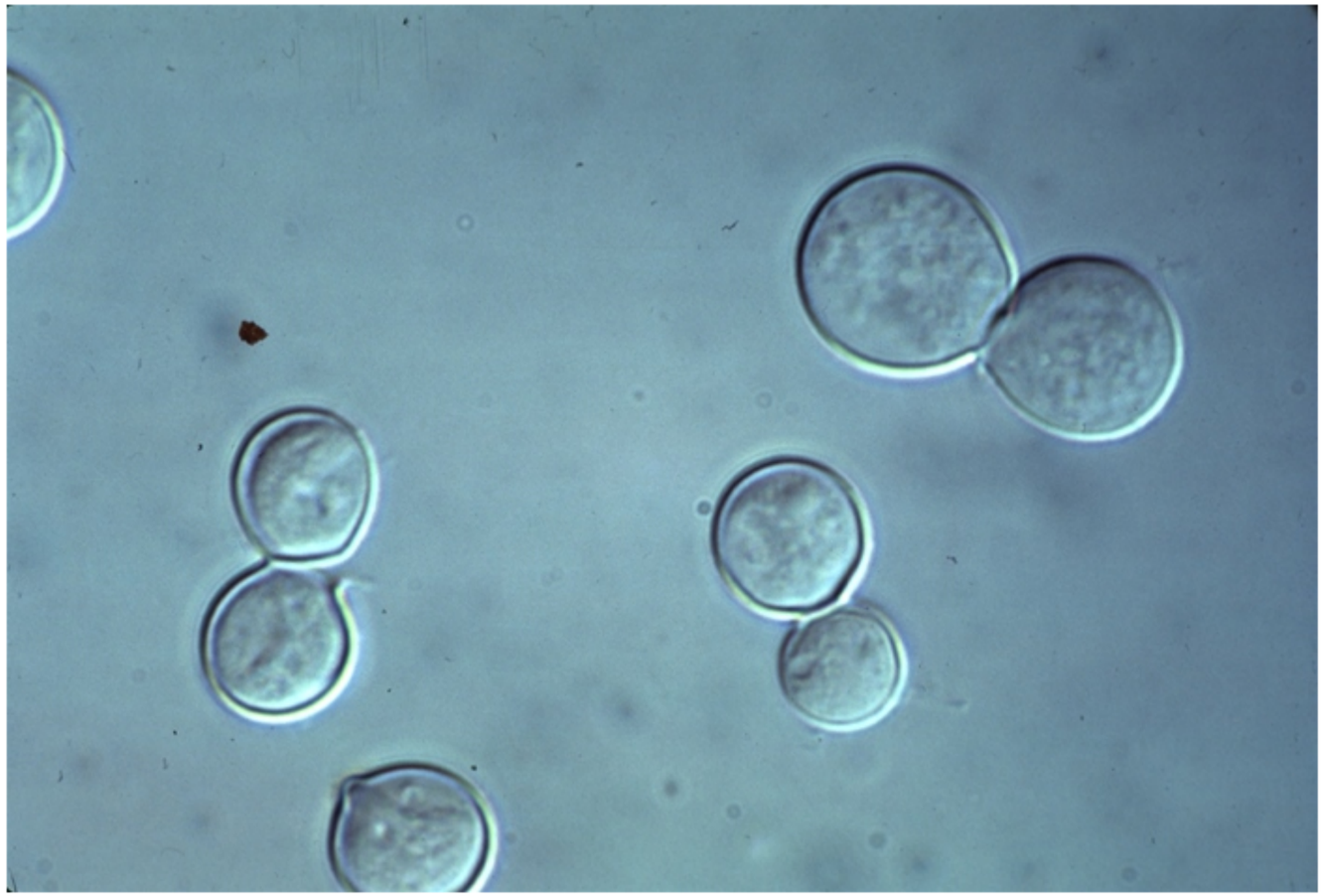

Zoom In | Zoom Out | Reset | Add To New Card | Existing Card

Subject System Topic

1
2
3
4
5
6
7
8
9
10
11
12
13
14
15
16
17
18
19
20
21
22
23
24
25
26
27
28
29
30
31

Exhibit Display

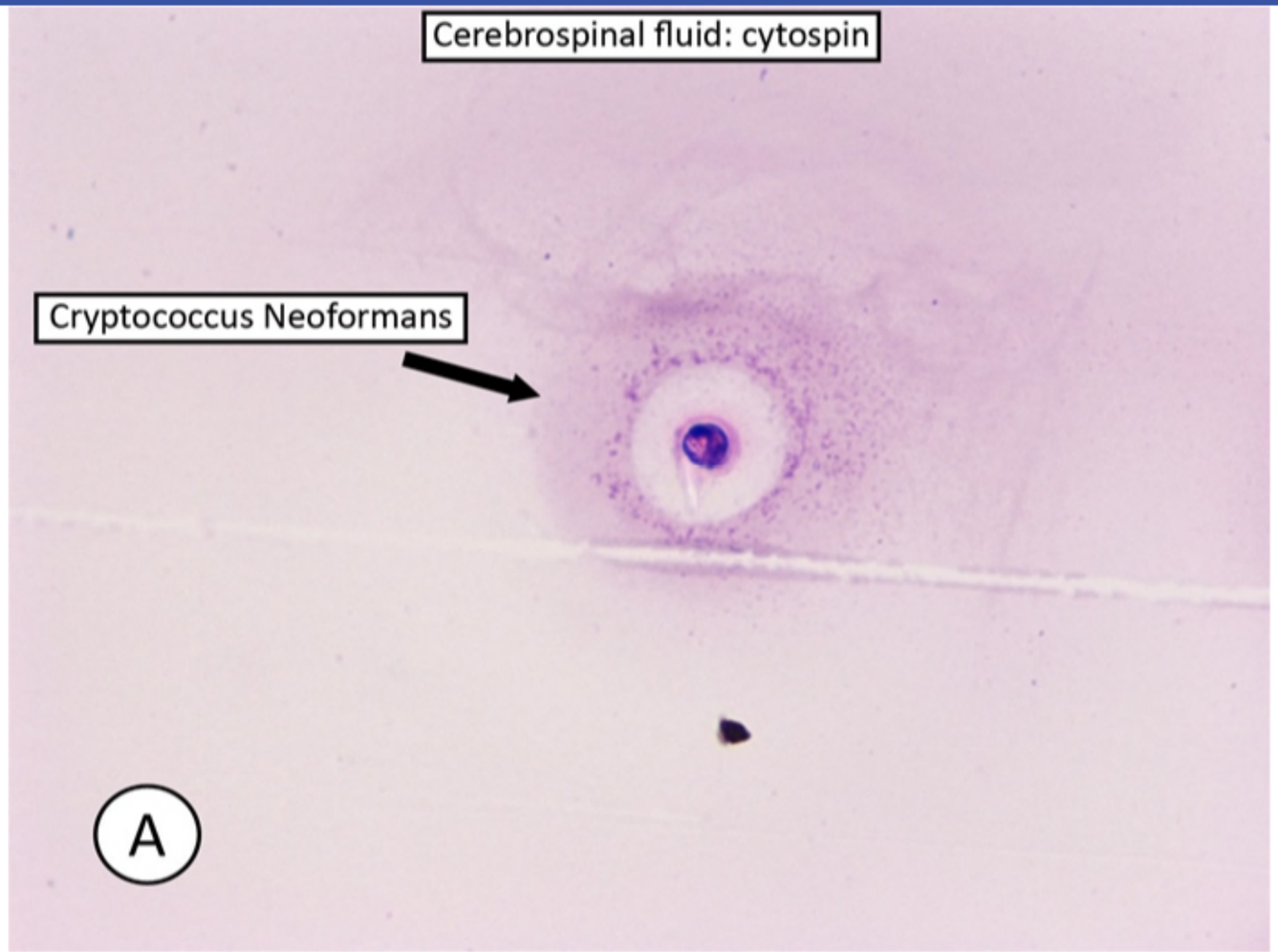

Zoom In | Zoom Out | Reset | Add To New Card | Existing Card

Subject System Topic

1
2
3
4
5
6
7
8
9
10
11
12
13
14
15
16
17
18
19
20
21
22
23
24
25
26
27
28
29
30
31

Exhibit Display

Invasive fungal sinusitis due to mucormycosis (zygomycosis)

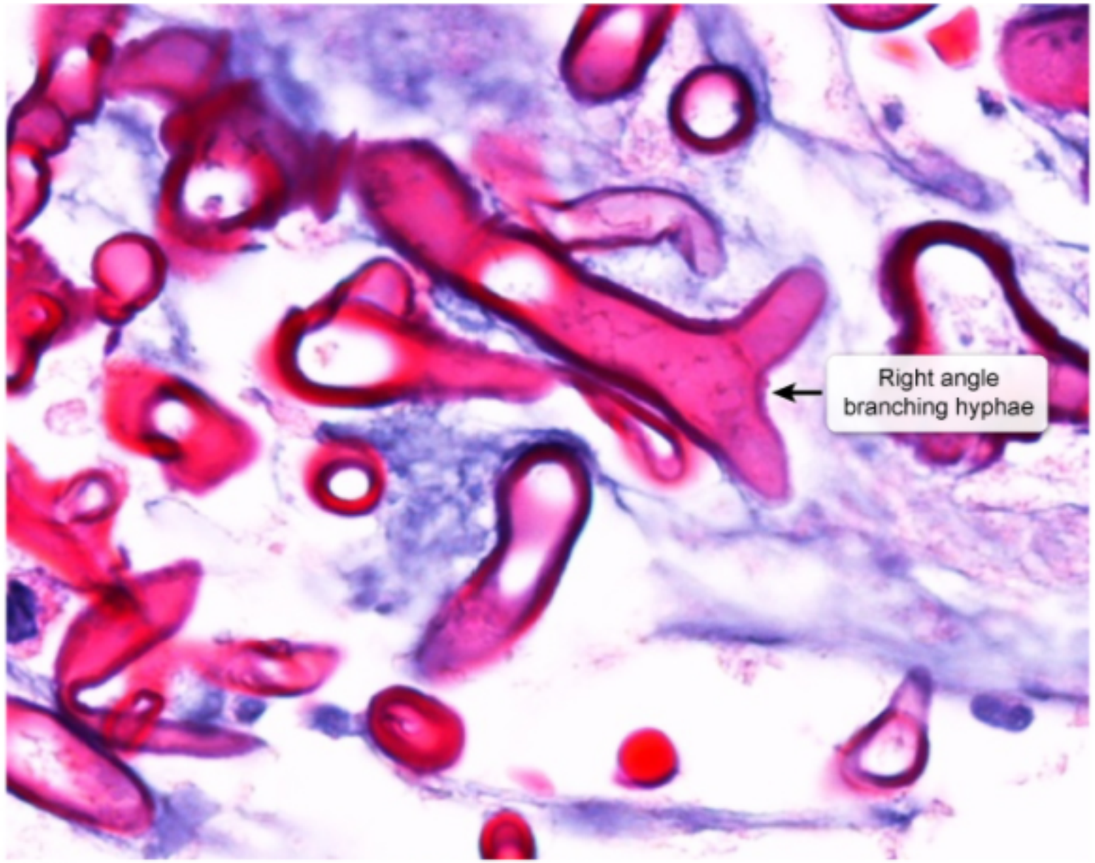

©UWorld

Zoom In | Zoom Out | Reset | Add To New Card | Existing Card

Subject System Topic

A 38-year-old man is undergoing treatment for acute myelogenous leukemia. Initially, he complained of fevers and being lethargic and fatigued all the time. However, of late, he has noted increasingly severe right-sided headaches. He describes the pain to be throbbing in nature and located behind his right eye, which is also associated with nasal stuffiness. The patient denies any previous history of allergies. Physical examination reveals right-sided proptosis and periorbital tenderness. Biopsy of the right maxillary sinus mucosa reveals the following:

Which of the following is the most likely cause of this patient's condition?

- A. *Malassezia furfur*
- B. *Microsporum canis*
- C. *Rhizopus* species
- D. *Aspergillus fumigatus*
- E. *Candida albicans*
- F. *Cryptococcus neoformans*
- G. *Blastomyces dermatitidis*
- H. *Histoplasma capsulatum*
- I. *Coccidioides immitis*
- J. *Sporothrix schenckii*

Submit

1
2
3
4
5
6
7
8
9
10
11
12
13
14
15
16
17
18
19
20
21
22
23
24
25
26
27
28
29
30
31

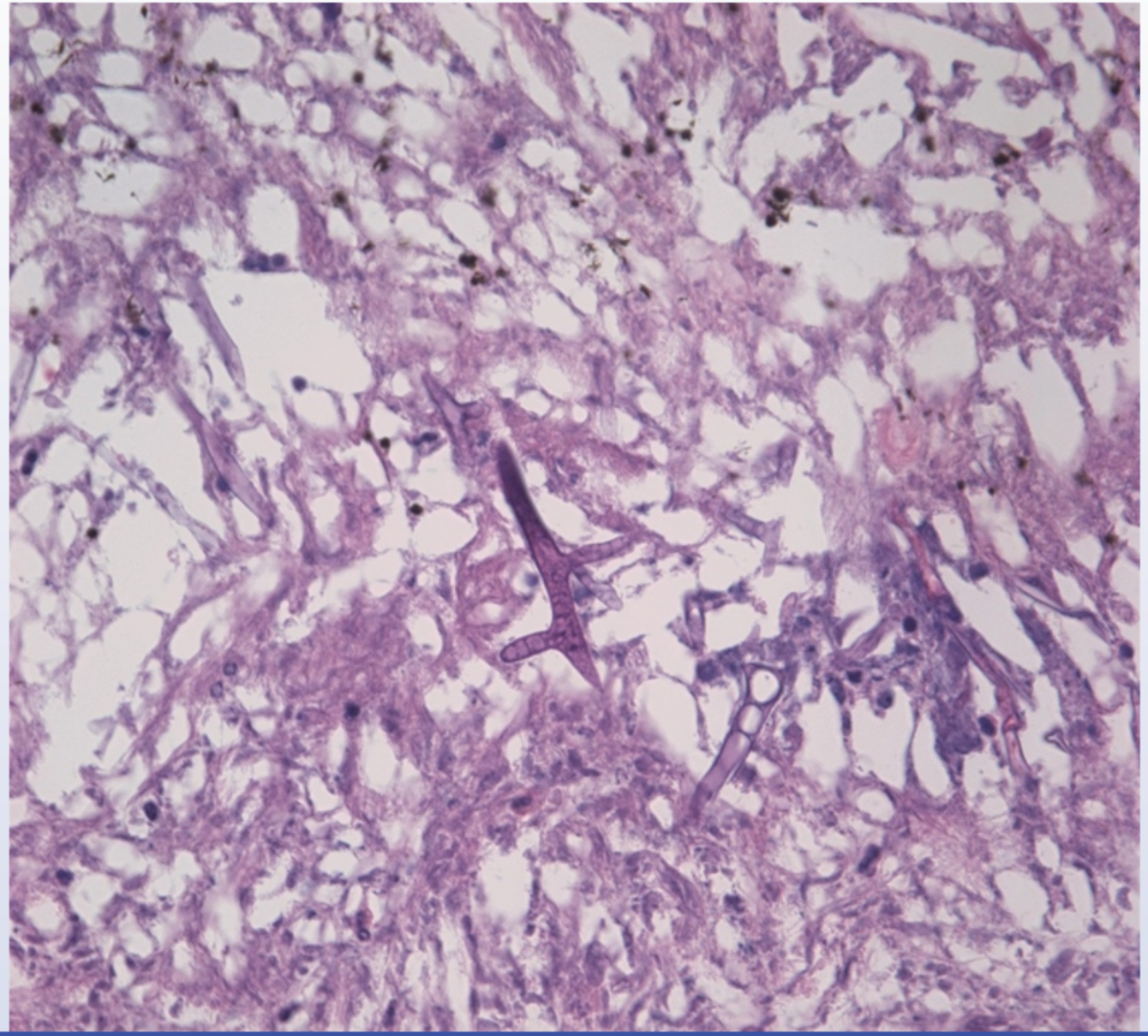

1
2
3
4
5
6
7
8
9
10
11
12
13
14
15
16
17
18
19
20
21
22
23
24
25
26
27
28
29
30
31

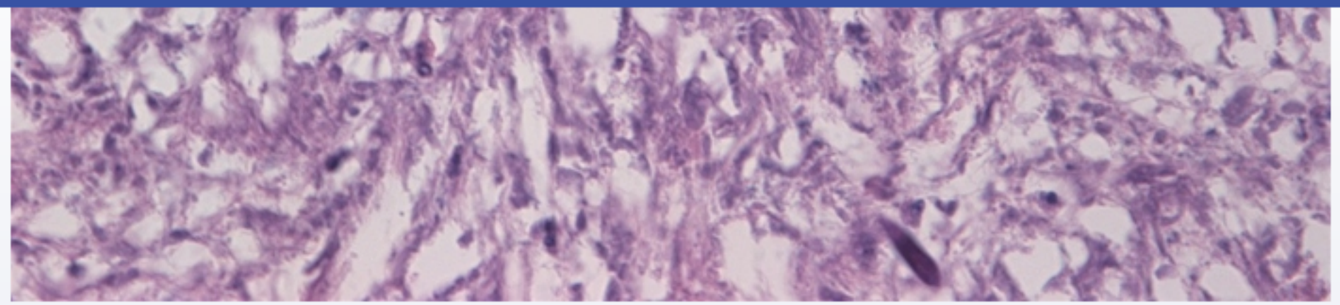

Which of the following is the most likely cause of this patient's condition?

A. *Malassezia furfur*

B. *Microsporum canis*

C. *Rhizopus* species

D. *Aspergillus fumigatus*

E. *Candida albicans*

F. *Cryptococcus neoformans*

G. *Blastomyces dermatitidis*

H. *Histoplasma capsulatum*

I. *Coccidioides immitis*

J. *Sporothrix schenckii*

Submit

1
2
3
4
5
6
7
8
9
10
11
12
13
14
15
16
17
18
19
20
21
22
23
24
25
26
27
28
29
30
31

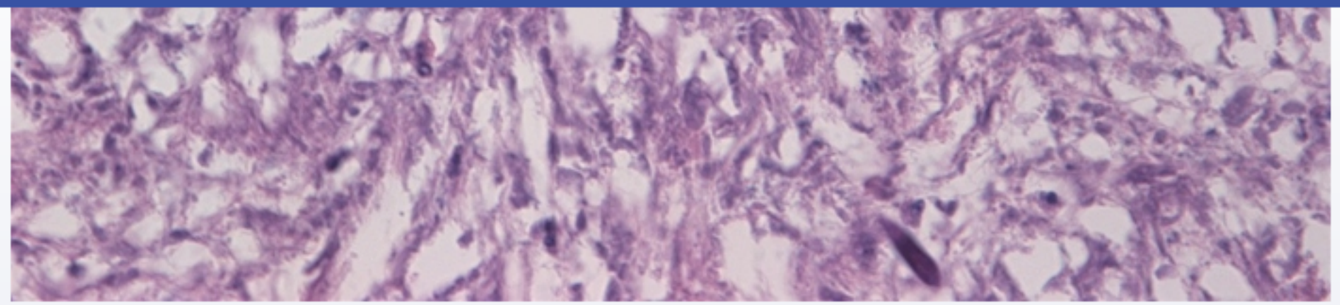

Which of the following is the most likely cause of this patient's condition?

A. *Malassezia furfur* (2%)

B. *Microsporum canis* (0%)

✓ C. *Rhizopus* species (73%)

D. *Aspergillus fumigatus* (13%)

E. *Candida albicans* (2%)

F. *Cryptococcus neoformans* (2%)

G. *Blastomyces dermatitidis* (1%)

H. *Histoplasma capsulatum* (0%)

I. *Coccidioides immitis* (0%)

J. *Sporothrix schenckii* (0%)

Omitted
Correct answer

73%
Answered correctly

08 secs
Time Spent

04/01/2020
Last Updated

1
2
3
4
5
6
7
8
9
10
11
12
13
14
15
16
17
18
19
20
21
22
23
24
25
26
27
28
29
30
31

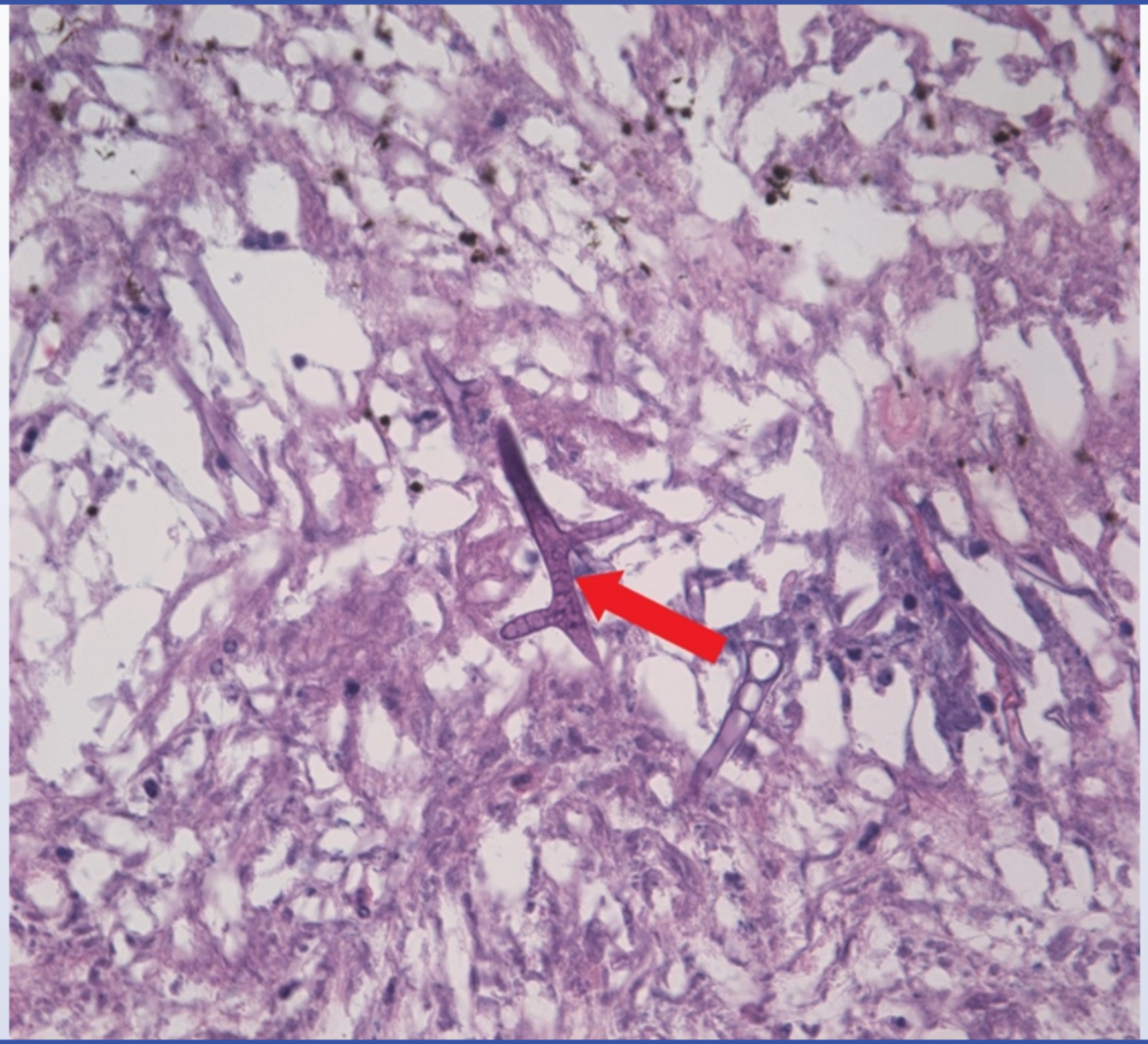

Mucor, *Rhizopus*, and *Absidia* species are saprophytic fungi present in the environment. They are transmitted by spore inhalation and cause **mucormycosis**. Mucormycosis is very strongly associated with diabetic ketoacidosis. Patients with underlying immunosuppression (eg, due to solid organ transplantation, hematologic malignancies, or glucocorticoid therapy) are also at high risk.

Mucormycosis tends to affect the paranasal sinuses. Patients complain of facial and periorbital pain, headache, and purulent nasal discharge. The fungi proliferate in the walls of blood vessels and cause necrosis of the corresponding tissue. Black eschar (necrotic tissue) may be seen on the palate or nasal turbinates.

Mucormycosis is diagnosed by light microscopy of a tissue specimen. *Mucor*, *Rhizopus*, and *Absidia* fungi exist in mold form only. They form broad, nonseptate hyphae that branch at wide, often 90° angles (arrow). Mucormycosis is treated by surgical debridement of necrotic tissue and amphotericin B.

(Choices A and B) *Malassezia furfur* and *Microsporum canis* cause cutaneous mycoses and do not affect the paranasal sinuses.

(Choice D) Invasive aspergillosis involving the paranasal sinuses can show close clinical resemblance to mucormycosis. Light microscopy of the affected tissue will differentiate these two diagnoses. Unlike *Mucor* and *Rhizopus*, *Aspergillus* has septate hyphae that branch at 45° angles (V-shaped branching).

(Choice E) *Candida albicans* can cause a variety of symptoms in immunosuppressed patients. Right-sided endocarditis, renal abscesses, pneumonia, and esophagitis are among the most common. Budding yeasts and pseudohyphae are seen on light microscopy.

(Choices G, H, and I) *Blastomyces*, *Histoplasma*, and *Coccidioides* cause lung disease in healthy patients. Disseminated disease occurs in immunosuppressed individuals. Isolated paranasal involvement is not typical.

Educational objective:
Mucormycosis is an opportunistic infection caused by *Rhizopus*, *Mucor*, and *Absidia* species. The classic clinical picture is paranasal sinus involvement in a diabetic or immunosuppressed patient. The fungi form broad nonseptate hyphae that branch at right angles.

References

- Mucormycosis in hematologic malignancies: an emerging fungal infection.

1
2
3
4
5
6
7
8
9
10
11
12
13
14
15
16
17
18
19
20
21
22
23
24
25
26
27
28
29
30
31

Exhibit Display

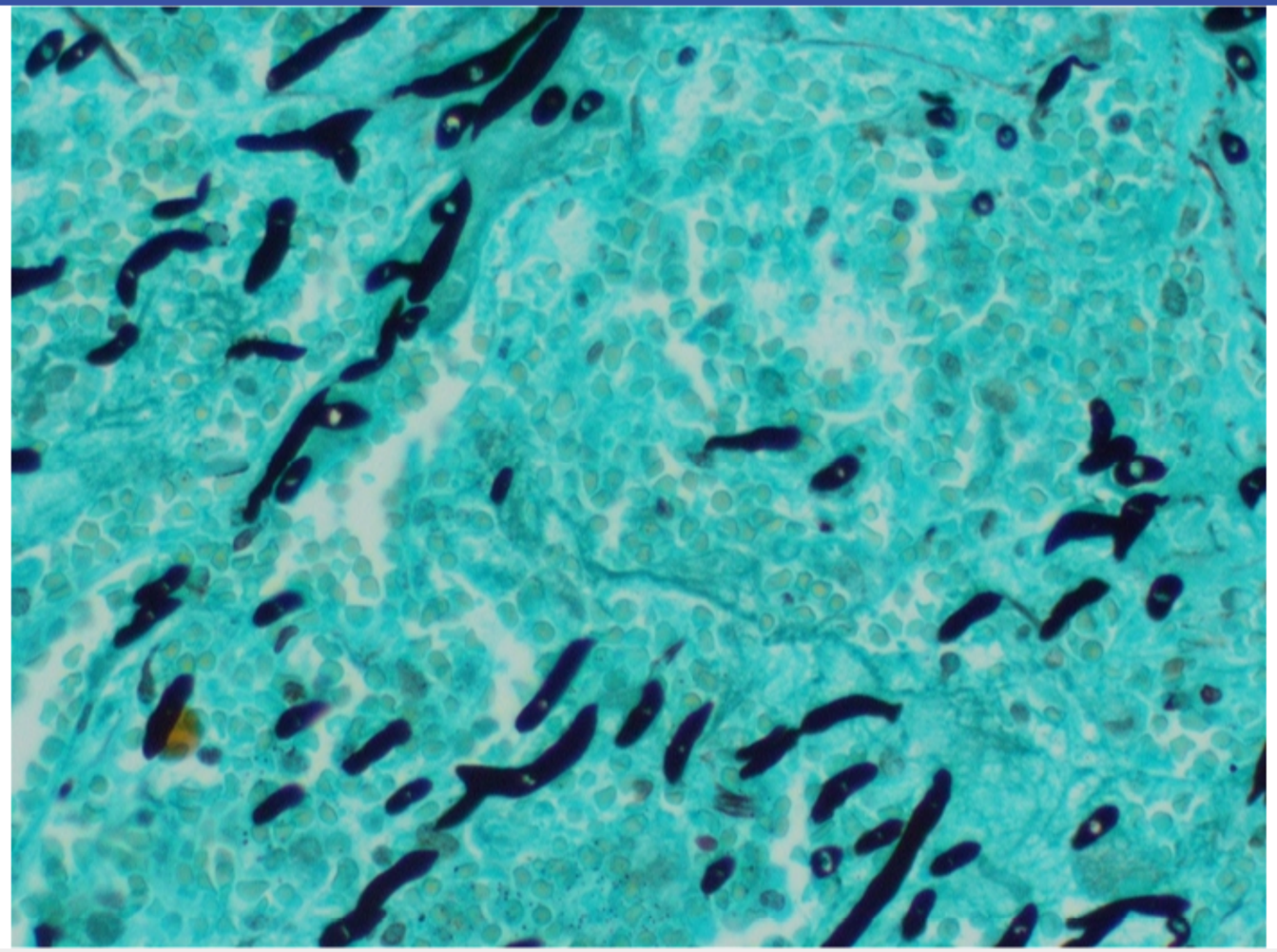

Zoom In | Zoom Out | Reset | Add To New Card | Existing Card

1
2
3
4
5
6
7
8
9
10
11
12
13
14
15
16
17
18
19
20
21
22
23
24
25
26
27
28
29
30
31

A 4-year-old boy is brought to the office with 3 days of fever, irritability, and oral lesions. His parents are concerned due to his refusal to eat or drink and lack of urination today. Physical examination demonstrates painful ulcers on the tongue and gingiva, swollen gums, and cervical lymphadenopathy. The remainder of his examination is unremarkable. Microscopic examination of an oral ulcer base scraping is shown in the image below.

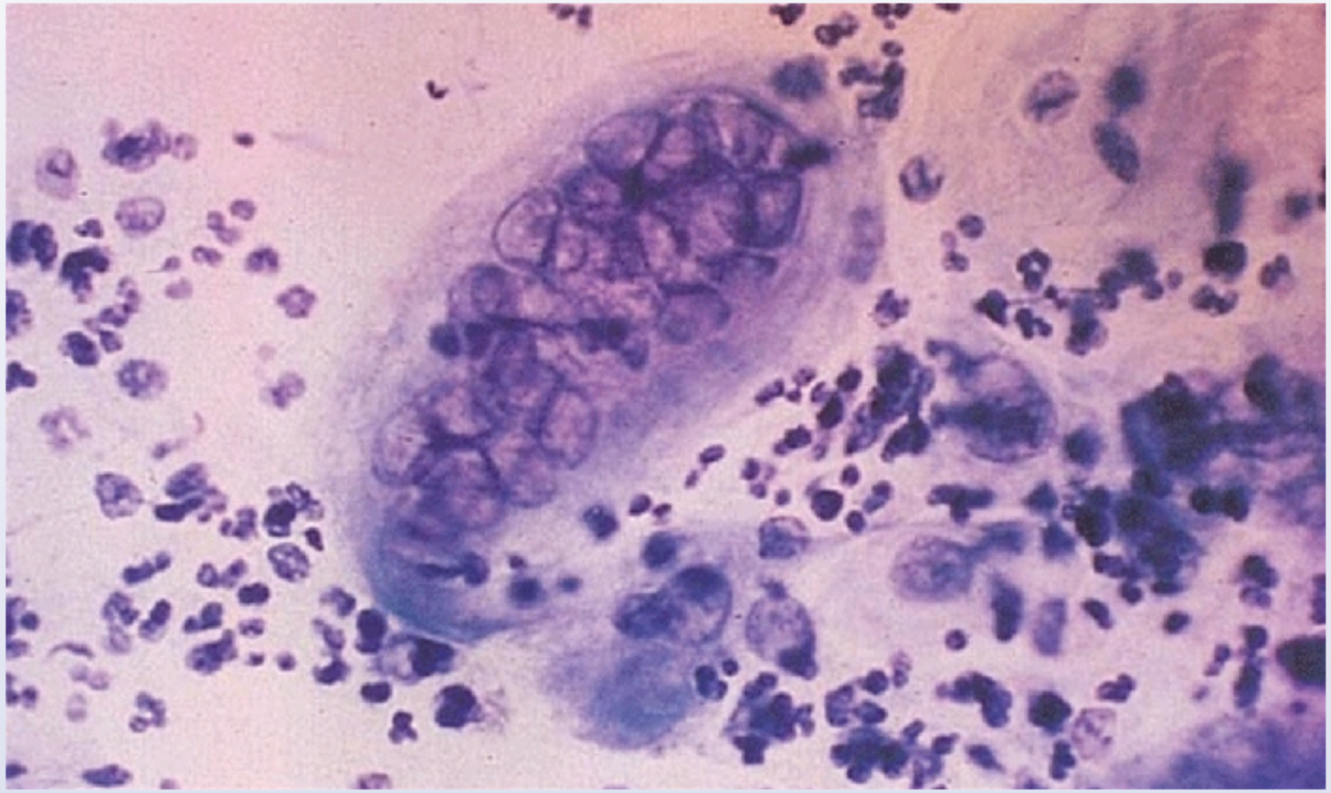

Which of the following is most likely the cause of this patient's condition?

A. Abortive infection

B. Latent infection

1
2
3
4
5
6
7
8
9
10
11
12
13
14
15
16
17
18
19
20
21
22
23
24
25
26
27
28
29
30
31

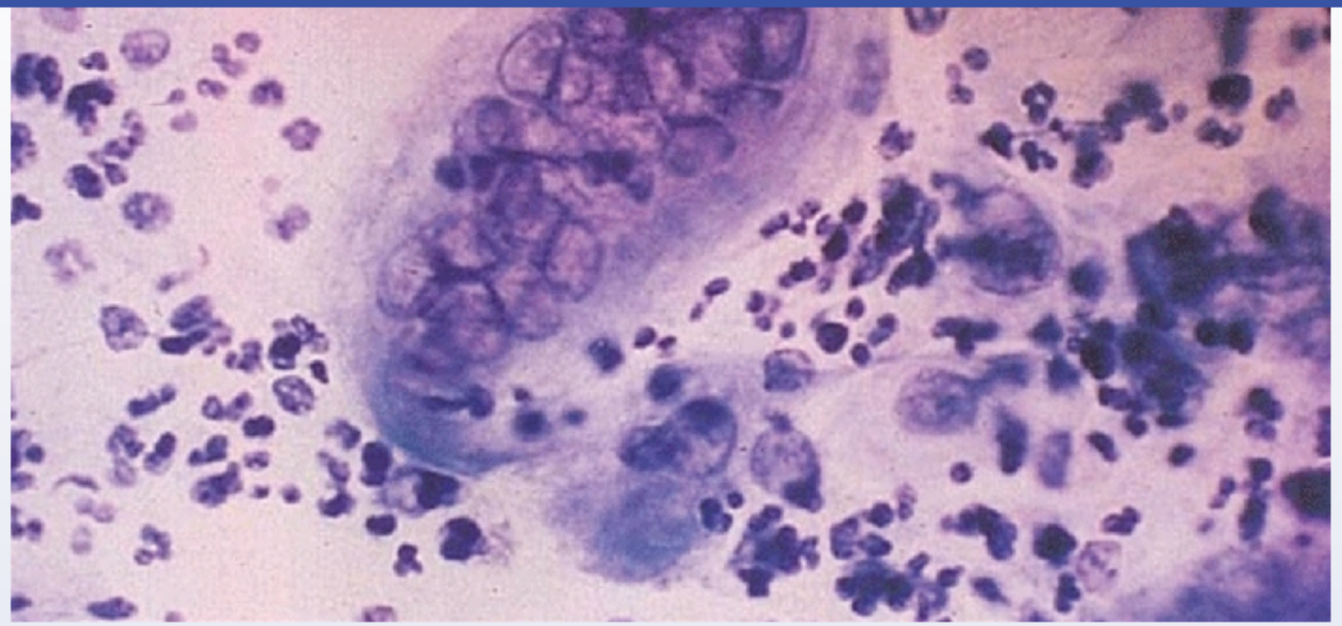

Which of the following is most likely the cause of this patient's condition?

- A. Abortive infection
- B. Latent infection
- C. Primary infection
- D. Slow virus infection
- E. Virus reactivation

Submit

1
2
3
4
5
6
7
8
9
10
11
12
13
14
15
16
17
18
19
20
21
22
23
24
25
26
27
28
29
30
31

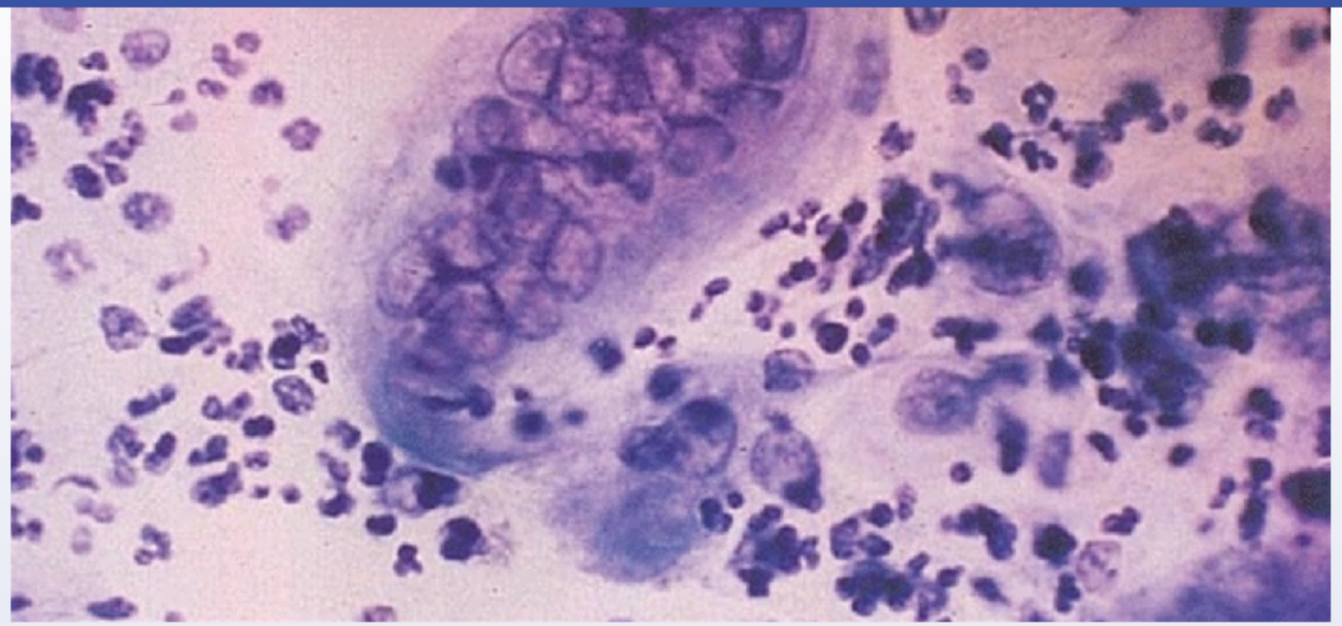

Which of the following is most likely the cause of this patient's condition?

A. Abortive infection (1%)

B. Latent infection (9%)

✓ C. Primary infection (67%)

D. Slow virus infection (3%)

E. Virus reactivation (17%)

Omitted
Correct answer

67%
Answered correctly

11 secs
Time Spent

02/25/2020
Last Updated

1
2
3
4
5
6
7
8
9
10
11
12
13
14
15
16
17
18
19
20
21
22
23
24
25
26
27
28
29
30
31

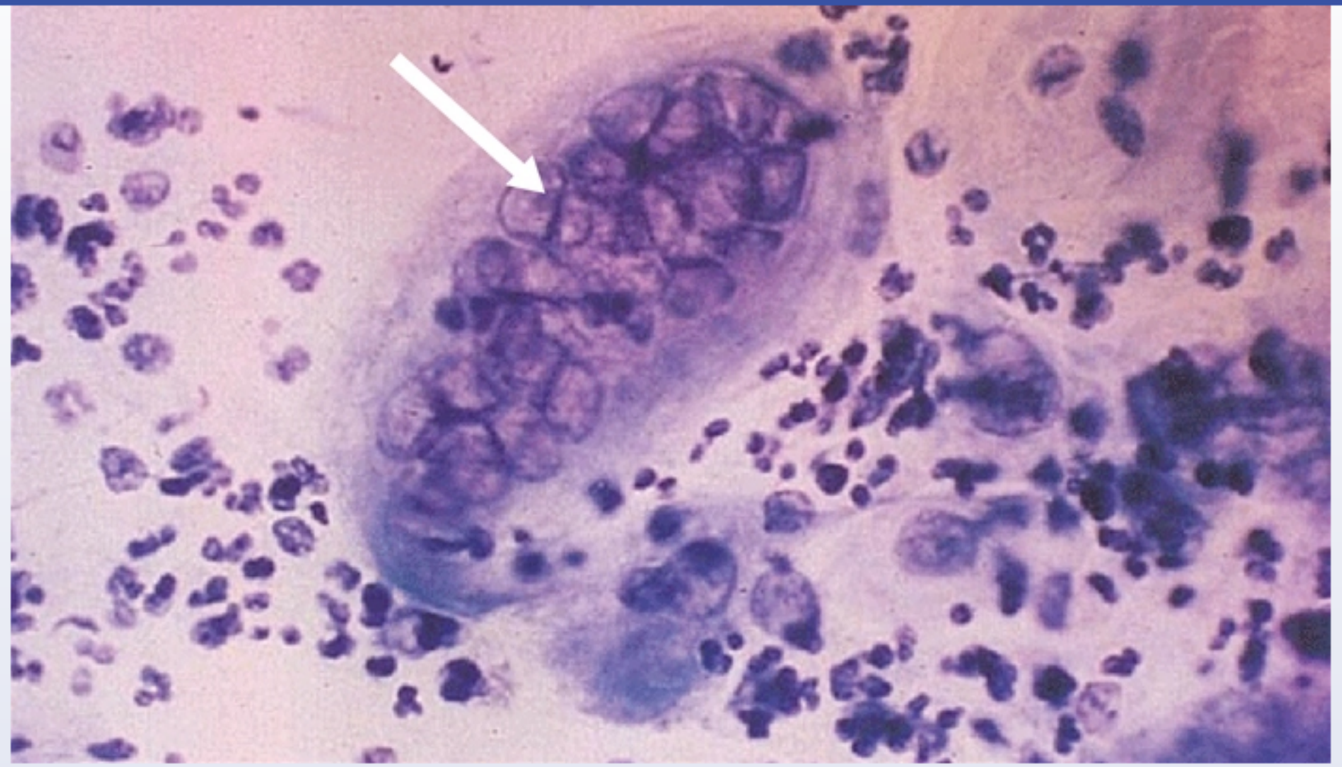

The above image depicts a **Tzanck smear**, in which epithelial cells are scraped from an ulcer base and stained. The presence of **multinucleated giant cells** (white arrow) is suggestive of **herpes simplex virus** (HSV) infection, which is consistent with this child's symptoms. Tzanck smears are insensitive and do not differentiate between HSV and varicella-zoster virus infection. Therefore, Tzanck smears largely have been replaced by polymerase chain reaction testing.

Primary infection with HSV-1 results in herpetic **gingivostomatitis**. Peak age for primary infection is age 6 months to 5 years. Prodromal symptoms (eg, fever, malaise, chills) begin approximately 1 week after contact with an infected person (who is generally asymptomatic). Painful **vesicles** appear, extensively covering the lips and gingiva, and may include the palate, tongue, or oropharynx. The vesicles organize into extensive ulcers and resolve within 1-2 weeks. The pain of gingivostomatitis often results in **dehydration**, the most common reason for hospitalization.

The above image depicts a **Tzanck smear**, in which epithelial cells are scraped from an ulcer base and stained. The presence of **multinucleated giant cells** (white arrow) is suggestive of **herpes simplex virus** (HSV) infection, which is consistent with this child's symptoms. Tzanck smears are insensitive and do not differentiate between HSV and varicella-zoster virus infection. Therefore, Tzanck smears largely have been replaced by polymerase chain reaction testing.

Primary infection with HSV-1 results in herpetic **gingivostomatitis**. Peak age for primary infection is age 6 months to 5 years. Prodromal symptoms (eg, fever, malaise, chills) begin approximately 1 week after contact with an infected person (who is generally asymptomatic). Painful **vesicles** appear, extensively covering the lips and gingiva, and may include the palate, tongue, or oropharynx. The vesicles organize into extensive ulcers and resolve within 1-2 weeks. The pain of gingivostomatitis often results in **dehydration**, the most common reason for hospitalization.

(Choice A) An abortive viral infection refers to an infection in which the virus enters the cell but does not successfully produce new infective virus. Therefore, an abortive infection is not capable of causing disease.

(Choice B) HSV is capable of latency by integrating into the trigeminal (or sacral, for HSV-2) ganglia. However, during latency no virus is produced and therefore no clinical disease occurs.

(Choice D) A slow virus infection is characterized by a prolonged incubation period that lasts months to years. During this time, the virus gradually multiplies before finally causing clinically apparent disease. Slow virus infections are predominantly progressive, degenerative disorders of the central nervous system (eg, subacute sclerosing panencephalitis following measles infection).

(Choice E) Reactivation of HSV from the trigeminal ganglia causes herpes labialis. In contrast to gingivostomatitis, recurrent labialis disease is usually mild, unilateral, and limited to the lips.

Educational objective:
Herpetic gingivostomatitis is a severe vesicular or ulcerative disease following primary infection with herpes simplex virus type 1. Involvement of the gingiva, tongue, palate, and pharynx along with systemic symptoms (eg, fever, malaise) is common. In contrast, reactivation of a latent herpes infection in the trigeminal ganglia generally results in mild perioral vesicles.

References

- Acute primary herpetic gingivostomatitis.

Primary infection with HSV-1 results in herpetic **gingivostomatitis**. Peak age for primary infection is age 6 months to 5 years. Prodromal symptoms (eg, fever, malaise, chills) begin approximately 1 week after contact with an infected person (who is generally asymptomatic). Painful **vesicles** appear, extensively covering the lips and gingiva, and may include the palate, tongue, or oropharynx. The vesicles organize into extensive ulcers and resolve within 1-2 weeks. The pain of gingivostomatitis often results in **dehydration**, the most common reason for hospitalization.

(Choice A) An abortive viral infection refers to an infection in which the virus enters the cell but does not successfully produce new infective virus. Therefore, an abortive infection is not capable of causing disease.

(Choice B) HSV is capable of latency by integrating into the trigeminal (or sacral, for HSV-2) ganglia. However, during latency no virus is produced and therefore no clinical disease occurs.

(Choice D) A slow virus infection is characterized by a prolonged incubation period that lasts months to years. During this time, the virus gradually multiplies before finally causing clinically apparent disease. Slow virus infections are predominantly progressive, degenerative disorders of the central nervous system (eg, subacute sclerosing panencephalitis following measles infection).

(Choice E) Reactivation of HSV from the trigeminal ganglia causes herpes labialis. In contrast to gingivostomatitis, recurrent labialis disease is usually mild, unilateral, and limited to the lips.

Educational objective:
Herpetic gingivostomatitis is a severe vesicular or ulcerative disease following primary infection with herpes simplex virus type 1. Involvement of the gingiva, tongue, palate, and pharynx along with systemic symptoms (eg, fever, malaise) is common. In contrast, reactivation of a latent herpes infection in the trigeminal ganglia generally results in mild perioral vesicles.

References

- Acute primary herpetic gingivostomatitis.

Microbiology	Infectious Diseases	HSV infection
Subject	System	Topic

Copyright © UWorld. All rights reserved.

A 20-year-old woman comes to the urgent care center due to 3 days of vaginal pain with intercourse and dysuria. She also had low-grade fevers and a mild headache. The patient is otherwise healthy and takes oral contraceptives only. She has no history of urinary tract infections or sexually transmitted infections. She is sexually active and recently began a monogamous relationship with a new partner. Her boyfriend uses condoms inconsistently. On examination, she is afebrile. She is uncomfortable, but in no acute distress. Her abdomen is soft and nontender. Genital examination reveals multiple, painful, shallow ulcers with an erythematous base on the left labia. There is no vaginal discharge. Internal examination reveals no cervical motion tenderness. She has bilateral tender inguinal lymphadenopathy. Which of the following is the best diagnostic test for this patient's condition?

A. Darkfield microscopy
B. Gram stain of the ulcer swab
C. Lymph node biopsy
D. Polymerase chain reaction for viral DNA
E. Potassium hydroxide preparation

Submit

A 20-year-old woman comes to the urgent care center due to 3 days of vaginal pain with intercourse and dysuria. She also had low-grade fevers and a mild headache. The patient is otherwise healthy and takes oral contraceptives only. She has no history of urinary tract infections or sexually transmitted infections. She is sexually active and recently began a monogamous relationship with a new partner. Her boyfriend uses condoms inconsistently. On examination, she is afebrile. She is uncomfortable, but in no acute distress. Her abdomen is soft and nontender. Genital examination reveals multiple, painful, shallow ulcers with an erythematous base on the left labia. There is no vaginal discharge. Internal examination reveals no cervical motion tenderness. She has bilateral tender inguinal lymphadenopathy. Which of the following is the best diagnostic test for this patient's condition?

- A. Darkfield microscopy (10%)
- B. Gram stain of the ulcer swab (18%)
- C. Lymph node biopsy (3%)
- ✓ D. Polymerase chain reaction for viral DNA (65%)
- E. Potassium hydroxide preparation (2%)

Omitted
Correct answer
D

65%
Answered correctly

02 secs
Time Spent

06/02/2020
Last Updated

Explanation

Genital ulcer disease				
	Syphilis	Genital herpes	Chancroid	Granuloma inguinale

Genital ulcer disease				
	Syphilis	**Genital herpes**	**Chancroid**	**Granuloma inguinale (donovanosis)**
Causative agent	*Treponema pallidum*	Herpes simplex virus	*Haemophilus ducreyi*	*Klebsiella granulomatis*
Description	Single, **painless** ulcer at inoculation site with heaped-up borders & clean base	Multiple, **painfulsuperficialvesicles** or **ulcerations** with erythematous base	**Deep**, **purulent**, painful ulcers with matted/**suppurative** lymphadenitis	**Painless**, progressive, red serpiginous ulcerative lesions **without** lymphadenopathy
Diagnostic tests	• VDRL/RPR • Dark-field microscopy	• PCR • Tzanck smear	• Gram stain & culture • PCR	• Gram stain & culture (difficult) • Biopsy (Donovan bodies)

PCR = polymerase chain reaction; **RPR** = rapid plasma reagin; **VDRL** = Venereal Disease Research Laboratory.

Primary genital **herpes simplex virus (HSV)** infection is the most likely diagnosis in this patient who has **multiple painful** genital ulcers (with a characteristic erythematous base), dysuria (likely due to irritation from the ulcers), tender lymphadenopathy (common with primary genital HSV infection), and **systemic** symptoms (fever, headache) in the setting of having a new sexual partner. The characteristic **vesicles** are often **absent**. HSV infection can be diagnosed using polymerase chain reaction (PCR), direct fluorescence antibody, viral culture (low sensitivity), or Tzanck smear (showing multinucleated giant cells).

(Choice A) Darkfield microscopy can be used to diagnose syphilis, which typically presents with painless ulcerations (chancre).

(Choice B) Gonorrhea, caused by *Neisseria gonorrhoeae*, is a common cause of urethritis, cervicitis, and pelvic inflammatory disease in sexually active females. Gram stain can reveal gram-negative diplococci. Chancroid (due to *Haemophilus ducreyi*) presents with purulent ulcers with "ragged" borders and suppurative lymphadenopathy. Gram stain may occasionally reveal gram-negative rods in a "school of fish" chain.

(Choice C) Lymph node biopsy is a relatively invasive procedure typically used to exclude malignancy or certain infections such as tuberculosis

characteristic erythematous base), dysuria (likely due to irritation from the ulcers), tender lymphadenopathy (common with primary genital HSV infection), and **systemic** symptoms (fever, headache) in the setting of having a new sexual partner. The characteristic **vesicles** are often **absent**. HSV infection can be diagnosed using polymerase chain reaction (PCR), direct fluorescence antibody, viral culture (low sensitivity), or Tzanck smear (showing multinucleated giant cells).

(Choice A) Darkfield microscopy can be used to diagnose syphilis, which typically presents with painless ulcerations (chancre).

(Choice B) Gonorrhea, caused by *Neisseria gonorrhoeae*, is a common cause of urethritis, cervicitis, and pelvic inflammatory disease in sexually active females. Gram stain can reveal gram-negative diplococci. Chancroid (due to *Haemophilus ducreyi*) presents with purulent ulcers with "ragged" borders and suppurative lymphadenopathy. Gram stain may occasionally reveal gram-negative rods in a "school of fish" chain.

(Choice C) Lymph node biopsy is a relatively invasive procedure typically used to exclude malignancy or certain infections such as tuberculosis. Biopsies of genital lesions may be performed if the diagnosis is unclear or if there is no response to initial treatment.

(Choice E) Potassium hydroxide testing can be used to identify *Candida* infections, including vulvovaginitis. However, this condition typically presents with a white discharge, not genital ulcers.

Educational objective:
The finding of multiple painful genital ulcers and constitutional symptoms in a sexually active patient is highly suggestive of primary genital herpes simplex virus infection. Diagnosis can be established by polymerase chain reaction testing, direct fluorescence antibody testing, viral culture, or Tzanck smear.

References

- Genital Herpes: A Review
- Update on Genital Lesions

Microbiology	Infectious Diseases	HSV infection
Subject	System	Topic

Copyright © UWorld. All rights reserved.

The influenza A virus uses a sialic acid as a receptor for cellular entry. The chemical composition of the specific type of sialic acid that the virus interacts with differs among animal species. The avian influenza virus attaches to a specific sialic acid that is present in fowl epithelial cells but absent in human cells, whereas the human influenza virus can only attach to the type of sialic acid present in human respiratory epithelium. When pig epithelial cells, which contain both types of sialic acid, are infected with the combination of avian and human influenza A viruses, some of the new avian influenza viral particles become capable of attaching to human cells. However, the progeny of this new strain of avian influenza virus is still unable to attach to human epithelial cells. Which of the following phenomena best describes the change in the avian influenza virus in this experiment?

A. Interference
B. Phenotypic mixing
C. Reassortment
D. Recombination
E. Transformation

Submit

The influenza A virus uses a sialic acid as a receptor for cellular entry. The chemical composition of the specific type of sialic acid that the virus interacts with differs among animal species. The avian influenza virus attaches to a specific sialic acid that is present in fowl epithelial cells but absent in human cells, whereas the human influenza virus can only attach to the type of sialic acid present in human respiratory epithelium. When pig epithelial cells, which contain both types of sialic acid, are infected with the combination of avian and human influenza A viruses, some of the new avian influenza viral particles become capable of attaching to human cells. However, the progeny of this new strain of avian influenza virus is still unable to attach to human epithelial cells. Which of the following phenomena best describes the change in the avian influenza virus in this experiment?

- A. Interference (1%)
- ✓ B. Phenotypic mixing (42%)
- C. Reassortment (32%)
- D. Recombination (12%)
- E. Transformation (9%)

Omitted
Correct answer
B

42%
Answered correctly

02 secs
Time Spent

01/30/2020
Last Updated

Explanation

Phenotypic mixing

Virus A Virus B

1
2
3
4
5
6
7
8
9
10
11
12
13
14
15
16
17
18
19
20
21
22
23
24
25
26
27
28
29
30
31

Phenotypic mixing

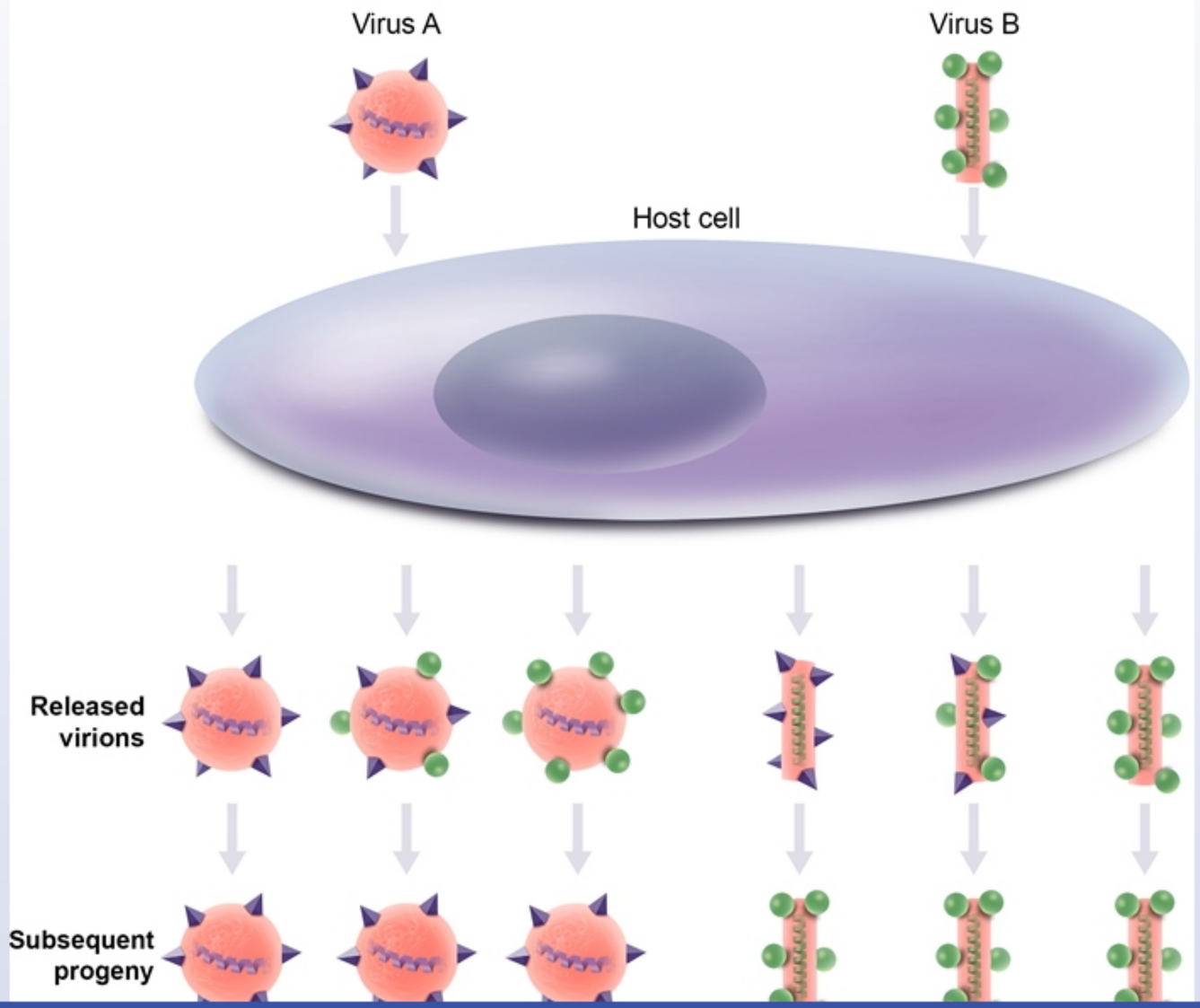

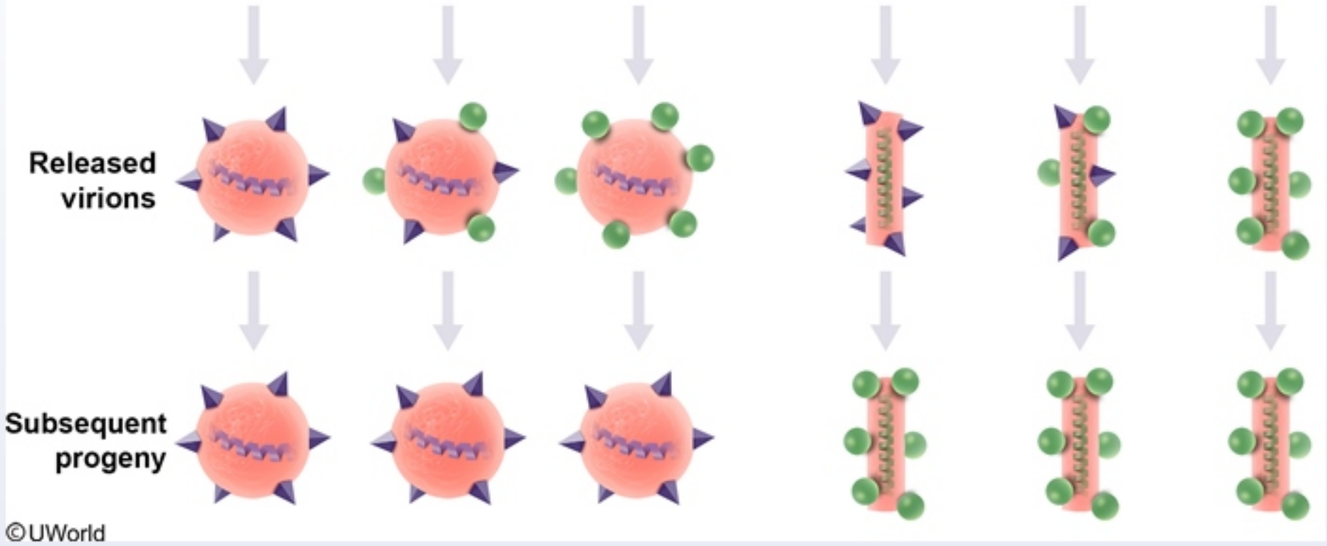

The acquisition of a new viral surface protein is often all that is necessary for a virus to infect a new type of host cell. In this scenario, avian and human influenza virus particles infect host pig cells; certain progeny avian virus particles obtain some of the surface components (eg, sialic acid receptors) of the human influenza virus, allowing the avian virus to infect human cells. This exchange is an example of **phenotypic mixing**, which generally occurs when a host cell is coinfected with 2 viral strains and progeny virions contain **unchanged parental genome** from one strain and **nucleocapsid (or envelope) proteins** from the **other** strain. However, because there is no change in the underlying viral genomes (no genetic exchange), subsequent progeny will **revert** to having only avian influenza type surface proteins and will again be noninfectious to human epithelium.

(Choice A) Interference occurs when one virus inhibits replication and/or release of a second virus that is infecting the same cell. Simple interference would not result in a new phenotype for progeny.

(Choice C) Reassortment refers to changes in genomic composition that occur when host cells are coinfected with 2 segmented viruses that exchange whole genome segments. When reassortment takes place in a cell coinfected by 2 viral strains, any genomic change in first generation progeny will also be present in subsequent progeny.

(Choice D) Recombination may be defined as the exchange of genes between 2 chromosomes (double-stranded DNA molecules) by crossing

The acquisition of a new viral surface protein is often all that is necessary for a virus to infect a new type of host cell. In this scenario, avian and human influenza virus particles infect host pig cells; certain progeny avian virus particles obtain some of the surface components (eg, sialic acid receptors) of the human influenza virus, allowing the avian virus to infect human cells. This exchange is an example of **phenotypic mixing**, which generally occurs when a host cell is coinfected with 2 viral strains and progeny virions contain **unchanged parental genome** from one strain and **nucleocapsid (or envelope) proteins** from the **other** strain. However, because there is no change in the underlying viral genomes (no genetic exchange), subsequent progeny will **revert** to having only avian influenza type surface proteins and will again be noninfectious to human epithelium.

(Choice A) Interference occurs when one virus inhibits replication and/or release of a second virus that is infecting the same cell. Simple interference would not result in a new phenotype for progeny.

(Choice C) Reassortment refers to changes in genomic composition that occur when host cells are coinfected with 2 segmented viruses that exchange whole genome segments. When reassortment takes place in a cell coinfected by 2 viral strains, any genomic change in first generation progeny will also be present in subsequent progeny.

(Choice D) Recombination may be defined as the exchange of genes between 2 chromosomes (double-stranded DNA molecules) by crossing over within homologous regions. As is the case with reassortment, any genomic change in the first generation progeny will also be present in subsequent progeny.

(Choice E) Transformation is generally defined as naked DNA uptake by a prokaryotic or eukaryotic cell. In virology, this term may also describe incorporation of viral DNA into a host cell chromosome. Transformation alters the genetic composition of the host cell but typically causes no genomic change in progeny virions.

Educational objective:
Phenotypic mixing refers to coinfection of a host cell by 2 viral strains, resulting in progeny virions that contain nucleocapsid proteins from one strain and the unchanged parental genome of the other strain. Because there is no change in the underlying viral genomes (no genetic exchange), the next generation of virions revert to their original, unmixed phenotypes.

Microbiology	Infectious Diseases	Viral genetics
Subject	System	Topic

receptors) of the human influenza virus, allowing the avian virus to infect human cells. This exchange is an example of **phenotypic mixing**, which generally occurs when a host cell is coinfected with 2 viral strains and progeny virions contain **unchanged parental genome** from one strain and **nucleocapsid (or envelope) proteins** from the **other** strain. However, because there is no change in the underlying viral genomes (no genetic exchange), subsequent progeny will **revert** to having only avian influenza type surface proteins and will again be noninfectious to human epithelium.

(Choice A) Interference occurs when one virus inhibits replication and/or release of a second virus that is infecting the same cell. Simple interference would not result in a new phenotype for progeny.

(Choice C) Reassortment refers to changes in genomic composition that occur when host cells are coinfected with 2 segmented viruses that exchange whole genome segments. When reassortment takes place in a cell coinfected by 2 viral strains, any genomic change in first generation progeny will also be present in subsequent progeny.

(Choice D) Recombination may be defined as the exchange of genes between 2 chromosomes (double-stranded DNA molecules) by crossing over within homologous regions. As is the case with reassortment, any genomic change in the first generation progeny will also be present in subsequent progeny.

(Choice E) Transformation is generally defined as naked DNA uptake by a prokaryotic or eukaryotic cell. In virology, this term may also describe incorporation of viral DNA into a host cell chromosome. Transformation alters the genetic composition of the host cell but typically causes no genomic change in progeny virions.

Educational objective:
Phenotypic mixing refers to coinfection of a host cell by 2 viral strains, resulting in progeny virions that contain nucleocapsid proteins from one strain and the unchanged parental genome of the other strain. Because there is no change in the underlying viral genomes (no genetic exchange), the next generation of virions revert to their original, unmixed phenotypes.

Microbiology	Infectious Diseases	Viral genetics
Subject	System	Topic

Copyright © UWorld. All rights reserved.